

# Diagnostic Accuracy of Benign Salivary Gland Aspiration Cytology - A Study with Histopathological Correlation

Lekshmi V.<sup>1</sup>, Mini B.<sup>2</sup>

<sup>1</sup>Department of Pathology, Government Medical College, Thrissur, Kerala, India. <sup>2</sup>Department of Pathology, Government Medical College, Alappuzha, Kerala, India.

## ABSTRACT

### BACKGROUND

Fine needle aspiration cytology (FNAC) is commonly used as a safe and minimally invasive diagnostic test in benign salivary gland lesions. Nevertheless, the capacity of aspiration cytology in diagnosing benign lesions in the salivary gland is still disputed because accurate tumour typing is dependent on the quality and yield of the aspirate, as well as the competence of the cytopathologist. We aim to assess the precision of fine needle aspirate in the pre-operative diagnosis of benign salivary gland lesions and compare it with the histopathological findings.

### METHODS

This is a longitudinal study conducted among 45 patients with preoperative cytological diagnosis of benign salivary gland lesions, who were followed-up till surgery with subsequent histopathological examination in Government Medical College, Thrissur, from 1<sup>st</sup> January 2013 to 30<sup>th</sup> June 2015.

### RESULTS

Among the benign neoplasms, 29 out of 30 cases of pleomorphic adenoma were confirmed on histopathology and one was basal cell adenoma. Out of nine cases of Warthin's tumour, only seven were confirmed by histopathology. Of the remaining two, one was found to be salivary duct carcinoma showing the typical comedo necrosis and the other was found to be low grade mucoepidermoid carcinoma. So, these two cases were found to be false negative. The statistical analysis showed an overall diagnostic accuracy of 95.5 % for benign salivary gland lesions.

### CONCLUSIONS

FNAC is a minimally invasive technique useful in salivary gland lesions. In non-neoplastic lesions surgery can be avoided and in neoplasms appropriate surgery can be planned. An accurate cytological diagnosis is often possible but may sometimes require the expertise of the cytopathology and use of ancillary techniques.

### KEYWORDS

Salivary Gland, Fine Needle Aspiration Cytology, Benign Tumours, Pleomorphic Adenoma, Warthin's Tumour, Mucoepidermoid Carcinoma, Salivary Duct Carcinoma

*Corresponding Author:*

*Dr. Mini B.,*

*Aparna, Kanjirathingal House,*

*VII/246, New Lane, NLRA-9,*

*Thottakkattukara P. O., Aluva,*

*Ernakulam - 683108, Kerala, India.*

*E-mail: aparnakammath@gmail.com*

*DOI: 10.18410/jebmh/2021/24*

*How to Cite This Article:*

*Lekshmi V, Mini B. Diagnostic accuracy of benign salivary gland aspiration cytology - a study with histopathological correlation. J Evid Based Med Healthc 2021;8(03):126-130.*

*DOI: 10.18410/jebmh/2021/24*

*Submission 05-10-2020,*

*Peer Review 20-10-2020,*

*Acceptance 03-12-2020,*

*Published 18-01-2021.*

*Copyright © 2021 Lekshmi V. et al. This is an open access article distributed under Creative Commons Attribution License [Attribution 4.0 International (CC BY 4.0)]*

## BACKGROUND

FNAC is commonly used as a safe and minimally invasive diagnostic test in benign salivary gland lesions.<sup>1</sup> The cytological features of benign lesions are comparatively well defined with a diagnostic accuracy of about 87 - 100 % in distinguishing benign from malignant salivary gland lesions.<sup>2,3</sup> Nevertheless, the capacity of aspiration cytology in diagnosing benign lesions in the salivary gland is still disputed because accurate tumour typing is dependent on the quality and yield of the aspirate, as well as the competence of the cytopathologist. The clinical value of pre-operative cytological analysis of salivary gland lesions is that it provides an accurate diagnosis with specific tumour type in many cases. If the diagnosis is that of a non-neoplastic lesion, then surgical intervention can be avoided. If it is a benign neoplasm, surgery can be avoided in the elderly patients and those who are at poor surgical risks.<sup>4</sup>

The limitations in cytological diagnosis of salivary gland lesions is mainly due to sampling errors. Cystic neoplasms like Warthin's tumour, mucoepidermoid carcinoma and occasionally pleomorphic adenoma with cystic degeneration may give a false negative diagnosis, as in these lesions, the sample content aspirated is mainly cyst fluid.<sup>5</sup> Mucoepidermoid and other carcinomas associated with focal inflammation and mucus retention can be mis-interpreted on cytology as sialadenitis or cystic lesions. Squamous metaplasia and atypia associated with sialadenitis, Warthin's tumour, or cellular pleomorphic adenoma can give a false positive diagnosis of malignancy.<sup>6</sup>

The present study aims at comparing cytological features of benign salivary gland lesions with that of histological findings to assess the diagnostic accuracy of aspiration cytology, with emphasis on discordant cases.

### Objectives

To evaluate the diagnostic accuracy of FNAC in the pre-operative diagnosis of salivary gland lesions by comparing it with the histopathologic sections.

## METHODS

This is a longitudinal study conducted on 45 patients with preoperative cytological diagnosis of benign salivary gland lesions for a period of 18 months.

### Inclusion Criteria

All patients with a pre-operative FNAC diagnosis of a benign lesion followed by surgical procedure and histologic examination in Government Medical College, Thrissur, from 1/1/2013 to 30/6/2015. Both male and female patients of all age group were included. Both direct and ultrasound guided FNAC were included in this study.

### Exclusion Criteria

Patients with recurrent lesions and patients who did not undergo surgical excision. The wet fixed cytological smears

were stained with Papanicolaou stain and May Grunwald Giemsa stain (MGG) was used for air dried smears. The specimens received after surgery were fixed in 10 % formalin for 24 hours after recording the gross morphological features. 5 mm thick bits were taken from representative areas and submitted for processing. 4–5 micron thick sections were cut with a microtome and stained with haematoxylin and eosin stain. Special stains were employed wherever indicated. The stained sections were studied by light microscopy. The histopathological findings were taken as the gold standard. FNAC diagnosis were compared with the final histological impression, concordance was assessed and diagnostic accuracy of aspiration cytology of benign salivary gland lesions were calculated.

## RESULTS

The present study showed a total number of 45 benign salivary gland lesions. The age of patients ranged from 12 years to 78 years, majority of cases (26.6 %) were seen in 4<sup>th</sup> decade. There were 22 male patients (48.89 %) and 23 female patients (51.11 %) in the present study. Male: Female ratio was 0.96:1.

### Frequency of Non-Neoplastic Lesions on FNAC

6 (13.3 %) out of 45 cases of benign salivary gland swellings were non-neoplastic lesions on FNAC. Of these, most common was chronic sialadenitis which was found in 3 cases (50 %), followed by chronic inflammatory lesion in 2 cases (33.3 %) and cystic lesion in one case (16.7 %).

### Frequency of Benign Neoplasms

Of the 45 cases, 39 cases (86.7 %) were found to be benign neoplasms. Out of which, pleomorphic adenoma was the commonest lesion, found in 30 cases (76.9 %) followed by Warthin's tumour in 9 cases (23.1 %).

### Site Wise Distribution of Benign Lesions

Majority of the benign neoplasms occurred in the parotid gland (86.7 %) followed by submandibular gland (13.3 %). Twenty-eight of thirty (93.3 %) cases of pleomorphic adenoma occurred in parotid gland and two (6.7 %) were seen in the submandibular gland. Nine out of nine (100 %) cases of Warthin's tumour occurred in parotid gland.

### Results of Fine-Needle Aspiration Cytology (FNAC) in 45 Salivary Gland Lesions with Histopathological Correlation

#### *Non-Neoplastic Lesions*

There were six cases (13.3 %) of non-neoplastic lesions all of which had histopathological correlation. All proved to be non-neoplastic on histopathological study. Hence, the accuracy was 100 %. All three cases with cytological findings of chronic sialadenitis were confirmed (100 %) on histopathological examination also. Of the two cases which

were reported as the chronic inflammatory lesion, one was diagnosed as lymphoepithelial cyst and the other as chronic sialadenitis on histopathology, which showed 50 % correlation. The case diagnosed as a cystic lesion turned out to be lymphoepithelial cyst (100 % accuracy). (Table 1)

**Benign Neoplasms**

Among the benign neoplasms, 29 out of 30 cases of pleomorphic adenoma diagnosed on cytological aspirates were confirmed on histopathology and one was proved to be basal cell adenoma, giving an accuracy rate of 96.7 %. Out of nine cases of Warthin’s tumour only seven were confirmed by histopathology. Here correlation was only 77.8 %. Of the remaining two, one was found to be salivary duct carcinoma showing the typical comedo necrosis and the other was found to be low grade mucoepidermoid carcinoma. So, these two cases (28.6 %) were proved to be false negative. (Table 2)

Non-Neoplastic Cytology	Histopathology (Non-Neoplastic)		
	Yes	No	Total
Yes	6	0	6
No	0	39	39
<b>Total</b>	<b>6</b>	<b>39</b>	<b>45</b>

**Table 1. Cytology Histopathology Correlation of Non-Neoplastic Salivary Gland Lesions**

Neoplastic–Benign Cytology	Histopathology (Neoplastic-Benign)		
	Yes	No	Total
Yes	37	2	39
No	0	6	6
<b>Total</b>	<b>37</b>	<b>8</b>	<b>45</b>

**Table 2. Cytology Histopathology Correlation of Benign Neoplastic Lesions**

Hence, the diagnostic accuracy of FNAC, for non-neoplastic lesions was found to be 100 % and for benign neoplastic lesions was 95.6 % (the diagnostic accuracy is expressed as a proportion of correctly classified subjects among all subjects. True positive + true negative / true negative + true negative + false positive + false negative)

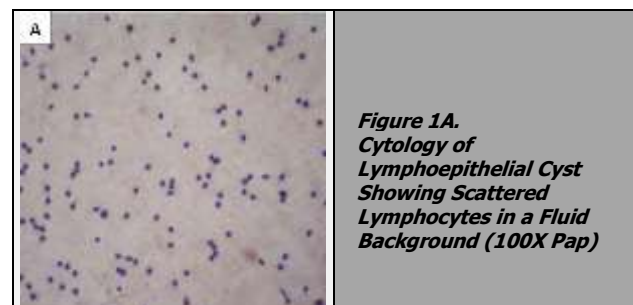
**DISCUSSION**

The maximum incidence of salivary gland lesions was observed in 4<sup>th</sup> decade of life for all lesions considered together.<sup>7,8</sup> Parotid gland was most frequently involved in present study, followed by submandibular salivary gland.<sup>7,8,9</sup> Among non-neoplastic lesions sialadenitis was the commonest non neoplastic lesion in present study.<sup>7,9,10</sup> Other non-neoplastic lesions included cystic lesions and all cases were correlated with cytological diagnosis. Most of patients diagnosed as sialadenitis, gave positive clinical history of the same. Smears were cellular with predominance of ductal epithelial cells, few acinar cells and a variable number of chronic inflammatory cells in chronic sialadenitis. Cystic lesion smears contained macrophages and lymphocytes against a mucinous background (Figure 1).

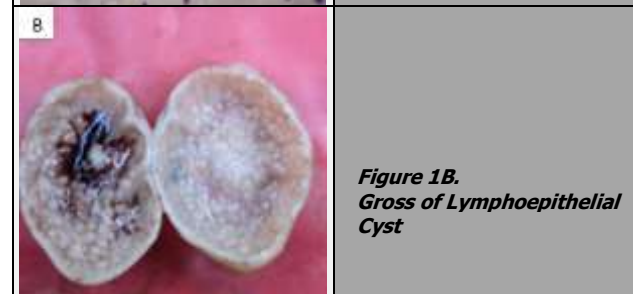
Present study showed pleomorphic adenoma as the most commonly encountered benign lesion and Warthin’s tumour as second most common lesion.<sup>7,8</sup> In this study pleomorphic adenoma shows higher incidence of occurrence in the parotid gland followed by submandibular gland.<sup>7,8</sup> Warthin’s

tumour cases are seen in parotid gland only in concordance with Shilpa et al<sup>7</sup> and Nanda et al.<sup>10</sup>

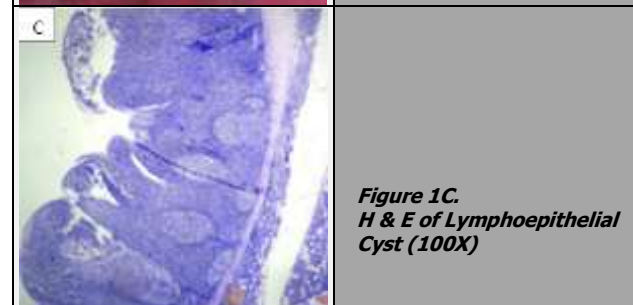
The smears diagnosed as pleomorphic adenoma were highly cellular in most of the cases with presence of both epithelial and chondromyxoid stromal component in various proportions. Epithelial component was either seen as clusters or were found dispersed. Myoepithelial cells in the background showed plasmacytoid appearance. Spindle shaped myoepithelial cells embedded in chondromyxoid stroma were also seen (Figure 2).



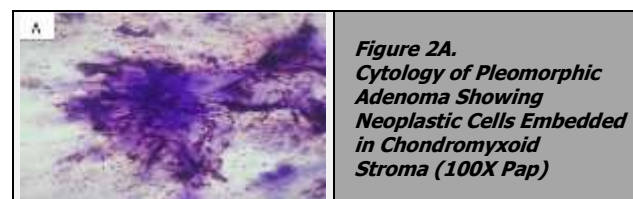
**Figure 1A.**  
*Cytology of Lymphoepithelial Cyst Showing Scattered Lymphocytes in a Fluid Background (100X Pap)*



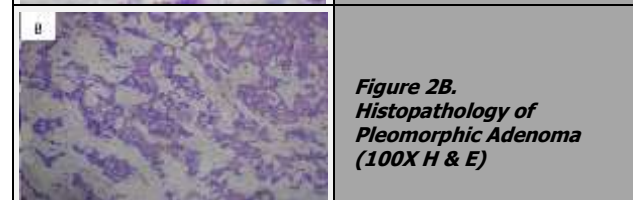
**Figure 1B.**  
*Gross of Lymphoepithelial Cyst*



**Figure 1C.**  
*H & E of Lymphoepithelial Cyst (100X)*



**Figure 2A.**  
*Cytology of Pleomorphic Adenoma Showing Neoplastic Cells Embedded in Chondromyxoid Stroma (100X Pap)*

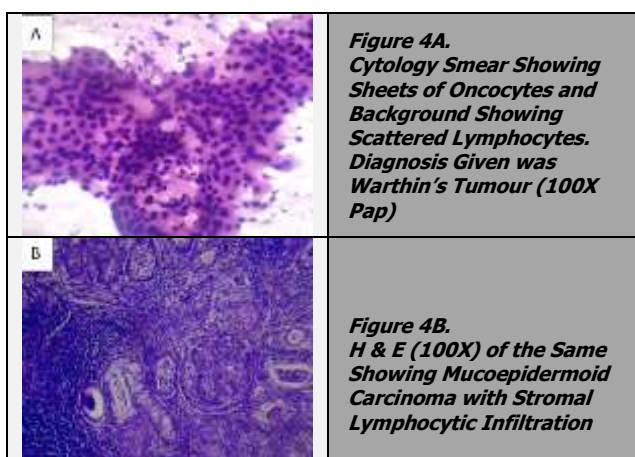
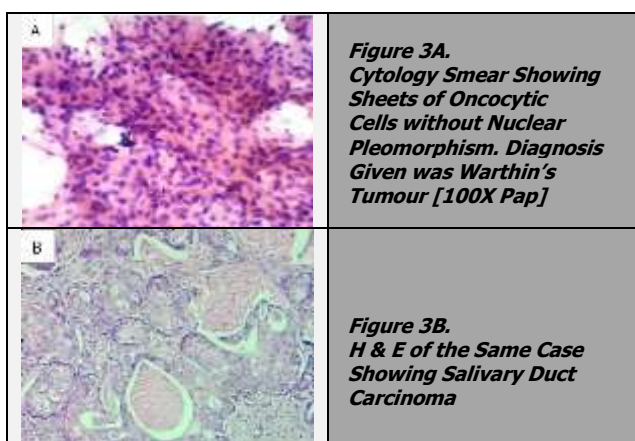


**Figure 2B.**  
*Histopathology of Pleomorphic Adenoma (100X H & E)*

In the present study, out of 30 cases, 29 cases of pleomorphic adenoma were confirmed by histopathology, and one was diagnosed as basal cell adenoma. FNAC is a fairly accurate pre-operative procedure for the diagnosis of pleomorphic adenomas. Some diagnostic problems do occur in differentiating pleomorphic adenoma (PA) from adenoid cystic carcinoma, basal cell adenoma, and mucoepidermoid

carcinoma.<sup>11</sup> Therefore, in order to avoid diagnostic pitfalls, a diagnostic approach based on the mandatory presence of all three of the following elements of PA should be looked for before signing out the report namely, 3-dimensional cohesive clusters of ductal cells, background of singly lying plasmacytoid myoepithelial cells and dense fibrillary brightly metachromatic stroma with partially obscured entrapped myoepithelial cells.<sup>11,12</sup>

Seven out of nine cases of Warthin's tumour was confirmed by histopathology. Of the other two cases of Warthin's tumour, one was diagnosed as salivary duct carcinoma (Figure 3) and the other was diagnosed as low grade mucoepidermoid carcinoma on histopathology. (Figure 4). The aspirates from Warthin's tumour were characteristic murky fluid in most of the cases. The smears showed clusters of oncocytic epithelial cells with plenty of lymphoid cells. The background showed macrophages and cellular debris.



In one case of Warthin's tumour, the aspirate was fluid material and the smears showed mainly fluid and macrophages even on repeated aspiration. On histology it turned out to be Warthin's tumour with predominant cystic change. According to Orell et al,<sup>13</sup> obtaining diagnostic material may be difficult in a predominantly cystic tumour. In order to make a definite diagnosis of Warthin's tumour, on cytology identification of both oncocytic cells and lymphocytes are required. (Lindberg et al).<sup>14</sup>

The case which was diagnosed as Warthin's tumour on FNAC showed sheets of oncocytic cells and plenty of lymphocytes in a dirty background containing histiocytes.

Nuclear pleomorphism was not prominent. Histopathology proved this case to be a low grade mucoepidermoid carcinoma. A diagnostic accuracy of only 50 % for mucoepidermoid carcinoma was reported by Pitts et al<sup>15</sup> in their study. According to Young et al<sup>16</sup> various neoplasms like mucoepidermoid carcinoma and acinic cell carcinoma are associated with lymphocytosis, leading to misinterpretation as Warthin tumour.

Similarly, the case of salivary duct carcinoma which was diagnosed as Warthin's tumour on cytology showed sheets of oncocytic cells without much nuclear pleomorphism and paucity of lymphocytes in the background. According to Klijanienko et al<sup>17</sup> Warthin's tumour, with paucity of lymphoid cells in the background and nuclear atypia is a differential diagnosis offered for salivary duct carcinoma on cytology. In the present study these were two false negative cases, and the diagnostic accuracy was found to be 95.5%.<sup>18,19,20</sup>

**CONCLUSIONS**

FNAC is a minimally invasive technique, useful in salivary gland lesions where an incisional biopsy is difficult and problematic. A diagnosis of a non-neoplastic lesion on cytology can avoid the need for surgery especially in elderly patients and those who are at risk for undergoing a major surgery. In neoplastic lesions, appropriate surgery can be planned. An accurate cytological diagnosis is often possible but may also sometimes require expertise of the cytopathologist, use of special laboratory techniques and is often better deferred to histological examination.

Data sharing statement provided by the authors is available with the full text of this article at jebmh.com.

Financial or other competing interests: None.

Disclosure forms provided by the authors are available with the full text of this article at jebmh.com.

**REFERENCES**

- [1] Layfield LJ, Glasgow BJ. Diagnosis of salivary gland tumors by fine-needle aspiration cytology: a review of clinical utility and pitfalls. *Diagnostic Cytopathology* 1991;7(3):267-272.
- [2] Paik I, Lee HK, Lee YD. The role of fine needle aspiration cytology of salivary gland tumors. *J Korean Surg Soc* 1999; 57:533-540.
- [3] Kline TS, Merriam JM, Shapshay SM. Aspiration biopsy cytology of the salivary gland. *Am J Clin Pathol* 1981;76(3):263-269.
- [4] Zhang S, Bao R, Bagby J, et al. Fine needle aspiration of salivary glands: 5-year experience from a single academic center. *Acta Cytol* 1999;53(4):375-382.
- [5] Kechagias N, Ntomouchtsis A, Valeri R, et al. Fine needle aspiration cytology of salivary gland tumours: a 10-year retrospective analysis. *Oral and Maxillofacial Surgery* 2011;16(1):35-40.

- [6] Kim MJ, Lee TS. A cytologic study of fine needle aspiration biopsy of salivary gland diseases. *Korean J Cytopathol* 1994;5(2):120-129.
- [7] Gandhi SH, Purohit TM, Purohit MB, et al. FNAC diagnosis of salivary gland lesions with histopathological correlation. *Nat J Integr Res Med* 2013;4(3):70-77.
- [8] Jain R, Gupta R, Kudesia M, et al. Fine needle aspiration cytology in diagnosis of salivary gland lesions: a study with histologic comparison. *Cyto Journal* 2013;10:5.
- [9] Tahoun N, Ezzat N. Diagnostic accuracy and pitfalls of preoperative fnac in salivary gland lesions. *J Egypt Natl Canc Inst* 2008;20(4):358-368.
- [10] Nanda KDS, Mehta A, Nanda J. Fine-needle aspiration cytology: a reliable tool in the diagnosis of salivary gland lesions. *Journal of Oral Pathology & Medicine* 2011;41(1):106-112.
- [11] Hussain N, Krishnani C, Gahine R, et al. Pleomorphic adenoma: a diagnostic pitfall in the diagnosis of salivary gland lesions on FNAC: case reports with review of the literature. *Cyto Journal* 2010; 7:17.
- [12] Lee SS, Cho KJ, Jang JJ, et al. Differential diagnosis of adenoid cystic carcinoma from pleomorphic adenoma of the salivary gland on fine needle aspiration cytology. *Acta Cytol* 1996;40(6):1246-1252.
- [13] Orell SR, Sterrett GF, Whitaker D, et al. Head and neck salivary glands. In: Orell SR, Sterrett GF, Whitaker D, eds. *Fine Needle Aspiration Cytology*. 4<sup>th</sup> edn. Edinburgh: Churchill Livingstone/ Elsevier 2005: p. 53-69.
- [14] Lindeerg L, Kerman M. Aspiration cytology of salivary gland tumors: diagnostic experience from six years of routine laboratory work. *The Laryngoscope* 1976;86(4):584-594.
- [15] Pitts DB, Hilsinger RL Jr, Karandy E, et al. Fine-needle aspiration in the diagnosis of salivary gland disorders in the community hospital setting. *Arch Otolaryngol Head Neck Surg* 1992;118(5):479-482.
- [16] Young J. Diagnostic problems in fine needle aspiration cytopathology of the salivary glands. *Journal of Clinical Pathology* 1994;47(3):193-198.
- [17] Klijanienko J, Vielh P. Cytologic characteristics and histomorphologic correlations of 21 salivary duct carcinomas. *Diagnostic Cytopathology* 1998;19(5):333-337.
- [18] Piccioni LO, Fabiano B, Gemma M, et al. Fine-needle aspiration cytology in the diagnosis of parotid lesions. *Acta Otorhinolaryngol Ital* 2011;31(1):1-4.
- [19] Postema R, van Velthuysen M, van den Brekel M, et al. Accuracy of fine-needle aspiration cytology of salivary gland lesions in the Netherlands Cancer Institute. *Head Neck* 2004;26(5):418-424.
- [20] Ashraf A, Shaikh AS, Kamal F, et al. Diagnostic reliability of FNAC for salivary gland swellings: a comparative study. *Diagn Cytopathol* 2010;38(7):499-504.