

DIAGNOSTIC ABILITY OF PERIMACULAR GANGLION CELL-INNER PLEXIFORM LAYER THICKNESS IN GLAUCOMA AND ITS CORRELATION WITH RETINAL NERVE FIBRE LAYER THICKNESS AND OPTIC NERVE HEAD PARAMETERS

Jyoti Shetty¹, Mohan Kannam², Rachel Joseph³, Fauqia⁴

¹Medical Director, Department of Ophthalmology, Bangalore West Lions Superspeciality Eye Hospital, Bangalore.

²DNB Student, Department of Ophthalmology, Bangalore West Lions Superspeciality Eye Hospital, Bangalore.

³Consultant, Department of Ophthalmology, Bangalore West Lions Superspeciality Eye Hospital, Bangalore.

⁴Consultant, Department of Ophthalmology, Bangalore West Lions Superspeciality Eye Hospital, Bangalore.

ABSTRACT

BACKGROUND

The retinal ganglion cell layer is the first cell layer within the retina to be affected by early glaucoma. Approximately, 50% of Retinal Ganglion Cells (RGC) are located within the macula, it is well known that patients with glaucoma can suffer a 20% to 50% loss of retinal ganglion cells before a defect becomes evident in standard perimetry. Hence, macular imaging is suggested to be a valuable alternative scanning location method for glaucoma diagnosis and assessing neural damage in glaucoma.

The aim of the study is to assess the diagnostic ability of perimacular Ganglion Cell Inner Plexiform Layer (GCIPL) thickness in patients with glaucoma using HD-cirrus OCT and its correlation with Retinal Nerve Fibre Layer (RNFL) thickness and other ONH parameters in different optic disc sizes in a tertiary referral eye care centre in southern India.

MATERIALS AND METHODS

Optic nerve head (200 x 200) and macular imaging (512 x 128) with cirrus HD-OCT was performed on 100 eyes of 66 glaucoma patients and 85 eyes of 50 control patients. Macular GCIPL thickness was assessed and correlated with peripapillary RNFL thickness and ONH parameters like disc area, rim area and cup volume.

RESULTS

Mean GCIPL thickness was thinner in eyes with glaucoma in comparison to controls (70.64 ± 12.24 micrometers versus 79.58 ± 0.51 micrometers). Mean RNFL thickness in eyes with glaucoma was thinner compared with controls (76.44 ± 16.36 micrometers vs. 90.62 ± 27.57 micrometers). Mean GCIPL segment thickness in all glaucomatous discs showed significant correlation ($P < 0.05$) with corresponding mean RNFL quadrant thickness. Significant correlation was found in large discs ($P < 0.05$), but the level of significance decreased in medium discs (P value- $0.05 < P < 0.10$). Mean RNFL thickness showed statistically significant correlation to rim area ($P < 0.001$) in large and medium discs, whereas mean GCIPL thickness showed significant correlation with rim area in large discs only. Other factors like disc area and cup volume did not show any correlation with mean RNFL and GCIPL thickness.

CONCLUSION

RNFL thickness analysis still remains the main quantitative analysis for glaucoma. GCIPL thickness analysis can also be used as a surrogate parameter to assess RNFL thickness loss in cases where RNFL analysis can be fallacious as in large peripapillary atrophy, abnormal disc vasculature and tilted disc provided macular pathology has been ruled out. RNFL thickness correlation with GCIPL thickness was not influenced by disc size. Rim area had significant positive correlation to mean RNFL thickness. Other optic nerve head parameters like disc area and cup volume did not show any correlation.

KEYWORDS

GCIPL Thickness in Glaucoma, Comparison of GCIPL and RNFL Thickness, ONH Parameters.

HOW TO CITE THIS ARTICLE: Shetty J, Kannam M, Joseph R, et al. Diagnostic ability of perimacular ganglion cell-inner plexiform layer thickness in glaucoma and its correlation with retinal nerve fibre layer thickness and optic nerve head parameters. J. Evid. Based Med. Healthc. 2017; 4(49), 2997-3001. DOI: 10.18410/jebmh/2017/593

Financial or Other, Competing Interest: None.

Submission 27-05-2017, Peer Review 02-06-2017,

Acceptance 15-06-2017, Published 17-06-2017.

Corresponding Author:

Dr. Rachel Joseph,

Consultant, Department of Ophthalmology,
Bangalore West Lions Superspeciality Eye Hospital, Bangalore.

E-mail: mail4dr Rachel@gmail.com

DOI: 10.18410/jebmh/2017/593



BACKGROUND

The retinal ganglion cell layer is the first cell layer within the retina to be affected by early glaucoma.^{1,2,3} Approximately, 50% of RGCs are located within the macula, it is well known that patients with glaucoma can suffer a 20% to 50% loss of retinal ganglion cells before a defect becomes evident in standard perimetry.^{4,5} Hence, macular imaging is suggested to be a valuable alternative scanning location method for glaucoma diagnosis and assessing neural damage in glaucoma.

Imaging of RGCs is the most promising approach for the early diagnosis of glaucoma, because the loss of RGCs is directly associated with the characteristic glaucomatous loss of visual field. However, imaging of retinal ganglion cells still remains a problem, because of the transparency of these cells.⁶ Histologically, GCIPL is the next best possible layer that can be used to quantify retinal ganglion cells, which became a possibility with the advent of newer generations of HD-OCT.

The present study has been taken up keeping in mind the paucity of studies of diagnostic value of GCIPL thickness and its correlation with RNFL thickness in glaucoma in south Indian population.

MATERIALS AND METHODS

Our study used an observational cross-sectional comparative research design. We recruited patients attending glaucoma clinic at Bangalore West Lions Superspeciality Eye Hospital, a tertiary eye care center in Bangalore for our study. Diagnosed cases of glaucoma with ONH changes on slit lamp biomicroscopy and characteristic visual field changes with refractive error between +4.0D to -4.0D in the age group of 20-90 yrs. were chosen for the study. Eyes with previous or current vitreoretinal diseases, a history of previous retinal surgery or retinal laser treatment, evidence of diabetic retinopathy or macular pathology (e.g., macular oedema, macular scar, etc.) and subjects with a history of dementia, multiple sclerosis or life-threatening or debilitating disease were excluded from the study. One or both eyes from same patient were included in the study if the inclusion criteria were met. Control eyes were randomly chosen among the patients attending general ophthalmology outpatient department in the same institute. Only eyes with no history or evidence of intraocular surgery and no retinal pathological features, a BCVA 6/6 or 6/9 and refractive error between +4.00 and -4.00D, intraocular pressure of ≤ 21 mmHg, open angle on gonioscopy, normal optic disc and reliable normal visual field test and normal OCT were selected as controls. Data collection commenced after ethical clearance was obtained from the biomedical research and ethics committee with all participants giving written informed consent. The tenets of the Declaration of Helsinki were adhered to.

Personal details, which includes age and gender, history of previous medical and ocular conditions were noted. Detailed clinical examination was done, which included Snellen's visual acuity aided and unaided. Slit lamp examination of anterior segment, intraocular pressure, gonioscopy and visual field test were done. Dilated fundus examination with indirect ophthalmoscopy using +20D and optic nerve head evaluation with 90D lens was done. Optic nerve head (200x200) and macular imaging (512x128) scans were captured using cirrus HD optical coherence tomography. Macular GCIPL thickness diagnostic value was assessed and correlated with peripapillary RNFL thickness and other ONH parameters like disc area, rim area and cup volume.

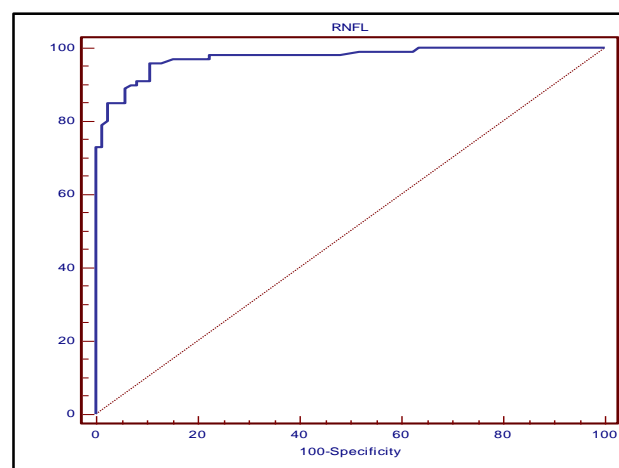
In total, 100 eyes of 66 subjects and 85 eyes of 50 controls were included in the study.

RESULTS

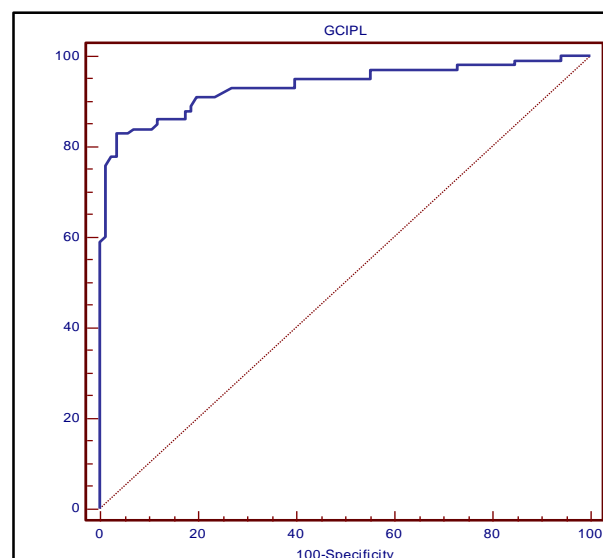
The mean age of the cases was 59.59 ± 14.10 years and controls was 51 ± 10.6 years. Males were predominant in both cases and controls. The mean RNFL thickness in cases was 76.44 ± 16.36 micrometers and in controls was 90.62 ± 27.57 micrometers. Mean RNFL thickness in each quadrant was thinner in cases compared to controls ($p < 0.05$). The mean GCIPL thickness in cases was 70.64 ± 12.24 micrometers and in controls was 79.58 ± 0.51 micrometers. Mean GCIPL thickness in each segment was thinner in cases in comparison to controls ($p < 0.05$). Mean GCIPL thickness measurement and mean RNFL thickness measurement in all discs, large discs and medium discs had excellent diagnostic capability.

Diagnostic value of mean RNFL thickness and mean GCIPL thickness- statistical data for interpretation of AUC in ROC curves-

1. 0.90-1 = Excellent.
2. 0.80-0.90 = Good.
3. 0.70-0.80 = Fair.
4. 0.60-0.70 = Poor.
5. 0.50-0.60 = Fail.

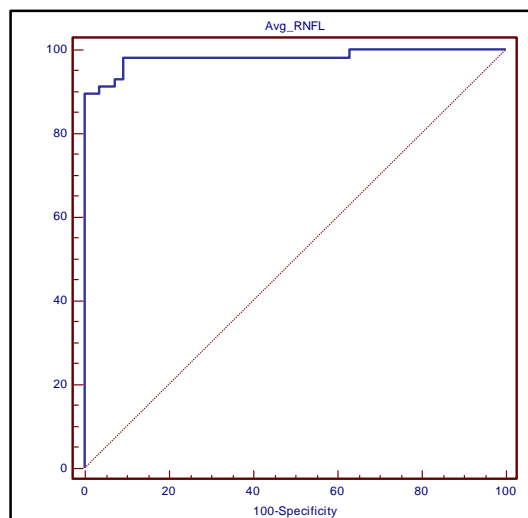


Graph 1. Area under Curve of ROC Curve for Mean RNFL Thickness (0.974) in all 100 Glaucomatous Eyes

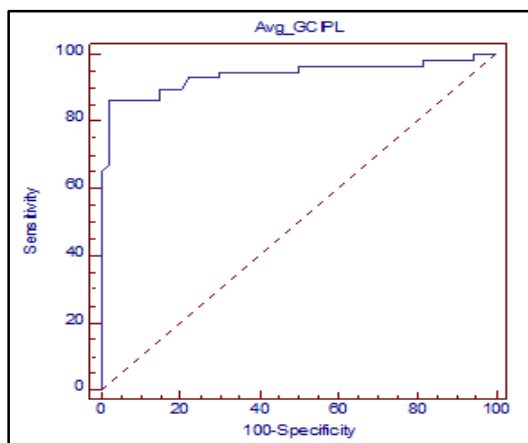


Graph 2. Area under Curve of ROC Curve for Mean GCIPL Thickness (0.934) in all 100 Glaucomatous Eyes

The area under the receiver operating characteristic curves of mean RNFL and mean GCIPL thickness showed excellent diagnostic ability in 100 glaucomatous eyes.

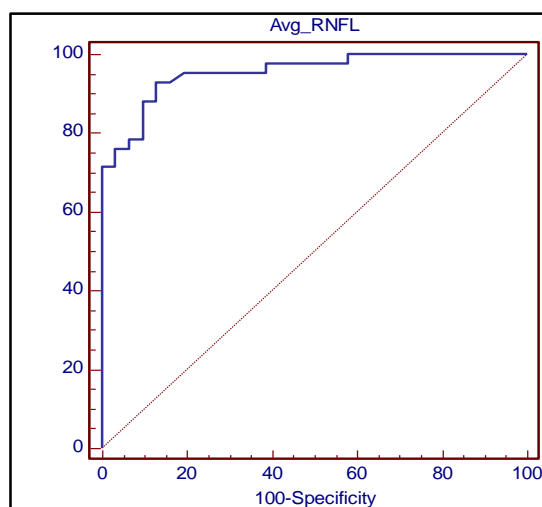


Graph 3. Area under Curve of ROC Curve for Mean RNFL Thickness (0.982) in Large Disc Glaucomatous Eyes

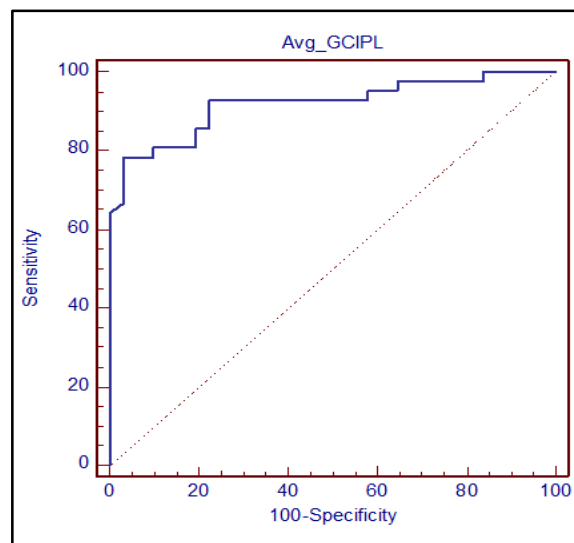


Graph 4. Area under Curve of ROC Curve for Mean GCIPL Thickness (0.940) in Large Disc Glaucomatous Eyes

AUC for mean RNFL thickness and mean GCIPL thickness in large disc showed excellent diagnostic ability.



Graph 5. Area under Curve of ROC Curve for Mean RNFL Thickness (0.954) in Medium Disc Glaucomatous Eyes



Graph 6. Area under Curve of ROC Curve for Mean GCIPL Thickness (0.919) in Medium Disc Glaucomatous Eyes

AUC for mean RNFL thickness and mean GCIPL thickness in medium disc showed excellent diagnostic ability.

RNFL quadrant thickness showed significant correlation ($P < 0.05$) with corresponding GCIPL segment thickness in all glaucomatous discs. Significant correlation was found in large discs ($P < 0.05$), but level of significance decreased in medium discs ($P \text{ value: } 0.05 < P < 0.10$). Mean RNFL thickness showed significant correlation with rim area in large and medium discs ($P < 0.05$) other factors like disc area and cup volume did not show any correlation. Mean GCIPL thickness showed significant correlation with rim area in large discs only. Other factors like disc area and cup volume did not show any correlation.

DISCUSSION

Optic Disc Size Distribution- The disc damage likelihood scale was used to categorise optic discs into small, medium and large. Our study includes predominantly medium and large discs with no small discs in either cases or controls. Our results are similar with Hoffmann et al⁷ study that showed a prevalence of medium to large sized discs in Asian population.

In All 100 Discs- Area under receiver operating characteristic curve was calculated for mean RNFL thickness (AUROC: 0.974) and mean GCIPL thickness (0.934) in all 100 glaucomatous discs, and it showed excellent ability to diagnose glaucoma.

In Large Discs- In large disc, Area Under Curve (AUC) for mean RNFL thickness was 0.982 and mean GCIPL thickness in large disc glaucomatous was 0.940.

In Medium Discs- AUC of ROC for mean RNFL thickness in medium disc glaucomatous eyes was 0.954 and for mean GCIPL thickness was 0.919.

In our study, mean RNFL and GCIPL thickness showed excellent ability to diagnose glaucoma in large and medium disc size groups. The results of our study are similar to

Myung Hun Yoon et al⁸ study in which they concluded that mean RNFL thickness and mean GCIPL thickness showed a good diagnostic ability for glaucoma in large and medium discs.

Correlation of Mean RNFL Thickness and Mean GCIPL Thickness in all Cases (100 Eyes)-

In 100 subject eyes when RNFL quadrant thickness was correlated with GCIPL segments thickness by Pearson Correlation.

- Inferior RNFL quadrant thickness showed significant correlation with inferotemporal, inferior and inferonasal GCIPL segment thickness.
- Superior and temporal RNFL quadrants thickness showed significant correlation with superotemporal, superior, superonasal and inferonasal GCIPL segments thickness.
- Nasal RNFL quadrants thickness showed significant correlation only with superior segment thickness as expected because of anatomical variability in distribution of RNFL around the macula.

Anatomically, ganglion cell axons from macular region are more likely to radiate towards temporal, superior and inferior poles of the optic disc than the nasal pole. Therefore temporal, superior and inferior peripapillary RNFL thicknesses would correlate significantly with macular GC-IPL, but none or weak correlation would be observed between nasal RNFL and macular GC-IPL thicknesses.⁹ David Huang et al¹⁰ in his paper explained that RNFL distribution is known to be nonuniform as nerve fibers radiate out from the disc, they shift away from the nasal quadrant toward the temporal quadrant because the macula is temporal to the disc. This asymmetric divergence should make temporal RNFL thickness decrease more slowly than nasal RNFL thickness decrease more rapidly.

Correlation of Mean RNFL Thickness and Mean GCIPL Thickness in Large Discs-

- Inferior RNFL quadrant thickness showed significant correlation with inferonasal, inferior GCIPL segments thickness and suggestive correlation with thickness of inferotemporal segment.
- Superior RNFL quadrant thickness correlated significantly with thickness of superotemporal, superior, superonasal and inferior GCIPL segments.
- Temporal RNFL quadrant thickness showed significant correlation with thickness of superotemporal and superior GCIPL segments.
- Nasal RNFL quadrant thickness showed suggestive correlation with inferotemporal quadrant thickness.

Correlation of Mean RNFL Thickness and Mean GCIPL Thickness in Medium Size Disc-

Only superior quadrant RNFL thickness showed significant correlation with superior, superotemporal and inferonasal GCIPL segments thickness. Inferior, nasal and temporal

RNFL quadrants thickness did not show any correlation with GCIPL segments thickness.

Correlation between mean RNFL thickness and mean GCIPL thickness was significant in all 100 glaucomatous eyes, but the strength of correlation decreased from large to medium disc. This can be explained by 3.4 mm peripapillary scan diameter used in the OCT.

According to Carpineto¹¹ and Savini et al,¹² thickness of RNFL is inversely proportional to radius as shown below.

In a circular scan of the RNFL, $T = A/2\pi \cdot r$

T = thickness of RNFL.

$R = r$ is the radius of the scan circle.

Based on above formula, the average RNFL thickness should be inversely proportional to the radius of the scan circle in an OCT circumpapillary scan. The number of nerve fibers transected by the scan circle is diminished as the scan circles goes away from the optic disc margin. In large disc, scan margin falls close to the optic disc margin, the number of fibres measured is more. This gives a false high thickness of circumpapillary RNFL. In moderate-sized disc as the scan margin falls away from the disc margin and due to wider separation of nerve fibres, the number of fibres measured is less, thus giving a false low thickness value.^{11,12}

Correlation of RNFL Thickness and GCIPL Thickness with ONH Parameters-

Mean RNFL thickness did not show any significant correlation with the optic disc area and cup volume in large and medium-sized discs. However, mean RNFL thickness showed statistically significant correlation to rim area ($P < 0.001$) in large and medium discs. This can be explained by the thinning of neuroretinal rim with loss of RNFL fibres passing through optic nerve. This was similar to the finding in the study conducted by Tham YC, Cheung CY et al.¹³

Mean GCIPL thickness did not show any significant correlation with the optic disc area and cup volume in large and medium-sized discs. However, mean GCIPL thickness showed significant correlation to rim area ($P < 0.001$) in large discs.

Similarly Myung Hun Yoon,⁸ et al and Huang, et al¹⁰ in their studies did not show any significant correlation between mean RNFL thickness, mean GCIPL thickness to optic nerve head parameters. Yih-Chung Tham et al¹³ study showed only fair correlation between optic nerve head parameters to mean GCIPL and RNFL thickness.

CONCLUSION

RNFL thickness analysis still remains the main quantitative analysis for glaucoma. Our study shows that RNFL thickness correlates well with GCIPL thickness in large and medium discs. Both have excellent capability for diagnosing glaucoma. GCIPL thickness analysis can also be used as a surrogate parameter to assess RNFL loss in cases where RNFL analysis can be fallacious as in large peripapillary atrophy, abnormal disc vasculature and tilted disc provided macula pathology has been ruled out. RNFL

thickness correlation with GCIPL thickness was not influenced by disc size. Rim area had significant positive correlation to mean RNFL thickness. Other optic nerve head parameters like disc area and cup volume did not show any correlation.

REFERENCES

- [1] Howard D, Harry AQ, Glovinsky Y. Study of central retinal ganglion cell loss in experimental glaucoma in monkey eyes. *Journal of Glaucoma* 1996;5(1):46-53.
- [2] Zeimer, Ran et al. Quantitative detection of glaucomatous damage at the posterior pole by retinal thickness mapping. A pilot study. *Ophthalmology* 1998;105(2):224-231.
- [3] Frishman LJ, Shen FF, Du L, et al. The scotopic electroretinogram of macaque after retinal ganglion cell loss from experimental glaucoma. *Invest Ophthalmol Vis Sci* 1996;37(1):125-141.
- [4] Kerrigan-Baumrind LA, Quigley HA, Pease ME, et al. Number of ganglion cells in glaucoma eyes compared with threshold visual field tests in the same persons. *Invest Ophthalmol Vis Sci* 2000;41(3):741-748.
- [5] Quigley HA, Addicks EM, Green WR, et al. Optic nerve damage in human glaucoma. The site of injury and susceptibility to damage. *Archives of Ophthalmology* 1981;99(4):635-649.
- [6] Bussell II, Wollstein G, Schuman JS. OCT for glaucoma diagnosis, screening and detection of glaucoma progression. *British Journal of Ophthalmology* 2014;98(2):15-19.
- [7] Hoffmann EM, Zangwill LM, Crowston JG, et al. Optic disk size and glaucoma. *Survey of Ophthalmology* 2007;52(1):32-49.
- [8] Yoon MH, Park SJ, Kim CY et al. Glaucoma diagnostic value of the total macular thickness and ganglion cell-inner plexiform layer thickness according to optic disc area. *Br J Ophthalmol* 2014;98(3):315-321.
- [9] Kim NR, Lee ES, Seong GJ, et al. Comparing the ganglion cell complex and retinal nerve fiber layer measurements by Fourier domain OCT to detect glaucoma in high myopia. *Br J Ophthalmol* 2011;95(8):1115-1121.
- [10] Huang D, Chopra V, Lu A, et al. Does optic nerve head size variation affect circumpapillary retinal nerve fiber layer thickness measurement by optical coherence tomography? *Invest Ophthalmol & Vis Sci* 2012;53(8):4990-4997.
- [11] Carpineto P, Ciancaglini M, Aharrh-Gnama A, et al. Custom measurement of retinal nerve fiber layer thickness using STRATUS OCT in normal eyes. *Eur J Ophthalmol* 2005;15(3):360-366.
- [12] Savini G, Barboni P, Carbonelli M, et al. The effect of scan diameter on retinal nerve fiber layer thickness measurement using Stratus optic coherence tomography. *Arch Ophthalmol* 2007;125(7):901-905.
- [13] Tham Y, Cheung C, Koh VT, et al. Relationship between ganglion cell-inner plexiform layer and optic disc/retinal nerve fibre layer parameters in non-glaucomatous eyes. *Br J Ophthalmol* 2013;97(12):1592-1597.