

DIAGNOSIS AND MANAGEMENT OF CSF RHINORRHOEA – OUR EXPERIENCE

N. Venkatram Reddy¹, K. Anjani kumar², J. Bhupender Singh Rathod³, B. Vyshnavi⁴, K. Sushma Reddy⁵, P. Amreetha Kaur⁶

¹Associate Professor, Department of ENT, Osmania Medical College.

²Assistant Professor, Department of ENT, Osmania Medical College.

³Assistant Professor, Department of ENT, Osmania Medical College.

⁴Senior Resident, Department of ENT, Osmania Medical College.

⁵Junior Resident, Department of ENT, Osmania Medical College.

⁶Junior Resident, Department of ENT, Osmania Medical College.

ABSTRACT

INTRODUCTION

CSF rhinorrhoea is the leakage of clear watery fluid from the subarachnoid space into nasal and/or sinus cavities. CSF leak is a known potential complication with significant morbidity and mortality. It may present a significant challenge in the diagnosis of localization of the site of the leak and its surgical management. CSF rhinorrhoea can be diagnosed with more accurate localization of the site of CSF leak with modern radiological methods. Repair involves surgical intervention, which has changed from open craniotomy to minimally invasive trans nasal endoscopic (TNE) surgical technique. Endoscopic repair (ER) through the nasal approach has gained popularity for the past two decades and practiced by ENT surgeons with or without the help of neurosurgeons.

AIM OF THE STUDY

1. To evaluate the causes and identification of CSF leak.
2. To assess the success rate in the CSF rhinorrhoea adopting a particular surgical technique and graft material by trans nasal endoscopic approach to skull base.

MATERIAL AND METHODS

This is a retrospective study of 76 established cases of CSF Rhinorrhoea (R) admitted and treated at Government ENT Hospital/Osmania Medical College, Hyderabad, Telangana State between 2005-2013.

INCLUSION CRITERIA

All the cases of CSF leak continuous or intermittent lasting for more than two weeks duration, irrespective of the aetiology. The study cases include spontaneous, traumatic, meningoencephalocoeles, post functional endoscopic sinus surgery (FESS).

EXCLUSION CRITERIA

CSF leaks of less than two weeks duration (medical treatment).
CSF leaks with space occupying lesions in the brain.
CSF leaks with polytrauma (PT) and patient in emergency status.

RESULTS

CSF rhinorrhoea cases are evaluated with regard to their site of leak and trans nasal endoscopic (TNE) surgical approach and the results are drawn and success rate is compared with other studies in the literature.

CONCLUSION

The authors concluded that trans nasal endoscopic management of CSF Rhinorrhoea had high success rate, low morbidity and stable long term results.

KEYWORDS

CSF-Cerebrospinal Fluid, ER-Endoscopic Repair, R-Rhinorrhoea, PT-Polytrauma, FESS-Functional Endoscopic Sinus Surgery, TNE-Trans Nasal Endoscopic, CT-Computerised tomography, HRCT-High Resolution CT, MRI-Magnetic Resonance Imaging

HOW TO CITE THIS ARTICLE: Reddy NV, Kumari KA, Rathod JBS. et al. Diagnosis and management of CSF rhinorrhoea – our experience. J. Evid. Based Med. Healthc. 2016; 3(12), 361-365. DOI: 10.18410/jebmh/2016/86

Submission 18-01-2016, Peer Review 30-01-2016,

Acceptance 08-02-2016, Published 11-02-2016.

Corresponding Author:

Dr. Venkatram Reddy,

H. No. 17-1-391/T/Plot 12,

Sarawathinagar, Saidabad, Hyderabad-500099.

E-mail: venkatramreddyn@gmail.com

DOI: 10.18410/jebmh/2016/86

INTRODUCTION: Management of CSF rhinorrhoea demands clear understanding of the etiopathology of dural fistula. Most leaks occur as a defect at the anterior skull base. The fundamental cause of CSF leaks is due to many factors like lack of proper closure (congenital), inadequate support of weak healing tissues, poor healing due to infection or trauma, metabolic disorders and other chronic diseases.

CSF Rhinorrhoea was first described by Galen 200 BC. The traumatic CSF leaks are known since 17th century. First published case of CSF rhinorrhoea was non-traumatic high pressure leak reported by Muller¹ in 1836, followed by King² in 1834 and Thompson³ in 1899. First series of cases treated by transcranial extradural repair using fascia lata was published by Cairns⁴ in 1937. The intradural repair was first used by Taylor and Eden⁵ in 1941. Etiological classification was first developed by Omayya et.al.⁶ Lanza et.al.⁷ has reported a study of 36 patients with success rate of 94.4% with trans nasal endoscopic approach. Dandy 1920 first described successful intracranial CSF leak repair by external approach. Dolhmann G⁸ 1948 reported extra cranial repair of spontaneous CSF leak by trans orbital ethmoidectomy approach. Hirsch O⁹ 1952 has done endo nasal repair of sphenoid sinus rhinorrhoea using septal mucosal flap. Wigand¹⁰ 1981 first described endoscopic repair for iatrogenic CSF leaks during Functional endoscopic sinus surgery (FESS). Papy et al 1989 described endoscopic management of CSF leak using thigh fat and fascia. Later these methods were popularized by Stankiewicz, Kennedy, Stamberger, Draf¹¹ etc. and the method has become the most accepted and widely used technique for CSF fistulae.

AIMS:

1. To evaluate the causes and identification of CSF leak
2. To assess the success rate in the CSF rhinorrhoea adopting a particular surgical technique and graft material by trans nasal endoscopic approach to skull base.

MATERIAL AND METHODS: This is a retrospective study of 76 established cases of CSF Rhinorrhoea admitted and treated at Government ENT Hospital/Osmania Medical College, Hyderabad, Telangana State between 2005-2013. All the 76 cases were worked up clinically with relevant history, DNE and investigations of High Resolution CT Scan with contrast to detect the site of leak. MRI with contrast was done in some cases where The HRCT failed to point out the site of defect. All the cases were subjected to trans nasal endoscopic repair with fascia lata and the thigh fat and post operatively managed with head end elevation of 45 degrees with acetazolamide, antibiotics. No lumbar drain was used as many studies in the literature suggest no advantage, on the contrary it has its own complications.

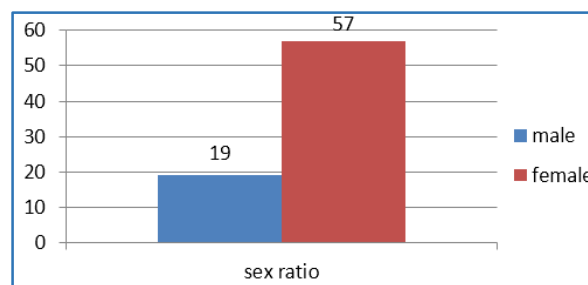
Inclusion Criteria: All the cases of CSF leak continuous or intermittent lasting for more than two weeks duration, irrespective of the aetiology.

The study cases include spontaneous, traumatic, meningoencephaloceles, post functional endoscopic sinus surgery.

Exclusion Criteria: CSF leaks of less than two weeks duration (medical treatment)

CSF leaks with space occupying lesions in the brain.

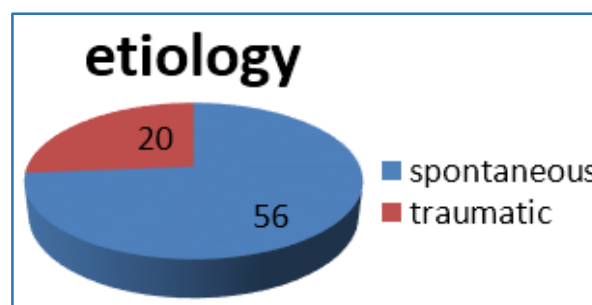
RESULTS: Seventy six (76) cases of CSF rhinorrhoea have been operated between January 2005–December 2013 at our institution, aged between 8 years–60 years, 57-female, 19-male, F : M=3:1.



Graph 1

N=76.

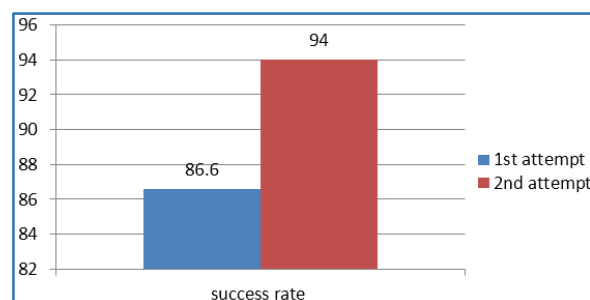
Of the total 76 cases of CSF Rhinorrhoea who have undergone surgery, 56 are spontaneous leaks and 20 are post trauma (16–Road Traffic Accidents and 4 cases–post endoscopic sinus surgery).



Graph 2

N=76.

Endoscopic endonasal surgical repair was successful in 66 cases at the first attempt giving a success percentage of 86.8%. 6 cases had recurrence of CSF leak which underwent revision surgery and are successful at the second attempt, giving a success percentage of 94% that includes primary and second attempt.



Graph 3

N=76.

Four (4) cases were referred to neuro surgeon as the defect was more than 18 millimetres, leak from multiple sites, leak from the roof of sphenoid. These four cases underwent craniotomy and are under the follow-up of neuro surgeon (5.2% cases). In our series the success rate of

endoscopic repair of CSF rhinorrhoea at first intervention is 86% which is similar to the results reported by Schick et.al¹² in 2001 and Burns¹³ in 1996.

DISCUSSION: CSF rhinorrhoea is classified Ommaya et. al into traumatic and non-traumatic. In the non-traumatic category, there may be high pressure leaks or normal pressure leaks. The authors conducted a retrospective study of 76 documented cases of CSF rhinorrhoea presented to the Department of Ear, Nose, Throat. The pre-operative evaluation of all the cases includes a thorough clinical examination including diagnostic nasal endoscopy, CSF analysis, High Resolution Computerized Tomography, Magnetic Resonance Imaging in cases where there is meningoencephalocele or a mass lesion in the roof of nasal cavity. Beta2 Transferrin test by electrophoresis was not conducted in any case. The Glucose level of >30 mg/dL was taken as confirmatory in the CSF analysis. High Resolution Computerized Tomography was confirmatory to detect the site of leak in the majority of the cases.¹⁴ The Magnetic Resonance Imaging (MRI) with contrast was performed in cases where the CT scan failed to point out the site of the

defect.^{15,16} Intra operatively, if the site of the defect is not identified, the authors adapted for intra operative Valsalva. Intra operative Fluorescein test was conducted in one case where the defect was identified at the cribriform plate.¹⁷

High resolution Computerized Tomography can detect the bony defect at skull base but cannot establish CSF leak. CT Cisternography is useful in identifying the leak.^{18,19}

MRI and MR Cisternography are non-invasive alternatives to intrathecal contrast. High resolution computerized tomography (HRCT) but cannot detect the bone defects.

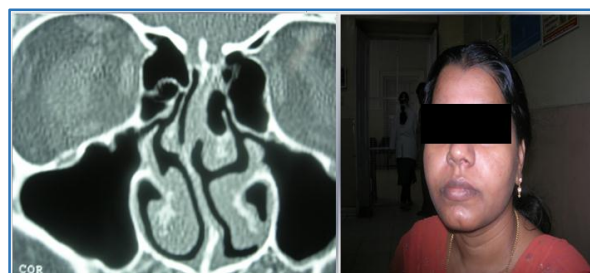


Fig. 1: Leak from cribriformplate

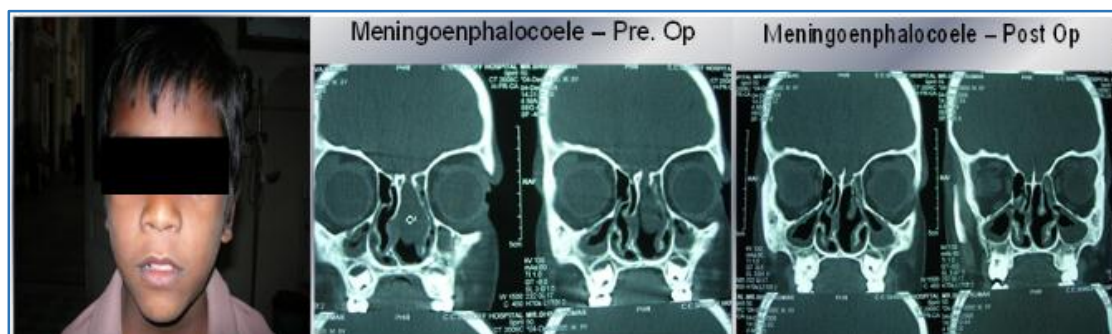

Fig. 2

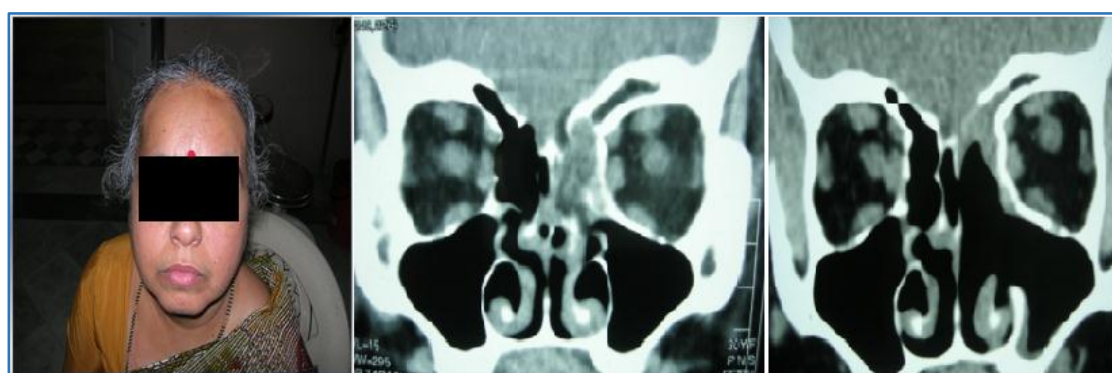

Fig. 3: Pre-operative

Post-operative

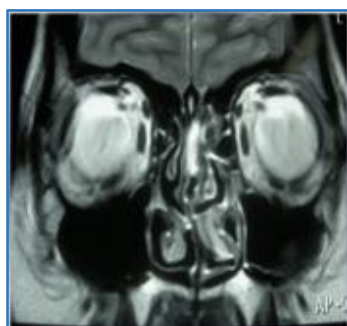

Fig. 4: MR Cisternography leak from cribriform plate

Surgical Technique: The basic principle of endoscopic surgical repair is positive identification of the leak, meticulous preparation of the graft bed and accurate placement of the graft material. There are many surgical techniques described in the literature like on lay placement of the graft, under lay, sandwich, ²⁰ bathplug technique, obliterative technique. There are many graft materials used in the literature. The authors adapted "multi-layered repair" of 'on-lay' and 'underlay' using thigh fat, fascia lata, surgical and gel foam. Tissue glue was not used in any of the author's cases for surgical repair^{21,22}.

All the CSF leaks, irrespective of the aetiology, lasting for more than 15 days were taken up for surgical repair. Those whose duration is less than 15 days were treated by medical management by advising bed rest 45 degrees head up, avoid strain/ constipation/ nose blowing, Acetazolamide 500mg tid for 2 weeks with potassium supplements, antibiotics for 10 days, lumbar drain for 3-5 days, 150-250ml/day.

All our cases that underwent repair of CSF leak were prepared with 4% xylocaine plus adrenalin 1 in 30,000 concentration ½hr before surgery. The anticipated site is explored endoscopically and identified the leak. In cases of difficulty in identification, the patients head is made low and with appositional Valsalva manoeuvre the leak site is identified in almost all cases. The thigh fascia was used as underlay graft and also on lay (Sandwich multi-layered), over which surgical and gel foam support was given. Merocel nasal pack was kept to support the assembly. The nasal pack was removed between 7-10 days. All patients were nursed 45 degree head up, Acetazolamide 250mg 1 TID and broad spectrum antibiotics for two weeks. No patient had any lumbar drain in the post-operative period. All patients were advised not to blow the nose and strenuous measures were avoided.

The site of leak ^{23,24}	Number of cases	Percentage [%]
Cribriform plate	64	86.48
Fovea (Anterior ethmoid)	4	5.2
Skull base (posterior ethmoid)	3	3.9
Lateral wall of sphenoid sinus	4	5.2
Roof of sphenoid sinus	1	1.3

Table 1

N=76.

Authors	No. of cases	Success at first attempt	success at second attempt	craniotomies
Papay et.al 1999	04	04(100%)	-	0
Mattox et al 1990	07	06(86%)	7(100%)	0
Stankiewicz 1995	06	06(100%)	-	0
Kelly et al 1996	08	07(88%)	8(100%)	0
Burns et al 1996	42	35(83%)	38(90%)	0
Lanza et al 1996	36	34(94%)	37(97%)	3
Venkat Ram Reddy et al 2016 (present series)	76	66(86%)	6(94%)	4

Table 2: Success rates of CSF leak repair

Papay et.al in 1999 reported successful repair in 4 cases out of 4 cases (100%). Mattox et.al in 1990 reported

successful endoscopic repair in 6 out of 7 cases (86%). Similarly Stankiewicz in 1995 reported 100% success rate in first attempt and Kelly et.al in 1996 reported 88% in first attempt and remaining 100% in the second attempt. These are small studies which cannot be comparable to our study. Burns et.al (42 cases), had shown the 83% in first attempt and 90% in the second attempt and similarly Lanza et.al (36 cases) in the same year had shown 94% in first and 97% in the second attempt, these studies are similar to our series of cases which shows the success rate of 86% in first attempt (66 cases out of 76 cases), 94% in the second attempt. The remaining 4 cases 5.2% were referred to Neurosurgeon for open neurosurgical approach.

CONCLUSIONS: Endoscopic endo nasal repair of CSF Rhinorrhoea provides a better field of vision with enhanced illumination, magnified angled visualization and also accurate positioning of graft placement under direct vision. As high success rate is attached to this method (94% success rate), it has become the preferred method for both spontaneous and traumatic CSF leaks, not associated with intracranial space occupying lesions.

High resolution CT scan with contrast, with or without contrast MRI is the investigation of choice for the confirmation of CSF leak.

Valsalva manoeuvre is of great help intra operatively to localize the site of leak in good number of cases.

Multi layered closure with under lay and on lay was the surgical technique adapted during surgery, to close the dural defect.

Good post-operative care is essential for successful outcome.

ACKNOWLEDGEMENTS: We thank Dr. S. Ramakrishna, HOD & Superintendent, Govt. ENT Hospital and Dr. S. Nirmala, RMO, Govt. ENT Hospital for permitting us to carry out this study and review the records of the patients. We thank our Ex Superintendents of this hospital Dr. C. Ramakrishna, Dr. MVV REDDY, Dr. S. Indira devi for their cooperation and support.

REFERENCES:

1. Muller C. Case of hydrocephalus, unusual appearance. Trans Med Chir Soc Edinb 1826;2:243-8.
2. King D. Report to west minister medical society lord. med.Surgical J 1834;4:823-5.
3. Thompson C CSF fluid,spontaneous escape from nose-London case11,1899.
4. Cairns.H. Injuries of frontal ethmoid. J laryngeal oto 1937;52:589-623.
5. Eden K. Taylor traumatic CSF rhinorrhoea repair fistula by trans frontal intradural operation. Br J Surgical 1941;29:299-303.
6. Ommaya AK, Di Chiro G, Baldwin M, et al. Non-traumatic cerebrospinal fluid rhinorrhoea. J Neurol Neurosurgery Psychiatry 1968;31(3):214-25.
7. Lanza DC, O'Brien DA, Kennedy DW. Endoscopic repair of CSF fistulae. Laryngoscope 1996;106:1119-1124.

8. Dohlman G. Spontaneous cerebrospinal rhinorrhea case operated by rhinologic methods. *Acta Otolaryngol Suppl* 1948;67:20-3.
9. Hirsch O. Successful closure of cerebrospinal fluid rhinorrhoea by endonasal surgery. *AMA Arch Otolaryngol* 1952;56(1):1-13.
10. Wigand WE. Transnasal ethmoidectomy under endoscopic control. *Rhinology* 1981;19(1):7-15.
11. Stamberger H, Greistorfer K, Wolf G, et al. Operativer verschluss. *Von Laryngol Rhinol Otol* 1997;76:595-607.
12. Schick. *Otol.Arch Nercher* 2001;108:279-582-264.
13. Burns JA, Dodson EE, Gross CW. Trans nasal endoscopic repair of cranionasal fistulae 1996;106:1080-1083.
14. Lloyd MN, Kimber PM, Burrows EH. Post traumatic cerebrospinal fluid rhinorrhoea: Modern high-definition computed tomography is all that is required for the effective demonstration of the site of leakage. *Clin Radiol* 1994;49:100-3.
15. Shetty PG, Shroff MM, Sahani DV, et al. Evaluation of high resolution CT and MR cisternography in the diagnosis of cerebrospinal fluid fistula. *Am J Neuroradiol* 1998;19(4):633-9.
16. Shetty PG, Shroff MM, Fatterprekar GM, et al. A retrospective analysis of spontaneous sphenoid sinus fistula:MR and CT findings. *Am J Neuroradiol* 2000;21(2):337-42.
17. Keer R, Weber RK, Draf W et al. Use of sodium fluorescein solution for detection of cerebrospinal fluid fistulas:an analysis of 420 administrations and complications in Europe and the United States. *Laryngoscope* 2004;114(2):266-172.
18. Chow JM, Goodman D, Mafee MF. Evaluation of CSF rhinorrhoea by computerised tomography with metrizamide. *Otolaryngol Head Neck Surgery* 1989;100(2):99-105.
19. Menelfe C, Cellerier P, Sobel D, et al. Cerebrospinal fluid rhinorrhoea: Evaluation with metrizamide cisternography. *Am J Roentgenol* 1982;138(3):47-6.
20. Wormald PJ, Mc Donough M. The bath -plug closure of anterior skull-base cerebrospinal fluid leaks. *Am J Rhinol* 2003;17(5):299-305.
21. EL Banhawy QA, Halaka AN, Altuwaijri MA, et al. Long-term outcome of endonasal endoscopic skull base reconstruction with nasal turbinate graft. *Skull base* 2008;18(5):297-308.
22. Weber SM, Kim J, Delashaw JB. Radial forearm free tissue transfer in the management of persistent cerebrospinal fluid leaks. *Laryngoscope* 2005;115(6):968-72.
23. Lindstrom DR, Toohill RJ, Loehrl TA, et al. Management of cerebrospinal fluid rhinorrhoea: Medical college of Wisconsin experience. *Laryngoscope* 2004;114(6):969-74.
24. Lanza DC, O'Brien DA, Kennedy DW. Endoscopic repair of cerebrospinal fluid fistulae and encephaloceles. *Laryngoscope* 1996;106(9 Pt 1):1119-25.