ORIGINAL ARTICLE

DEVELOPMENT OF SULCI & GYRI AT DIFFERENT FOETAL AGE GROUPS

M. S. Usha[1], K. Sudharani[2], P. Ratnachary[3]

HOW TO CITE THIS ARTICLE:
M. S. Usha, K. Sudharani, P. Ratnachary. "Development of Sulci & Gyri at Different Foetal Age Groups". Journal of Evidence based Medicine and Healthcare; Volume 2, Issue 22, June 01, 2015; Page: 3238-3251.

ABSTRACT: INTRODUCTION: The human nervous system is the most complex, widely investigated and yet poorly understood physical system known to mankind. The study of the development of human brain in utero is possible with investigations like ultrasound scanning and magnetic resonance imaging during pregnancy. At what week of gestation which part of brain is forming is known now. Progress of neuronal growth is assessed. It follows a predictable timetable. **AIM:** The aim is provide certain anatomical standards of neural developmental growth comparing already available imaging studies by physical dissection of fetuses and adult brains. **MATERIAL AND METHODS:** 50 fetuses (from 20 weeks of gestation) and 10 adult brains were dissected, formalin prepared and studied. Weight and volume also recorded. **OBSERVATIONS:** Are tabulated. **SUMMARY AND CONCLUSIONS:** Results are comparable with results of imaging studies.
KEYWORDS: Sulci, Gyri, Ultrasound, MRI, Cerebral Hemisphere.

INTRODUCTION: The Human Nervous system is the most complex widely investigated and yet poorly understood physical system known to mankind. Its structure and activities are inseparable from daily activities of life like physical, mental intellectual and cultural aspects. Brain is the basic organ of neural activity. The human brain is the seat of highly evolved intelligence that can set apart the species from all other living organisms by its proportional surface area and by weight to the body weight ratio and also by acquisition of true neopallium. The study of the structure and function of growing brain is important for assessing the functional and behavioral capacities. Human nervous system functions with about 10 million afferent neurons and 50 billion central neurons (West 1990)(1) and ½ million efferent neurons (output or motor neurons).

Brain is accommodated in a limited space – cranial box. The cerebral cortex is folded into numerous convolutions, the gyri separated by depressions, the sulci. The total surface area of cortex of human brain is about 2200 cm^2 in which one third of it is visible on surface and rest is obscured (William 1995).(2) The knowledge of sulci and gyri is helpful in differentiating the motor and sensory areas of brain e.g: central sulcus is a limiting sulcus. Sulci area also in relation to sutures – the squamo parietal suture is related to the posterior ramus of lateral sulcus. The lobes of brain are demarcated with the help of sulci. Overall arrangement of sulci and gyri are same. They appear during development of brain in an orderly sequence, but they vary in dimensions in different individuals and also on the right and left hemispheres of same individual.

Thorough understanding and appreciation of variation anatomy of sulcal and gyral pattern is useful to neuro surgeon while performing operations on brain. A part from surgical importance of sulci and gyri to the neuro surgeon, the anthropological indices are of importance to assess the evolution of brain. The convolution pattern is known to be dependent upon hereditary tendencies.

The development of brain starts right from intra uterine life evolving and maturing with the physical growth. In recent time's ultrasound and MRI studies have provided vast information on development patterns of sulci and gyri of cerebral hemispheres, their chronological order of appearance and importance in the fetal maturation and their variations in normal and abnormal fetuses. Abnormal sulcal patterns can be recognized based on the normal appearance. For each gestational age sulcal anomalies are quite specific as in holo prosencephaly, lissen cephaly, Schizen cephaly, micropoly gyry, and agenesis of the corpus callosum. Hence we have done a gross anatomical study of various physical parameters of brain like weight, volume, appearance in addition to the appearance and formation of culci and gyri at different gestational age groups to support the already available literature based on ultrasound and MRI studies.

MATERIALS AND METHODS: Materials: The material for the present study comprises of 50 foetal brains of different gestational age groups taken from dead fetuses collected from Government Maternity Hospital, Sultan Bazar and Government Maternity Hospital, Nayapool Hyderabad and ten adult brains collected from the cadavers from dissection hall of Anatomy Department, Osmania Medical College Hyderabad from 2001 - 2003. Ages of fetuses ranged from 5 months to full term. Age is determined by crown rump length, head circumference, foot length. (Keith Dewbury 1993).[3] Among 50 fetuses males are 42 and females are 8.

Instruments used:

1. Scalpel.
2. Toothed and non-toothed forceps.
3. Scissors - curved and plain.
4. Divider.
5. Metal scale graduated in centimeters.
6. Ordinary scale.
7. Thread.

As soon as dead foetus is received into department it is thoroughly washed with water and following data is recorded. (Table – 1, 2.)

1. Age
2. Sex
3. Weight
4. Crown rump length(CRL)
5. Foot length (FL)
6. Head circumference (HC)
7. Volume (CC)

Preservation of foetus: The fetuses are injected with 10% formalin through umbilical vessel, abdominal cavity and cranial cavity. After injecting formalin the embalmed fetuses are kept in formalin tanks containing 5% formalin solution for a minimum period of one month.

Removal of foetal brain: After one-month individual fetuses are removed from the tank, thoroughly washed under water. Skin of the scalp is reflected in four flaps after opening skull,

dura is cut and opened in four flaps. The falx cerebri is cut from crista galli and pulled back with one hand while the palm of other hand supports the brain from posterior aspect. Frontal lobes are gently separated and lifted back from anterior cranial fossa, olfactory bulbs are separated from cribriform plate of ethmoid, and later optic nerves are cut close to optic foramina. The removed fetal brains are left in formalin (10%) jars for 3 weeks for proper hardening. Volume is measured by water displacement method.

ADULT BRAINS: The brains from adult cadavers used for student dissections are removed adopting the same procedure for removal of fetal brains. The brains thus removed are preserved in 10% formalin.

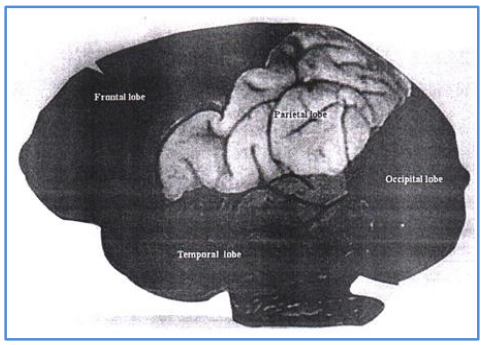

Fig. 1: Superolateral surface of cerebral hemisphere showing different lobes

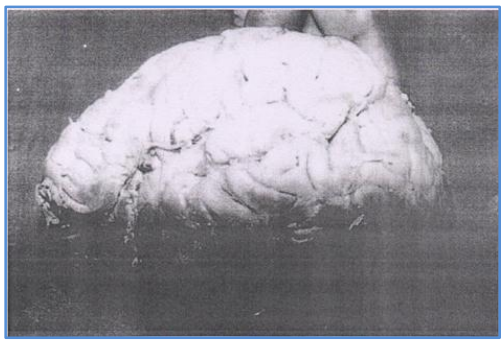

Fig. 2: Superolateral surface of adult cerebral hemisphers

NORMAL ANATOMY OF HUMAN CEREBRAL HEMISPHERE:

EMBRYOLOGY: All the appearance and development of sulci and gyri start from early 4th month of intra uterine life onwards and completed by term. In the 4th month parieto occipital sulcus first form on the medial side of the hemisphere. Posterior part of calcarine sulcus appears near occipital pole and extends forward. During 5th and 6th month cingulate sulcus appear on medial aspect of hemisphere. By the end of 8th month all important sulci are recognized. At term it represents adult brain in miniature.

GROSS ANATOMY: Cerebral hemispheres are two (right and left) and form largest part of the brain. They are broader behind than in front. The two hemispheres are incompletely divided into right and left hemispheres by a deep median fissure known as the longitudinal fissure. The longitudinal fissure completely separates the hemispheres in front and behind. In the middle they are connected by the corpus callosum.

Surfaces, border and poles of cerebral hemispheres: Each cerebral hemisphere has 3 surfaces and 3 poles. (Fig. I, II, III, IV, V, VI)

Surfaces:	**Poles:**
1. Supero lateral surface.	1. Frontal pole.
2. Medial surface.	2. Temporal pole.
3. Inferior surface.	3. Occipital pole.

Divisions of cerebral hemispheres: They are a) rostral frontal lobe, b) dorsal parietal lobe, c) caudal occipital lobe and d) ventral temporal lobe. The central sulcus is in between frontal and parietal lobes.

OBSERVATION: The present study is under taken in 50 foetal brains ranging from 20 weeks to full term. The weight of brain is taken without meninges and blood vessels. It is 204.9 gms in 36 weeks and 269 gms in 38 weeks; and 303.2 gms at term. The volume is 197.8 cc in 36 weeks, 199.2 cc in 38 weeks and 205.4 cc at term fetuses. (Table - 3).

Out of 50 brains 27 brains ranging from 36 weeks to full term have shown fully developed sulci. The measurements of sulci and gyri are taken from the foetuses of 38 weeks and more than 38 weeks gestational age. In rest of brains with gestational age below 38 weeks their time of appearance is noted. In adult specimens measurements are taken in 10 brains. The measurements of various sulci are tabulated (Table - 4). The measurements of various gyri are tabulated. (Table - 5)

DISCUSSION: The developmental maturity of normal foetal brain follows a predictable timetable. A thorough review of available literature revealed detailed ultrasonographic and MRI studies of sulcal and gyral patterns of brains on preterm and term foetuses by various authors. (Table no. 6, 7). Aim of their study was to physically study the development with the background of standards set by USG and MRI studies and gives the various parameters for different gestational age groups.

Weight and volume of foetal brains are studied at different age groups. The measurements of weight and volume of foetal brains could not be compared with any other data as there is no existing literature available.

The foetal brains of different age groups starting from 20 weeks gestational age are studied for the appearance and development of cerebral sulci and gyri on supero lateral, medial and inferior surfaces. Appearance and development of various sulci are studied by different authors by ultrasonography, MRI and also wherever possible by gross anatomical study. The sulci studied by different authors include central sulcus, sylvian fissure, post rolandic fissure, inferior temporal sulcus, calosal sulcus, cingulate sulcus, parieto occipital sulcus, calcarine sulcus, and collateral sulcus. The present study is compared with study of different authors and tabulated as above.

G.A. weeks	CRL mm	HC mm	FL mm	VOL cc	Weight gms
36	305	305	70	196	199.0
36	300	300	70	209	200
36	300	300	70	196	199.01
36	300	300	60	105	198.0
36	305	305	60	197	198.0
36	300	300	60	195	198.05
36	305	305	60	196	199.02
36	300	300	60	198	210.02
36	305	305	60	196	210.20

36	300	300	60	199	200.04
36	305	305	60	199	218.95
36	305	305	60	198	228.01
39	310	310	70	198	230.01
39	320	320	70	198	240.32
39	310	310	70	198	260.82
39	320	320	70	200	250.32
39	320	320	70	200	330.05
39	320	320	69	199	310.01
39	310	310	69	200	300.00
39	310	310	70	200	300.00
39	320	320	70	199	300.00
Term	340	340	71	200	301.01
-do-	345	345	71	202	300.1
-do-	340	340	71	206	300.1
-do-	345	345	70	206	299.01
-do-	340	340	70	210	299.09
-do-	345	345	70	208	310.02

Table 1: Measurements of foetal cri, head circumference, foot length & volume and weight of foetal brains

G.A.- Gestational age, CRL - Crown rump length, HC - Head circumference, FL - Foot length, VOL - Volume.

Age		**Crown – Rump Length**	**Weight**
Weeks	**Lunar months**	**(cms)**	**(gms)**
9-12	3	5-8	10-45
13-16	4	9-14	60-200
17-20	5	15-19	250-450
21-24	6	20-23	500-820
25-28	7	24-27	900-1300
29-32	8	28-30	1400-2100
33-36	8	31-34	2200-2900
37-40	10	35-36	3000-3400

Table 2: Growth in length and weight during foetal period

G. A.	**CRI**	**HC**	**FL**	**Vol.**	**Weight**	
					Foetal	**Adults**
Weeks	**mm**	**mm**	**mm**	**cc**	**gms**	**gms**
36	302.5	302.5	62.5	197.8	204.9	949.6/F 1151.4/M
38	315.6	315.6	69.8	199.2	269.0	
Term	342.5	342.5	70.00	205.4	303.2	

Table 3: Weight and volume of foetal brains corresponding to different gestational ages determined by cri. HC and FL

F/Female, M/ Male.

CRL – Crown Rump Length, HC – Head circumference, FL – Foot length, Vol. Volume.

		FOETAL						ADULT					
		Length (Cms)			Depth (Cms)			Length (cms)			Depth (Cms)		
Sl. No.	Name of sulci	Right	Left	Average	Right	Left	Average	Right	Left	Average	Right	Left	Average
1.	Central sulcus	5.10	5.40	5.25	0.70UE	0.70 UE	0.70UE*	9.10	9.16	9.15	1.40 UE	1.50 UE	1.45 UE*
					0.93 M	0.93 M	0.93M**				1.72 M	1.71M	1.71 M**
					0.314 LE	0.32 LE	0.63 LE***				1.23 LE	1.19 LE	1.21 LE ***
2.	Lateral suicus												
	Ascending Ramus	0.50	0.55	0.53	0.51	0.52	0.52	1.10	1.10	1.10	1.09	1.10	1.10
	Anterior Ramus	0.91	0.92	0.91	0.04	0.69	0.55	1.97	1.99	1.98	1.23	1.41	1.32
	Posterior Ramus	5.03	4.94	4.99	1.25	0.96	1.11	7.00	7.39	7.30	1.90	1.98	1.94
3.	Pre Central	4.10	4.40	4.25	0.85	0.80	0.81	8.00	7.50	7.75	1.50	1.41	1.46
4.	Superior Frontal	5.71	5.65	5.68	0.60	0.62	0.61	7.10	7.50	7.30	1.50	1.48	1.49
5.	Interior Frontal	2.09	2.08	2.09	0.59	0.60	0.60	3.76	3.79	3.78	1.35	1.36	1.36
6.	Superior Temporal sulcus	5.71	5.65	5.68	0.60	0.62	0.61	11.00	11.51	11.26	0.91	0.79	0.85
7.	Inferior temporal	-	-	-	-	-	-	5.00	4.99	4.10	0.98	0.99	0.99
8.	Post Central	4.18	4.19	4.19	0.80	0.70	0.75	7.40	7.38	7.39	1.58	1.57	1.58
9.	Intra Parietal	3.73	3.70	3.72	0.71	0.69	0.70	6.20	6.25	6.23	1.40	1.48	1.44
10.	Transverse Occipital	2.20	2.28	2.24	0.59	0.58	0.59	2.79	2.78	2.79	0.91	0.90	0.91
11.	Lateral occipital	1.92	2.01	1.97	-	-		2.90	3.30	2.95	0.80	0.81	0.91
12.	Cingulate	8.01	8.31	8.16	0.60	0.61	0.61	12.83	12.80	12.82	0.83	0.86	0.85
13.	Supra Splenial	1.10	1.11	1.11	-	-	-	1.80	1.82	1.81	-	-	-
14.	Calcarine	4.19	4.35	4.27	0.94	0.98	0.96	6.80	6.81	6.81	1.40	1.37	1.40
15.	Calcarine	4.19	4.35	4.27	0.94	0.98	0.96	6.80	6.81	6.81	1.40	1.37	1.40
16.	Olfactory	-	-	-	-	-	-	1.91	1.91	1.91	-	-	-
17.	Collateral	4.20	4.20	4.20	-	-	-	4.90	4.88	4.89	0.43	0.41	0.42
18.	Occipito Temporal	4.26	4.27	4.27	0.70	0.68	0.68	7.98	7.96	7.97	0.80	0.79	0.80

Table 4: Measurements of various sulci on foetal and adlt brains

UE/ upper end, M/Middle, LE/Lower end.

Name of the gyrus	Foetal		Adult	
	Length cms	Depth cms	Length cms	Depth cms
Precentral gyrus	4.98	0.70	7.00	0.99
Superior frontal gyrus	7.90	1.20	10.99	1.98
Middle frontal gyrus	4.98	0.94	8.28	1.40

Inferior frontal gyrus	3.00	0.81	4.00	1.40
Post central gyrus	4.95	0.14	9.00	1.00
Superior temporal gyrus	5.25	0.20	6.02	1.29
Middle temporal gyrus	5.20	0.99	10.00	1.50
Inferior temporal gyrus	3.72	0.70	7.10	0.80
Superior parietal Lobule	1.87	1.03	5.01	2.00
Inferior parietal Lobule	2.07	0.99	6.01	3.21
Superior occipital gyrus	2.15	1.52	4.11	2.98
Inferior occipital gyus	1.32	0.99	2.80	2.91
Cingulate gyrus	7.62	0.69	13.02	1.28
Medial frontal gyrus	6.16	0.99	11.0	2.07
Paracentral lobule	1.12	0.99	3.90	2.20
Isthamus	1.00	-	1.30	1.41
Gyrus with uncus	3.68	0.69	6.80	0.99
Precuneus	1.70	2.00	3.69	0.69
Cuneus	1.58	0.99	3.91	2.00
Gyrus recti	2.00	-	4.09	0.50
Anterior orbital gyrus	1.20	1.00	2.10	1.09
Posterior orbital gyrus	1.00	1.01	1.50	1.24
Medial orbital gyrus	2.00	1.39	4.00	1.69
Lateral orbital gyrus	1.60	0.80	2.20	0.90
Lingula	4.01	1.09	6.10	1.50
Medial occipito temporal	5.29	-	9.00	1.58
Lateral occipito Temporal	6.10	-	9.40	1.10

Table 5: Principal gyri on cerebral hemisphere and their measurements

Sl. No.	Name of the Author	Year	Type of study	Inter Hemispheric fissure	Central Sulcus	Post rolandic Sulcus (Post Central)	Sylvian fissure (Posterior Ramus)	Inferior Temporal Sulcus	Remarks
1.	Benard C et al[4]	1988	U.S.G	12 Weeks	-	-	21 Weeks	-	-
2.	Huang C.C[5]	1991	U.S.G	-	-	28-31 Weeks	Insular sulci 31 wks	28-31 Weeks	-
3.	Patriquin et al[6]	1992	U.S.G	-	-	-	-	-	During second trimester brain is smooth and homogenous and has few sulci and two large venricals

4.	Naidich et al[7]	1994	U.S.G and MRI	-	-	-	-	-	Ultasonographic display of anatomical features lack behind the initial appearance of the features by a variable interval
5.	Peter William[2]	1995			6th Month	6th month		6th month	

Table 6: Study of sulci on supero lateral surface of cererbal hemisphere by different authors by UG, MRI and gross study

Sl. No.	Name of the Author	Year	Type of study	Inter Hemisphe -ric fissure	Central Sulcus	Post rolandic Sulcus (Post Central)	Sylvian fissure (Posterior Ramus)	Inferior Temporal Sulcus	Remarks
6.	Vander knap MS et al[8]	1996	MR Images	-	-	-	-	-	Concluded that sulcal and gyral development was most advanced in areas of central sulcus and medial occipital area and is latest in fronto basal, fronto polar areas and the anterior part of temprol lobe. Simple staging system allows easy assessment of progress of cerebral gyration and sulculation in pre-term and term infants
7.	Monteaguda A et al[9]	1997	Transvaginal sonography		-		18 weeks	-	-
8.	Lan LM et al[10]	2000	MR Images	-	24-26 Weeks shallow groove	-	-	-	In 12-23 weeks is gestation age brain is smooth and in 24-26 weeks of gestation age shallow groove seen on central sulcus, 27 29 wks sulcal

									formation was observed in various regions and in 30 weeks sulci are seen on whole of cerebral cortex and opercula formation is not seen before 33 weeks.
9.	Garel C et al[11]	2001	MRI	-	-	-	-	-	Establish the time table by MRI for primary and secondary sulci for 22-38 weeks of gestation period which was in good agreement with neuro anatomic standards of reference with a mean lag time of 1 week.
10.	Present Study	2001 - 2003	Gross	Present in all specimens	22 wks	24 wks	26-28 wks	25 wks	

Table 7: Study of sulci on supero lateral surface of cererbal hemisphere by different authors by USG, MRI and gross study

SUMMARY & CONCLUSION: 50 Foetal brains of different age groups and 10 adult brains from cadavers are selected for study of the weight, volume and formation of cerebral sulcal and gyral patterns.

In foetal brains from the observations following conclusions are made;

1. Weight: Ranged from 204.9 gms, 269 gms and 303.2 gms at 36 weeks, 38 weeks, and term correspondingly.
2. Volume of foetal brain without meninges and blood vessels is 1997 cc. 199.2 cc, 209. 4 cc at 36 weeks, 38 weeks and term correspondingly.
3. The lateral surface of foetal brain up to 20 weeks gestational age is very smooth and featureless. (Fig. IX)
4. Central sulcus appeared as a very shallow depression at 22 weeks of gestation (Fig. X) Central sulcus is not cutting the superomedial border (Fig. XIX) and extending on to medial surface in few foetal and adult specimen.
5. Precentral sulcus, superior and inferior frontal, post central sulci made their appearance by 24 weeks (Fig. XI) and moderately developed by 28 weeks of gestation. Post central sulcus is seen in bits in few specimens (Fig. XX)
6. Posterior ramus of Sylvian fissure started differentiating very early and by 34-36 weeks it has almost completed its formation. Superior temporal sulcus is well demarcated by 24 weeks and inferior temporal sulcus developed a little latter (seen by 25 weeks).

7. Intraparietal and occipital sulci are seen as depression by 26 weeks.
8. Cingulate and callosal sulci are present as mere faint depressions by 20 weeks gestation. Calcarine and parieto occipital sulci are seen as one deeper depression by 23 weeks of gestational age. (Fig. XV, XVI, XVII)The exact time of appearance of these sulci on medial surface could not be stated as the study material is collected from 20 weeks gestational age.
9. Olfactory orbital sulci and collateral sulcus made their appearance by 23 weeks on the inferior surface (Fig. XVIII).
10. Insular opercula started appearing by 22 weeks (Fig. XII, XIII)
11. Gyri are well formed by full term but in early stage of development they are not completely formed.
12. At 36 weeks well developed temporal, frontal, parietal opercula are seen. (Fig. XIV)
13. These findings provide an anatomical data for comparing the prenatal studies of the foetal brain development and maturation by ultrasound, magnetic ray imaging investigations.

FIG – III : BASE OF ADULT BRAIN

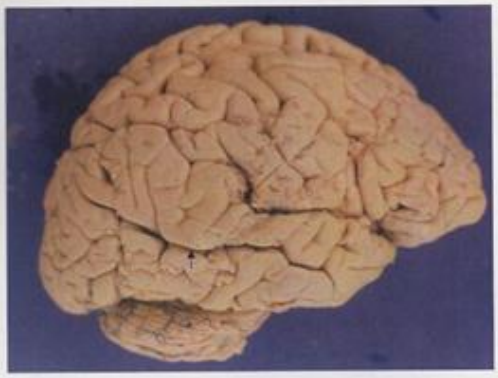

FIG – IV : SUPEROLATERAL SURFACE OF ADULT CEREBRAL HEMISPHERE. ARROW INDICATING SUPERIOR TEMPORAL SULCUS EXTENDING INTO OCCIPITAL LOBE

FIG – V : INFERIOR SURFACE OF ADULT CEREBRAL HEMISPHERES

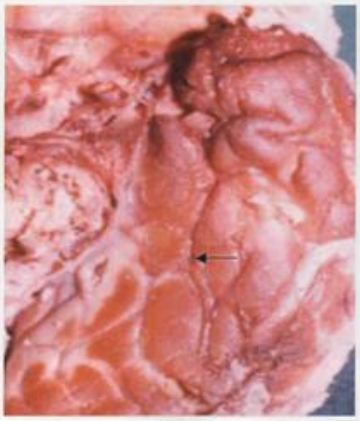

FIG – VI : ENLARGED PHOTOGRAPH OF ABOVE SPECIMEN ARROW POINTING THE CONTINUITY OF RHINAL SULCUS WITH COLLATERAL SULCUS

FIG – VII : BASAL ASPECTS OF FOETAL BRAIN WITH MENINGIES AND BLOOD VESSELS

FIG – VIII : LATERAL ASPECTS OF FOETAL BRAIN ALONG WITH MENINGIES AND BLOOD VESSELS

FIG – IX : LATERAL ASPECTS OF FOETAL BRAIN OF 20 WEEKS GESTATION SHOWING ABSENCE OF SULCI & GYRI, DEMARCATED LATERAL CEREBRAL FOSSA, ABSENCE OF OPERCULA IN THE INSULAR AREA

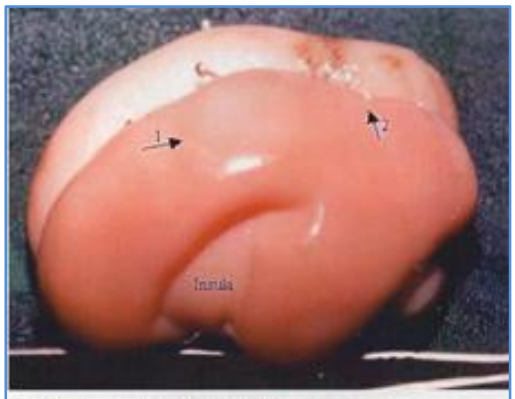

FIG – X : CEREBRAL HEMISPHERE OF FOETAL BRAIN (22 WEEKS GESTATION) SHOWING DEPRESSION IN THE REGION OF 1. CENTRAL SULCUS, 2. PARIETO OCCIPITAL SULCUS & EXPOSED INSULA WITH DEVELOPING OPERCULA

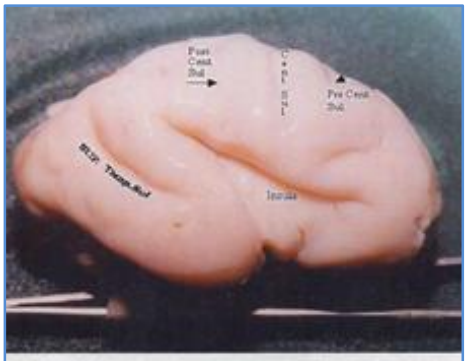

FIG – XI : LATERAL SURFACE OF FOETAL CEREBRAL HEMISPHERE OF 24 WEEKS GESTATION WELL DEMARCATED CENTAL SULCUS & SUPERIOR TEMPORAL SULCUS, DIFFERENTIATING POST CENTRAL & PRECENTRAL SULCI, INSULA COVERED BY OPERCULA TO A GREATER EXTENT.

FIG – XII : FOETAL BRAINS OF 24 WEEKS & 28WEEKS GESTATION SHOWING DEGREES OF EXPOSURE OF INSULA

FIG – XIII : ENLARGED VIEW OF INSULAR REGION OF FOETAL BRAINS OF 24 & 28 WEEKS GESTATION. OPERCULA COVERING ALMOST ENTIRE INSULA IN 28 Wks SPECIMEN WHICH ALSO SHOWS APPEARANCE OF SULCI AND DEMARCATION OF GYRI ON SURFACE

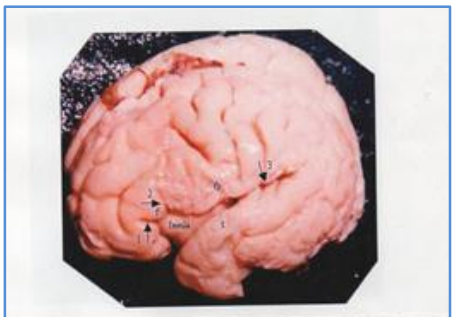

FIG – XIV : LATERAL VIEW OF CEREBRAL HEMISHERE OF 36 WEEKS GESTATION SHOWING WELL DEVELOPED TEMPORAL OPERCULA (t), FRONTO PARIETAL OPERCULA (fp),FRONTAL OPERCULA (f) – WELL DEMARCARED 3 RAMI OF LATERAL SULCUS 1. ANTERIOR, 2. ASCENDING & 3. POSTERIOR RAMI. MOST OF THE INSULA IS COMPLETELY COVERED EXCEPT A SMALL PART

FIG – XV : MEDIAL SURFACE OF CEREBRAL HEMISPHERE OF FOETAL BRAIN OF 23 WEEKS GESTATION SHOWING WELL DEMARCATED CALCARINE AND PAREITO OCCIPITAL SULCI AND JUST DEVELOPING CINGULATE SULCUS

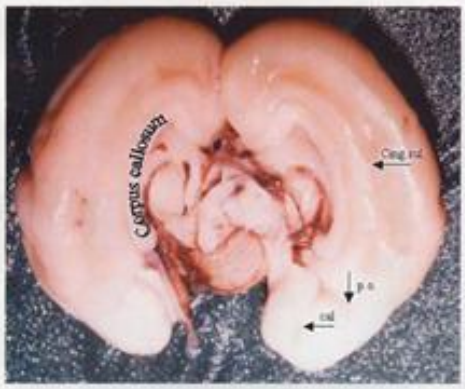

FIG – XVI : MEDIAL SURFACE OF FOETAL CEREBRAL HEMISPHERE OF 24 WEEKS GESTATION SHOWING WELL DEMARCATED CINGULATE SULCUS(cing.sul), PARIETO OCCIPITAL SULCUS(p.o) AND CALCARINE(cal) SULCUS

FIG XVII : MEDICAL SURFACE OF FOETAL CEREBRAL HEMISPHERE OF 23 WEEKS GESTATION SHOWING WELL FORMED CALCARINE SULCUS, DEVELOPING CINGULATE SULCUS AND OTHER SMALL SULCI

FIG – XVIII : INFERIOR ASPECTS OF FOETAL BRAIN OF 23 WEEKS GESTATION SHOWING: 1. ORBITAL SULCI 2. RHINAL SULCUS 3. LIMEN INSULA OLFACTORY SULCUS

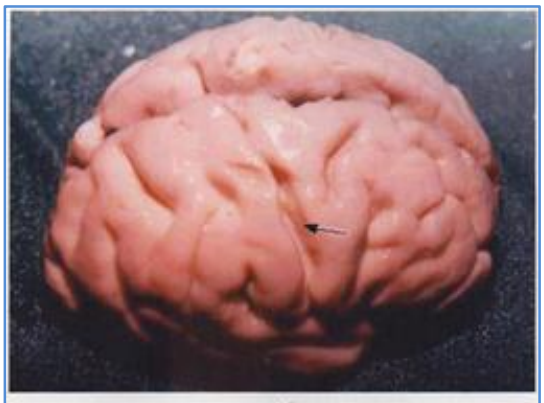

FIG – XIX : FOETAL CEREBRAL HEMISPHERE OF 32 WEEKS GESTATION SHOWING WELL DEVELOPED SULCI AND ARROW INDICATING CENTRAL SULCUS WITHOUT INTERLOCKING GYRI

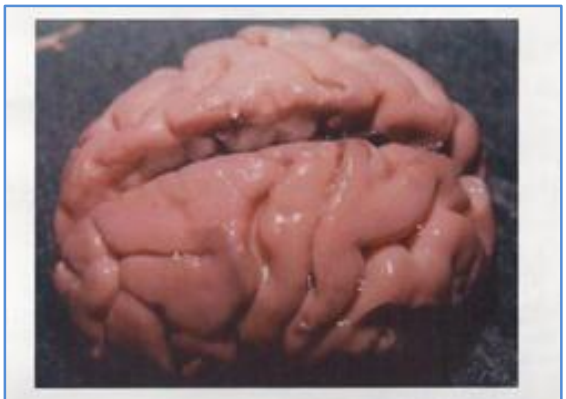

FIG – XX : LATERAL SURFACE OF FOETAL CEREBRAL HEMISPHERE OF 38 WEEKS GESTATION SHOWING WELL DEVELOPED SULCI. THE SUPERIOR FRONTAL SULCUS IS NOT CUTTING INTO PRECENTRAL SULCUS POST CENTRAL SULCUS IS IN BITS

ACKNOWLEDGEMENT: The present study of "The Development of sulci and gyri at different foetal age groups" was undertaken by us in the department of Anatomy, Osmania Medical College, Hyderabad, under the guidance of Professor and HOD Department of Anatomy, Osmania Medical College.

Our special thanks to Superintendent of Govt. Maternity Hospital, Sultan Bazar, Hyderabad to fetch the foetuses. We express my gratitude to Principal, Osmania Medical College, Hyderabad.

BIBLIOGRAPHY:

1. West, John B 1990 Best and Taylor's Physiological basis of Medical. Practice, 12th ed. P. 926.
2. Williams Peter. L 1995 Gray's Text Book of Anatomy 38th edition P. 1108, 1109, 250.
3. Keith Dewbury.1993 Ultrasound in obstetrics and gynaecology Hylton Meire, et al Churchill Livingstone P. 528
4. Bernard C,1988 Echographic aspects of cerebral Droulle P, et al sulci in the ante – and perinatal Period (Article in French) J. Radiol: Aug – Sep: 69 (8 – 9): 521 – 32.
5. Hung CC., 1991 Sonographic cerebral sulcal development in premature new borns Brain Dev: 13 (1): 27-31.
6. Patriquin H 1992 Development of fetal brain in the second Fontaine S. et al trimester: an anatomic and ultrasonographic Demonstration. Can Assoc Radiol J Apr: 43 (2): 131-7.
7. Naidich TP, 1994 the developing cerebral surface. Grant JL, et al Preliminary report on the patterns of sulcal and gyral maturation – anatomy, ultrasound, and magnetic resonance imaging. Neuroimaging Clin N AM May: 4(2): 201-40.
8. Van der Knaap MS, 1996 Normal gyration and sulcation in Van Wezel-meijler G, et al preterm and term neonates: Appearance on MR images. Radiology Aug: 2000 (2): 389-96.
9. Monteagudo A, 1997 Development of fetal gyri, sulci and Timor-Tritsch IE et al fissures: a transvaginal sonographic study Ultrasound obstet Gynaecol Apr; 9 (4): 222- 8.

10. Lan LM 2000 Normal fetal brain development: Yamashita Y et al Mr imaging with a half – Fourier rapid Acquisition with relation enhancement Sequence Radiology Apr: 215 (1): 205 – 10.
11. Garel C, et al 2001 Foetal cerebral cortex: normal Gestational land marks identified using prenatal MR imaging. AJNR AM J Neuroradiol Jan: 22 (1): 184-9.

AUTHORS:

1. M. S. Usha
2. K. Sudharani
3. P. Ratnachary

PARTICULARS OF CONTRIBUTORS:

1. Formerly Assistant Professor, Department of Anatomy, Osmania Medical College, Hyderabad.
2. Formerly Assistant Professor, Department of Anatomy, Osmania Medical College, Hyderabad.
3. Physician, Department of Medicine, ESI DC, Jeedimetla, Hyderabad.

NAME ADDRESS EMAIL ID OF THE CORRESPONDING AUTHOR:

Dr. K. Sudharani,
Associate Professor,
Gandhi Medical College,
Secunderabad.
E-mail: sudharani.kandukuru@gmail.com

Date of Submission: 17/05/2015.
Date of Peer Review: 18/05/2015.
Date of Acceptance: 22/05/2015.
Date of Publishing: 27/05/2015.