

## DESCRIPTIVE ANALYSIS OF FUNCTIONAL OUTCOME OF ARTHROSCOPIC REPAIR OF RECURRENT ANTERIOR SHOULDER DISLOCATION

Kumaraswami Ramulu Dussa<sup>1</sup>, Aseem Niranjana Parekh<sup>2</sup>, Kiran Sudhakar Belsare<sup>3</sup>, Jitesh Ramesh Shinde<sup>4</sup>, Nazmuddin Jainuddin Jetaji<sup>5</sup>

<sup>1</sup>Associate Professor, Department of Orthopaedics, B. Y. L. Nair Charitable Hospital & T. N. Medical College, Mumbai, Maharashtra, India.

<sup>2</sup>Professor & HOD, Department of Orthopaedics, B. Y. L. Nair Charitable Hospital & T. N. Medical College, Mumbai, Maharashtra, India.

<sup>3</sup>Senior Registrar, Department of Orthopaedics, B. Y. L. Nair Charitable Hospital & T. N. Medical College, Mumbai, Maharashtra, India.

<sup>4</sup>Senior Registrar, Department of Orthopaedics, B. Y. L. Nair Charitable Hospital & T. N. Medical College, Mumbai, Maharashtra, India.

<sup>5</sup>Senior Registrar, Department of Orthopaedics, B. Y. L. Nair Charitable Hospital & T. N. Medical College, Mumbai, Maharashtra, India.

---

### ABSTRACT

---

#### BACKGROUND

Anterior glenohumeral dislocation is a commonly seen pathology in clinical practice of orthopaedic traumatology. This is a study of the functional outcome of arthroscopic Bankart repair in forty patients.

#### MATERIALS AND METHODS

Forty patients with posttraumatic anterior dislocation of shoulder were treated by arthroscopic repair from Jan 2012 to June 2104. Forty patients, with an average age of 28.96 years (range 20-40 years), were reviewed in the study. The average followup period was 6 months. University of California, Los Angeles Shoulder Rating Scale was used to evaluate the outcome after surgery. The scale takes into account the recurrence rates, range of motion, as well as postoperative function and return to sporting activities.

#### RESULTS

Thirty four patients (85.00%) had satisfactory results, whereas six patients (15.00%) had unsatisfactory results. Eighty five percent patients had stability compared with the normal-sided shoulder and were able to return to sports. There were no cases of redislocation observed in this study.

#### CONCLUSION

Arthroscopic Bankart repair using suture anchors to reattach the torn labroligamentous complex is a treatment method with good functional outcomes, reliable results and satisfactory postoperative shoulder motion with low recurrence rates.

#### KEYWORDS

Bankart's lesion, Shoulder instability, Arthroscopic repair.

---

**HOW TO CITE THIS ARTICLE:** Dussa KR, Parekh AN, Belsare KS, et al. Descriptive analysis of functional outcome of arthroscopic repair of recurrent anterior shoulder dislocation. J. Evid. Based Med. Healthc. 2016; 3(27), 1216-1221.

DOI: 10.18410/jebmh/2016/281

---

**INTRODUCTION:** Anterior glenohumeral dislocation is a commonly seen pathology in clinical practice of orthopaedic traumatology. The incidence of anterior glenohumeral instability has been reported as 2%.<sup>1</sup> The glenohumeral joint has been reported as the most commonly dislocated synovial joint in human body.<sup>2</sup> Forced abduction and external rotation of the shoulder can cause dislocation resulting in instability.<sup>3</sup>

Rhee et al.<sup>4</sup> mentioned that the age at the time of the first dislocation and athletic activity were related to early redislocation and a high frequency of dislocation. Because of increasing participation of population of all ages in sporting activities, orthopaedicians dealing with trauma care patients must have thorough understanding of anatomy, pathophysiology, risk factors and management of anterior shoulder instability. Degenerative arthropathy in shoulder joint is generally the final result of chronic instability.<sup>5</sup>

Shoulder joint by virtue of its anatomy and biomechanics is one of most frequently dislocated joint in body.<sup>6</sup> Bankart published paper stating that in acute dislocation, the humeral head is forced anteriorly out of glenoid cavity and tears not only fibrocartilaginous labrum from entire anterior half-rim of glenoid cavity but also capsule and periosteum

---

*Financial or Other, Competing Interest: None.*  
*Submission 10-03-2016, Peer Review 24-03-2016,*  
*Acceptance 31-03-2016, Published 02-04-2016.*  
*Corresponding Author:*  
*Dr. Kumaraswami Ramulu Dussa,*  
*#1/1, Doctors Staff Quarters,*  
*Government Colony, Near Mahalaxmi Race Course,*  
*Haji Ali, Mumbai, Mumbai-400034.*  
*E-mail: drkumardussa@gmail.com*  
*DOI: 10.18410/jebmh/2016/281*

---

from anterior surface of neck of scapula. This traumatic detachment of glenoid labrum has been called Bankart lesion.<sup>7</sup>

The Bankart lesion represents most common form of labroligamentous injury in patients with traumatic dislocation of the shoulder. The socket deepening effect of glenoid labrum has an important factor in maintaining stability. Reattaching the labrum on to the articulating surface restores its socket deepening effect; this is accomplished using suture anchor by either open or arthroscopic method.<sup>8,9</sup>

The surgical treatment is accomplished by reattachment of labroligamentous complex to glenoid either arthroscopically or by open procedure known as Bankart repair.<sup>10</sup> With continuing criticism of wide dissection, loss of external rotation and postoperative pain associated with open repair, the demand of arthroscopic surgery has increased over the last two decades. Also there have been reported cases of subscapularis insufficiency and subscapularis tendon rupture following open repair.<sup>11,12</sup> The arthroscopic Bankart repair offers minimally invasive procedure with less surgical trauma, less blood loss with improvement in operative time, perioperative morbidity, narcotic use, hospital stay, time loss from work, less number of complications, cost of surgery and better cosmetic results.<sup>13,14</sup>

Hereby, we analyse the functional outcome of arthroscopic Bankart repair in patients with recurrent anterior shoulder dislocation. The aims and objectives of our study are descriptive analysis of functional outcome of arthroscopic repair of recurrent anterior shoulder dislocation, compare preoperative and postoperative pain in patients, compare preoperative and postoperative active forward flexion and strength and compare preoperative and postoperative satisfaction and function in patients with arthroscopic Bankart repair.

**MATERIALS AND METHODS:** This study has been done to analyse the functional outcome of arthroscopic Bankart repair in 40 cases of recurrent anterior shoulder dislocation operated between January 2012 to June 2014, details of which have been collected from T. N. Medical College & Nair Hospital Medical Record Office (MRO) using University of California, Los Angeles Shoulder Scale (UCLA) considering patient's pain, function, strength, active forward flexion and patients' satisfaction. Population included males and females between 20-50 years. Type of study is descriptive retrospective cross-sectional study.

History, physical examination findings and investigations like MRI shoulder were documented. The UCLA Score report was maintained before and after surgery. We requested for waiver of consent as all the patient's data was accessed from the Medical Records Office and Department Records.

**Inclusion Criteria:** Inclusion criteria were age between 20 and 40 years, recurrent shoulder dislocation with Bankart lesion confirmed on MRI, patients with only posttraumatic recurrent anterior shoulder dislocation.

**Exclusion Criteria:** Exclusion criteria were patients with bony lesion more than 30% of the glenoid rim, patients with associated injury like rotator cuff tear, glenoid fracture and proximal humerus fractures, patients with other causes of recurrent shoulder dislocation like epilepsy and muscle paralysis, mentally retarded and non-cooperative patients, patients operated more than once for Bankart repair.

UCLA scale was used to evaluate the patient's pain, function, active forward flexion, strength in forward flexion, and patient satisfaction. The maximum total score possible is 35, with a higher score indicating better shoulder function. We assigned a score of 34-35 points as excellent, 28-33 points as good, 21-27 as mild, and 20 or less as poor. Excellent and good scores were taken as satisfactory. The patients were followed up at 2 weeks, 1 month, and then at 6 monthly intervals. All patients had a minimum of 1 year's followup. Treatment failure was regarded as recurrent shoulder dislocation, any sensation of subluxation or instability preventing return to full activity or requiring a further stabilising procedure.

#### **Arthroscopic Bankart's Repair: Surgical Steps:**

1. Anterior portal position. An outside-to-inside technique ensures the position and trajectory of the portals created.
  - a. Low anterior portal created just superior to the subscapularis tendon, which is critical for capsular release and mobilisation as well as placement of the 5 o'clock anchor.
  - b. Superoanterior portal created just anterior to the biceps tendon, allowing secondary suture management portal or superior labral anterior to posterior (SLAP) reconstruction.
2. Capsular release and anterior glenoid neck preparation (Fig. 1).
  - a. Through the low anterior portal, release the capsulolabral complex from the glenoid neck to the 6 o'clock position for a distance of 1 to 2 cm medially along the glenoid neck.
  - b. Decorticate the anterior glenoid neck using an arthroscopic bur.
  - c. Grasp the labrum to ensure that it can be readily shifted superiorly and onto the glenoid fossa into its normal position. Adequate mobilisation is achieved when the underlying subscapularis muscle is seen.
3. Anchor position and suture passing.
  - a. Anchors are inserted onto the glenoid face near the periphery at the 3, 4, and 5 o'clock positions when necessary (right shoulder). Anchors are placed one at a time, and the sutures are passed and tied before subsequent anchor placement.
  - b. The capsulolabral complex is captured at the 6, 5, and 4 o'clock positions corresponding to the 5, 4, and 3 o'clock anchor positions, respectively. This tissue capture management effectively shifts the capsulolabral tissue superiorly and onto the glenoid fossa (Fig. 2).

- c. The 5 o'clock anchor is placed, and its security in the osseous tunnel is confirmed (Fig. 2). Placement of the 5 o'clock anchor and its suture passage are the most critical steps; they will determine the amount of subsequent tissue captured by the more proximal anchors. Lateral and posterior translation of the humerus is helpful during 5 o'clock anchor and suture placement.
- d. Use of a commercially available suture shuttle or use of a 48-inch looped Prolene suture allows for capture of the tissue at the 6 o'clock position for the 5 o'clock suture anchor.

Suture management is improved by placing the "articular" suture through the superior cannula, so as to shuttle the capsular suture through the low anterior portal. If desired, shifting of the labrum is facilitated by placing a grasper through the superior portal during suture passage. Knot tying is performed based on the surgeon's preference. These simple sutures typically slide easily without fraying or hanging up at the soft tissue-anchor interface.<sup>8,15,16,17</sup>

**RESULTS AND OBSERVATIONS:** Statistical analysis has been done using SPSS version 16 software. Wilcoxon signed ranks tests were applied to determine whether the difference is significant.

Our study included 40 patients out of which 29 were between 20-30 years of age and 11 were between 31-40 years. Mean age was 28.96 years. Recurrent shoulder

dislocations are common in young population group. 34 patients were male and 6 patients were female. Majority of patients (85 percent) were male. Out of 40 patients, 30 (75%) patients had right-sided extremity involved. There was no patient with bilateral involvement. Right-sided (dominant) involvement is more common than left.

**SCORE (UCLA Shoulder Score):** The preoperative UCLA shoulder mean score of 9.93 with a standard deviation of 1.711 improved to 28.15 with a standard deviation of 3.544. There is statistically significant difference between preoperative and postoperative patients with respect to postoperative UCLA shoulder score with p-value <0.05. (table 1)

As per UCLA shoulder score, at the end of 6 months, 6 patients had fair outcome with scores between 21-27 and 34 patients had good outcome with scores between 28-33. This is 15% fair and 85% good outcome.

With respect to postoperative pain, there was significant improvement noted. This has been shown in the table no 2. Individual pain scores from UCLA score were compared and statistical test of significance was applied. There is significant improvement in postoperative function as shown in table 3. There is significant improvement in postoperative satisfaction as shown in table 4. There is significant improvement in postoperative strength as shown in table 5. There is significant improvement in postoperative flexion and range of motion as shown in table 6.

Score	Mean	Std. Dev	Median	IQR	Wilcoxon Signed Ranks Test	P value
Pre	9.93	1.711	9.00	3.000	-6.800	0.000
Post	28.15	3.554	29.00	4.000	Difference is significant	
					p 0.000037	

**Table 1: Comparison of "Pre" and "Post" among study group**

Pain	Mean	Std. Dev	Median	IQR	Wilcoxon Signed Ranks Test	P value
Pre	2.52	0.887	2.00	2.000	-6.949	0.000
Post	7.61	1.084	8.00	2.000	Difference is significant	
					p -0.000036	

**Table 2: Comparison of Preoperative and Postoperative pain among study group**

Function	Mean	Std. Dev.	Median	IQR	Wilcoxon Signed Ranks Test	P value
Pre	2.92	1.005	2.00	2.000	-6.951	0.000
Post	7.93	1.209	8.00	0.000	Difference is significant	
					p-0.000039	

**Table 3: Comparison of Preoperative and Postoperative function among study group**

Satisfaction	Mean	Std. Dev	Median	IQR	Wilcoxon Signed Ranks Test	P value
Pre	0.00	0.000	0.00	0.000	-7.416	0.000
Post	4.51	1.501	5.00	0.000	Difference is significant	
					p-0.000035	

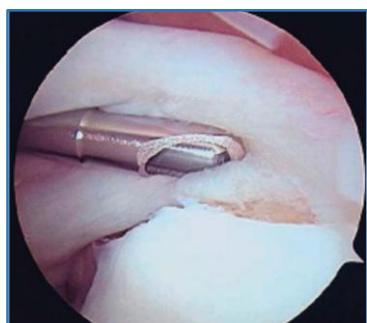**Table 4: Comparison of Preoperative and Postoperative among study group for satisfaction**

Strength	Mean	Std. Dev.	Median	IQR	Wilcoxon Signed Ranks Test	P value
Pre	2.36	0.484	2.00	1.000	-6.753	0.000
Post	4.28	0.662	4.00	1.000	Difference is significant	
					p 0.000034	

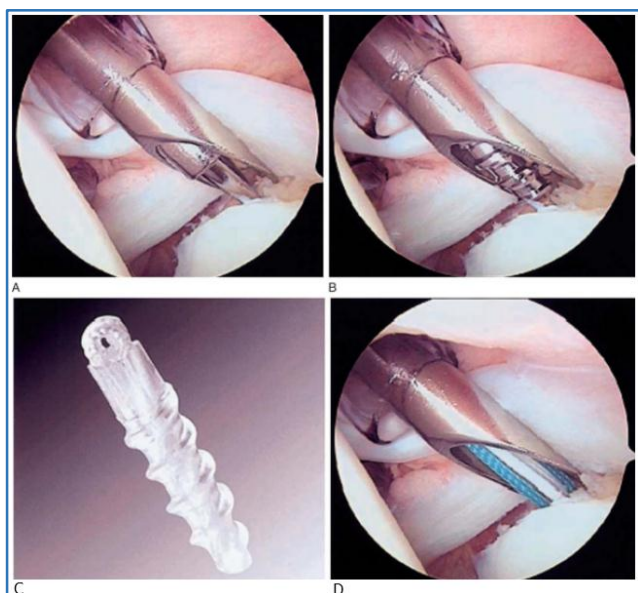
**Table 5: Comparison of Preop and Postop among study group for strength**

Flexion	Mean	Std. Dev	Median	IQR	Wilcoxon Signed Ranks Test	P value
Pre	2.13	0.386	2.00	0.000	-7.013	0.000
Post	4.08	0.493	4.00	0.000	Difference is significant	
					p-0.000036	

**Table 6: Comparison of Preoperative and Postoperative among study group for flexion**



**Fig. 1: Glenoid preparation**



**Fig. 2**

**Figure 2:** Arthroscopic suture anchor insertion. A, 3.5-mm Arthrex Spear delivery guide placed through anterosuperior portal beneath root of biceps. Angled opening of Spear Guide allows retraction of biceps–superior labral complex by guide while viewing instrumentation through angled mouth. Pilot hole for suture anchor produced by 2-mm punch. B, 3-mm tap placed through delivery device to create threaded channel for suture anchor. C and D, 3-mm biodegradable Bio-FASTak suture anchor, placed through guide to prethreaded channel, may accommodate one or two sutures

**DISCUSSION:** Anterior glenohumeral instability is the most common form of instability around the shoulder

joint.<sup>18,19</sup> It usually affects young adults and most of the cases arise secondary to traumatic dislocations. In our study, 76.76% patients were between 21 to 30 years with a mean age of 28.96 years.

Rowe and Zarins reported a rate of 95.6% traumatic origin to anterior dislocation in their study that included 500 patients.<sup>20</sup> Similarly, all patients, 100%, in our study had recurrent anterior glenohumeral instability following initial traumatic anterior dislocation, as our study included only patients with posttraumatic recurrent shoulder dislocation.

Historically, arthroscopic repair for the treatment of the Bankart lesion had been less satisfactory than the open technique.<sup>21</sup> Arthroscopic techniques described previously used transglenoid sutures or bioabsorbable tracks.<sup>22</sup> In the past few years, newer techniques involving suture anchor fixation and capsular plication have evolved with promising results. Suture anchors are low-profile fixation devices that minimize articular surface damage of the humeral head offering anatomic reconstruction of the glenoid labrum as well as the glenohumeral ligament complex. Any redundant or loose capsule is also addressed during the same operation allowing one to address any capsular laxity, restoring tension in the anterior-inferior glenohumeral ligament and stability to the glenohumeral joint.

Open method of Bankart repair has several limiting factors, which renders it a less favourable option. It causes an increased blood loss during surgery, a prolonged period of stay in the hospital and a significant loss of range of motion. In the classic open Bankart repair, there is disruption of the subscapularis tendon, which may result in postoperative subscapularis insufficiency; in addition, there have been reported cases of postoperative subscapularis tendon rupture. The arthroscopic Bankart repair offers a minimally invasive approach with less surgical trauma and blood loss, with improvements in operating time, perioperative morbidity, narcotic use, hospital stay, time loss from work, and decrease in number of complications together with a lower cost of surgery and cosmetic. Postoperative recovery and rehabilitation is faster than open surgical techniques. Postoperative range of motion is also not sacrificed for the sake of stability. Patients are able to have a good range of motion functionally, especially external rotation, which allows them to return to their sports or high-demand jobs.<sup>23,24</sup>

We have also shown that postoperative range of motion is not sacrificed for the sake of stability, and good functional outcome with mean UCLA score of 28.15 We used the UCLA system because it was one of the first shoulder outcome measures that was introduced, the test is easy to administer and clinicians who want to quickly and simply evaluate outcomes for a variety of diagnoses find UCLA to be helpful.<sup>25,26</sup> We found a lot of research papers based on this score<sup>27</sup> and so a formal comparison between different studies could be performed. Although it lacks formal validation, we have included it because of its historic standing and continued popularity.

Out of sixty patients, 52 patients had good functional outcome and eight patients with fair functional outcome. Out of these eight, six were those whose physiotherapy sessions were not supervised. We did not encounter any problems with either subscapularis muscle dysfunction or rupture. There were no cases of redislocation postoperatively observed in our study; however, three cases had mild laxity (grade I) of the joint, which were asymptomatic and not associated with any difficulty in lifting the arm up or limitation of the ability to do overhead activity.

Gartsman et al performed arthroscopic Bankart repair, capsular plication, and if necessary thermal capsulorrhaphy in 53 patients with anteroinferior shoulder instability. After 2 years followup, good and excellent results were 92%, and 7.5% had recurrence.<sup>26</sup> Mishra and Fanton reported a failure rate of 7% with arthroscopic Bankart repair combined with thermal treatment.<sup>24</sup> Seddek et al. reached at a 92.5% successful rate after arthroscopic treatment of 40 shoulders.<sup>10</sup>

Our study shows results 86.67% had good functional outcome and 13.33% had fair functional outcome with mild instability in 5.0% patients which was similar to the above-mentioned studies.

In a prospective study by Karlsson et al. comparing arthroscopic and open methods, after a mean duration of 28 months, external rotation in abduction was 65° in open group and 83° in arthroscopic group postoperatively.<sup>28</sup> Gartsman et al. and Synder et al.<sup>29</sup> both reported a 5° decrease in external rotation.in a study done by Mishra et al<sup>30</sup> Thirty six patients (72.0%) had excellent results, whereas seven patients (14.0%) had good results. The mean pre- and postoperative range of external rotation was 80.38° and 75.18°, respectively. Eighty-six percent patients had stability compared with the normal-sided shoulder and were able to return to sports.

Chart showing comparison of our study and previous studies

Study	Our study	Rowes	Gartsmans
Satisfactory results (excellent +good)	86%	94%	92%
Unsatisfactory results% (mild+poor)	14%	6%	8%

This limitations of the study are relatively small sample size, lack of comparison with open procedure, and short-term followup of one year. We conclude that arthroscopic Bankart repair with suture anchors for recurrent anterior glenohumeral instability is an excellent procedure as our study shows good postoperative functional outcome in terms of range of motion, pain, strength and patient’s satisfaction.

**SUMMARY AND CONCLUSION:** In this study, forty patients with Bankart lesion on MRI were operated arthroscopically with suture anchors were analysed. The functional outcome was calculated at the end of six months after surgery with help of UCLA Shoulder Score. Mean age of the population of study group was 28.96 years. After comparing the findings and functional score at 6-month followup after surgery with that of preoperative, we have found significant difference both in terms of overall postoperative UCLA Shoulder Score and in terms of improvement in range of shoulder motion, postoperative pain, strength, and overall satisfaction.

We can hence conclude that arthroscopic Bankart repair for recurrent anterior dislocation of shoulder shows good functional outcome, good range of motion, and is more cosmetic and with short hospital stay.

**CONSENT:** The patients have given the necessary consent for the case report to be published.

**BIBLIOGRAPHY:**

1. Hovelius L, Augustini BG, Fredin H, et al. Primary anterior dislocation of shoulder in young patients, a ten year prospective study. J Bone Joint Surg Am 1996;78(11);1677-1684.
2. Dodson CC, Cordaso FA. Anterior glenohumeral joint dislocations. Orthop clin North Am 2008;39(4):507-508.
3. Kaplin LD, Flanign DC, Norwig J, et al. Prevalence and variance of shoulder injuries in elite collegiate football players. Am J Sports Med 2005;33(8):1142-1146.
4. Rhee YG, Cho SH. Traumatic anterior dislocation of the shoulder: Factor affecting the progress of traumatic anterior shoulder dislocation. Cin Orthop Surg 2009;1(4):188-193.
5. Hovelius L, Saeboe M. Neer award 2008: Arthropathy after primary shoulder anterior dislocation -223 shoulder prospectively followed up for twenty five years. J Shoulder Elbow Surg 2009;18(3):339-347.
6. Erkoç OF, Yel M. The functional result of arthroscopic Bankart repair with knotless anchor for anterior glenohumeral instability. Eur J Gen Med 2010;7(2):179-186.
7. Bankart AS. Recurrent or habitual dislocation of the shoulder joint. BMJ 1923;2(3285);1132-1133.
8. Fabbriani C, Milano G, Demontis A, et al. Arthroscopic versus open treatment of Bankart lesion of shoulder a prospective randomised study. Arthroscopic 2004;20(5):456-462.

9. Ee GW, Mohamed S, Tan AH. Long term result of arthroscopic Bankart repair for traumatic anterior shoulder instability. *J Orthop Surg Res* 2011;6:28.
10. Sedeek SM, Tey IK, Tan AH. Arthroscopic Bankart's repair for traumatic anterior shoulder instability with the use of suture anchor. *Singapore Med J* 2008;49(9):676-681.
11. Scheibel M, Tsynman A, Magosch P, et al. Postoperative subscapularis insufficiency after primary and revision open shoulder stabilization. *Am J sports Med* 2006;34(10):1586-1593.
12. Bottani CR, Smith EL, Berkowitz MJ, et al. Arthroscopic versus open shoulder stabilization for recurrent shoulder anterior instability. *Am J sports med* 2006;34(11):1730-1737.
13. Wang C, Ghalambor N, Zarins B, et al. Arthroscopic versus open Bankart repair: analysis of patient subjective outcome and cost. *Arthroscopy* 2005;21(10):19-22.
14. O'Neil BD. Arthroscopic Bankart repair of anterior detachment of glenoid labrum. A prospective study. *Arthroscopy* 2002;18:755-63.
15. Potzl W, Witt KA, Hackenberg L, et al. Results of suture anchor repair of anteroinferior shoulder instability: a prospective clinical study of 85 shoulders. *J Shoulder Elbow Surg* 2003;12:322-326.
16. Richmond JC, Donaldson WR, Fu FH, et al. Modification of the Bankart reconstruction with a suture anchor. Report of a new technique. *Am J Sports Med* 1991;19(4):343-346.
17. Pagnani MJ, Dome DC. Surgical treatment of traumatic anterior shoulder instability in American football players. *J Bone Joint Surg Am* 2002;84(5):711-715.
18. Baker CL, Uribe JN, Whitman C. Arthroscopic evaluation of acute initial anterior shoulder dislocation. *Am J Sports Med* 1990;18(1):25-28.
19. Liu SH, Henry MH. Anterior shoulder instability. current review. *Clin Orthop* 1996;323:327-337.
20. Rowe CR, Zarins B. Recurrent transient subluxation of the shoulder. *J Bone Joint Surg* 1981;63(6):863-872.
21. Kirkley A, Griffin S, Richards C, et al. Prospective randomized clinical trial comparing the effectiveness of immediate arthroscopic stabilization versus immobilization and rehabilitation in first traumatic anterior dislocation of the shoulder. *Arthroscopy* 1999;15(5):507-514.
22. Linters TR, Franta AK, Wolf FM, et al. Arthroscopic compared with open repairs for recurrent anterior shoulder instability: a systematic review and meta-analysis of the literature. *J Bone Joint Surg Am* 2007;89(2):244-254.
23. Kim SH, Ha KI, Cho YB, et al. Arthroscopic anterior stabilization of the shoulder: two to six year followup. *J Bone Joint Surg Am* 2003;85A(8):1511-1518.
24. McIntyre LF, Caspari RB, Savoie FH. The arthroscopic treatment of multidirectional shoulder instability: two-year results of a multiple suture anchor. *Arthroscopy* 1997;13(4):418-425.
25. Savoie FH, Miller CD, Field LD. Arthroscopic reconstruction of traumatic anterior instability of the shoulder. The Caspari technique. *Arthroscopy* 1997;13:201-209.
26. Gartsman GM, Roddey TS, Hammerman SM. Arthroscopic treatment of anterior-inferior glenohumeral instability. Two- to five-year followup. *J Bone Joint Surg Am* 2000;82A(7):991-1003.
27. Mishra DK, Fanton GS. Two-years outcome of arthroscopic Bankart repair and electrothermal-assisted capsulorrhaphy for recurrent traumatic anterior shoulder instability. *Arthroscopy* 2001;17(8):844-849.
28. Karlsson J, Magnusson L, Ejerhed L, et al. Comparison of open and arthroscopic stabilization for recurrent shoulder dislocation in patients with a Bankart lesion. *Am J Sports Med* 2001;29(5):538-542.
29. Synder SJ, Banas MP, Belzer JP. Arthroscopic treatment of anterior shoulder instability using threaded suture anchors and nonabsorbable sutures. *Instr Course Lect* 1996;45:71-81.
30. Amit Mishra, Pulak Sharma, Deepak Chaudhary. Analysis of the functional results of arthroscopic Bankart repair in posttraumatic recurrent anterior dislocations of shoulder *Indian J Orthop* 2012;46(6):668-674.