

CT ENTEROCLYSIS / CT ENTEROGRAPHY FOR DIFFERENTIATING INTESTINAL TUBERCULOSIS FROM CROHN'S DISEASE

Alpana¹, Rajanikant R. Yadav², Geeta Yadav³, Praveer Ra⁴, Kunti Yadav⁵, Archana Gupta⁶

¹Senior Resident, Department of Radiodiagnosis, Sanjay Gandhi Post Graduate Institute of Medical Sciences, Lucknow, Uttar Pradesh.

²Associate Professor, Department of Radiodiagnosis, Sanjay Gandhi Post Graduate Institute of Medical Sciences, Lucknow, Uttar Pradesh.

³Assistant Professor, Department of Pathology, King George's Medical University, Lucknow, Uttar Pradesh.

⁴Professor, Department of Gastroenterology, Sanjay Gandhi Post Graduate Institute of Medical Sciences, Lucknow, Uttar Pradesh.

⁵Senior Resident, Department of Radiodiagnosis, Sanjay Gandhi Post Graduate Institute of Medical Sciences, Lucknow, Uttar Pradesh.

⁶Professor, Department of Radiodiagnosis, Sanjay Gandhi Post Graduate Institute of Medical Sciences, Lucknow, Uttar Pradesh.

ABSTRACT

BACKGROUND

Intestinal tuberculosis is highly prevalent in India and the incidence of Crohn's disease is also increasing. Both these diseases have similar clinical presentation, imaging and pathological features. This makes differentiation between these two entities challenging. Differentiating these entities is important because there is a considerable difference in their management. CT enteroclysis (CT-EC) and CT enterography (CT-EG) are newer imaging techniques which provide good luminal distention of the bowel and allow better detection of bowel wall lesions, their pattern of enhancement and also detect extra-intestinal findings in the abdomen. The aim of this study was to evaluate the role of CT-EC/CT-EG in the detection, characterization and differentiation of intestinal tuberculosis and Crohn's disease.

METHODS

One hundred and fifty patients with clinically suspected intestinal tuberculosis or Crohn's diseases were subjected to CT-EC/CT-EG. Findings on CT-EC/CT-EG were correlated with other investigations (radiological, endoscopic, histopathological, microbiological, body fluid examination) and improvement on empirical therapy.

RESULTS

Seventy-nine patients had bowel lesions based on findings on CT-EC/CT-EG and other investigations of which 47, 18 and 14 patients had final diagnoses of intestinal tuberculosis, Crohn's disease and other bowel lesions (ulcerative colitis, duodenal ulcers, strictures of undetermined aetiology, parasitic infections and appendicitis) respectively. The sensitivity of CT-EC/CT-EG for detecting bowel involvement in intestinal tuberculosis and Crohn's disease was 91.48% and 94.44% respectively. Contiguous involvement of terminal ileum, ileo-cecal junction and adjacent colon, homogenous enhancement of bowel wall thickening, and abdominal lymphadenopathy were significantly more common in intestinal tuberculosis while jejunal involvement, mural stratification pattern of enhancement, strictures, skip lesions, mesenteric fat stranding and increased mesenteric vascularity were significantly commoner in Crohn's disease. Associated calcified and necrotic abdominal lymphadenopathy, cocoon formation and vertebral involvement were specific to intestinal tuberculosis.

CONCLUSIONS

CT-EC/CT-EG are sensitive investigations for detection of bowel lesions in intestinal tuberculosis and Crohn's disease. No site of bowel involvement or pattern of enhancement of bowel wall thickening is specific to intestinal tuberculosis or Crohn's disease. However, associated extra-intestinal findings on CT-EC/CT-EG and findings on other investigations can help differentiate between intestinal tuberculosis and Crohn's disease.

KEYWORDS

CT Enteroclysis, CT Enterography, Intestinal Tuberculosis, Crohn's Disease.

HOW TO CITE THIS ARTICLE: Alpana, Yadav RR, Yadav G, et al. CT enteroclysis / CT enterography for differentiating intestinal tuberculosis from Crohn's disease. J. Evid. Based Med. Healthc. 2019; 6(27), 1837-1843. DOI: 10.18410/jebmh/2019/375

BACKGROUND

In developing countries like India, intestinal tuberculosis is highly prevalent, and the incidence of Crohn's disease is also increasing.¹ Both entities have similar symptomatology. Both are chronic granulomatous disorders and currently, majority

of diagnoses are made on endoscopic mucosal biopsy specimens which may not show the characteristic caseation and acid-fast bacilli in intestinal tuberculosis or the fissuring ulcers and transmural inflammation in Crohn's disease.²

Financial or Other, Competing Interest: None.
Submission 18-06-2019, Peer Review 20-06-2019,
Acceptance 28-06-2019, Published 08-07-2019.
Corresponding Author:
 Dr. Rajanikant R. Yadav,
 Type 4/74, SGPGIMS Campus,
 Raebareli Road, Lucknow-226014,
 Uttar Pradesh, India.
 E-mail: rajani24478@gmail.com
 DOI: 10.18410/jebmh/2019/375



Various imaging (plain x-rays, barium studies, ultrasonography, CT and Magnetic Resonance Imaging) and endoscopic modalities are available for detection and characterization of these bowel pathologies which along with histopathological and microbiological findings and response to empirical therapy complement each other in making a final diagnosis.^{2,3} CT is often the initial imaging investigation performed for the evaluation of suspected bowel pathology. However, conventional CT does not provide adequate distension of the bowel and the positive oral contrast only depicts bowel wall thickening, stricture, and dilatation, but not mucosal abnormality. Newer CT techniques such as CT-EC and CT-EG which provide bowel distension are now the preferred initial imaging techniques for evaluation of the bowel.⁴ CT-EC is performed after inserting a nasojejunal (NJ) tube and actively injecting neutral contrast agents (water, polyethylene glycol (PEG) or Volumen) to provide rapid distension of the small bowel whereas CT-EG is performed by passively distending the bowel loops by orally ingesting osmotic neutral contrast agents such as PEG, mannitol or sorbitol.⁵

Aims and Objectives

To evaluate the role of CT-EC and CT-EG in the detection, characterization and differentiation of intestinal tuberculosis from Crohn's disease.

METHODS

A prospective study involving 150 patients was carried out from January 2014 to October 2015. The study was approved by the Institutional Ethics Committee, and written informed consent was obtained from all the patients participating in the study.

Inclusion Criteria

1. Patients with strong clinical suspicion of intestinal tuberculosis or Crohn's disease.
2. Patients with both clinical suspicion and findings on other radiological investigations (chest x-ray, chest CT, barium meal follow through, barium enteroclysis) suggestive of tuberculosis or Crohn's disease.
3. Patients with proven tuberculosis or Crohn's disease on cytological, histopathological or microbiological examination of endoscopic, ultrasound or CT guided ileo-colonic or lymph node FNAC/ biopsy specimens.

Exclusion Criteria

Pregnant patients, patients with renal insufficiency or documented adverse reaction to iodinated contrast material

and patients with a final diagnosis of neoplastic bowel conditions were excluded from the study.

Consenting patients satisfying the inclusion criteria were subjected to CT-EC or CT-EG. All patients were advised not to take anything per oral at least 6 hours before the examination except necessary medications with small sips of water.

CT Enteroclysis (CT-EC)

After anaesthetizing the nasal cavity with 2% lignocaine hydrochloride gel (Lox-2% Jelly, Neon Laboratories, Ltd., Mumbai, India), a 12-16F, 150 cm long NJ tube (Devon Innovations Pvt. Ltd., Bengaluru, India) was inserted under fluoroscopic guidance. The tip of the NJ tube was positioned in the jejunum beyond the duodeno-jejunal flexure. The patient was brought to the CT room and made to lie on the CT examination couch. 1.5-2 litres of normal saline was infused through the NJ tube via an infusion line connected to the NJ tube at one end and to a normal saline container fixed to an intravenous infusion stand at the other end. The rate of infusion was adjusted to approximately 100-150 ml /minute.

CT Enterography (CT-EG)

Patients who refused the NJ intubation or patients in whom intubation failed underwent CT-EG. Patients were asked to drink 2 to 2.5 litres of iso-osmotic PEG solution in equal aliquots of 100 ml starting 45 minutes before the CT examination.

CT Examination

After the infusion of normal saline via NJ tube or after oral ingestion of PEG solution all patients underwent CT examination on a multi detector CT scanner (Brilliance 64, Philips Healthcare, Netherlands). 20 mg of hyoscine butyl bromide (Buscopan, Boehringer Ingelheim Pvt. Ltd., Mumbai, India) was administered intravenously (i.v.) immediately prior to scanning to decrease small bowel peristalsis and facilitate bowel distension. Unenhanced CT examination was performed from the level of diaphragm to pubic symphysis during a single breath hold to evaluate the adequacy of distension of the small bowel loops using the following parameters: Detector configuration 64 x 0.6, section thickness 3 mm, section increment 1.5 mm, KVP 120 KV, mAs 200 with reconstruction up to 1 mm. If bowel distension was inadequate, patients were asked to ingest more PEG solution (250 ml) or further infusion of normal saline (250 ml) via the NJ tube was done. Then, 1.5 ml/kg of non-ionic iodinated contrast material (Iohexol 350 mg /ml- Omnipaque; GE Healthcare, Waukesha, WI, USA) was injected via an 18-20 gauge I.V. cannula inserted into an arm vein at a rate of 4 ml/s and contrast enhanced CT was performed at 30-50 seconds after beginning of administration of I.V. contrast using the same parameters as used for unenhanced CT.

CT Evaluation

Evaluation of CT images was done in multiple planes. Abnormal small bowel loops were defined by wall thickness ≥ 3.0 mm. The following characteristics of abnormal small bowel loops were evaluated: Pattern of enhancement, length of involvement, location of lesion along the course of small bowel- jejunum, ileum, ileocecal junction and adjacent large bowel, Associated dilatation of proximal bowel (jejunum >25 mm, ileum >30 mm).⁶ Other findings including associated abnormalities in the mesentery and blood vessels, ancillary findings in the rest of the abdomen / visualized chest were also recorded.

Findings on Other Investigations and Response to Empirical Therapy

Findings on CT-EC/CT-EG were correlated with findings on other investigations and response to empirical therapy to help reach a final diagnosis of intestinal tuberculosis or Crohn's disease. These investigations included:

1. Upper Gastro intestinal endoscopy (UGIE) or ileo-colonoscopy showing features suggestive of intestinal tuberculosis or Crohn's disease.
2. Chest X-ray / Chest CT findings suggestive of associated pulmonary tuberculosis.
3. Ultrasound/CT guided or endoscopic FNAC/ biopsy specimens showing histological features suggestive of Crohn's disease or caseating granulomas and/or acid fast bacilli on smears or histological sections suggestive of tuberculosis.
4. Culture or RT-PCR of sputum or guided FNAC/ biopsy samples from diseased tissue or lymph nodes suggestive of tuberculosis.
5. Increased adenosine deaminase levels (>36 units /litre) in ascitic fluid suggestive of tuberculosis.
6. In cases where a definite diagnosis of intestinal tuberculosis or Crohn's disease was uncertain, empirical therapy (anti-tubercular therapy (ATT) for intestinal tuberculosis, anti-inflammatory (mesalamine) / immunosuppressive (azathioprine) therapy for Crohn's disease) was administered and a favourable response to empirical therapy was recorded to help reach a final diagnosis.

Statistical analysis was done using statistical package for the social sciences version 23 (IBM, Chicago, USA). A p value of <0.05 was considered as statistically significant.

RESULTS

The demographic parameters and clinical presentation of patients of intestinal tuberculosis and Crohn's disease are summarized in Table 1. The CT-EC/CT-EG findings in patients of intestinal tuberculosis and Crohn's disease are summarized in Table 2.

Sl. No.	Parameter	Intestinal Tuberculosis (N=47)	Crohn's Disease (N=18)	P Value
1.	Demographics			
a.	Mean age (age range) in years	34.87 \pm 13.88 (14-65)	44.22 \pm 16.72 (21-89)	0.025
b.	Gender (M:F ratio)	1.76: 1	2.4: 1	0.86
2.	Symptoms			
a.	Abdominal pain	32 (74.5%)	16 (88.88%)	0.20
b.	Abdominal distension	26 (55.3%)	17 (94.44%)	0.003
c.	Fever	8 (17.02%)	6 (33.33%)	0.15
d.	Loss of weight	9 (19.1%)	6 (33.33%)	0.23
e.	Loss of appetite	7 (14.9%)	1 (5.55%)	0.303
f.	Vomiting	2 (4.2%)	6 (33.33%)	0.001
g.	Loose stools	4 (8.5%)	8 (44.44%)	0.001
h.	Melena/fresh bleed Per rectum	1 (2.1%)	2 (10.5%)	0.149

Table 1. Demographic Parameters and Clinical Presentation of Patients of Intestinal Tuberculosis and Crohn's Disease

Sl. No.	Parameter	Intestinal Tuberculosis (N=47)	Crohn's Disease (N=18)	P Value
1.	Site of Involvement in the Bowel			
a.	Jejunum	4/47(8.5%)	5/18(27.77%)	0.044
b.	Ileum	21/47(44.64%)	11/18(61.11%)	0.218
c.	Terminal ileum, Ileocecal junction & adjacent colon	21/47(44.64%)	3/18(16.66%)	0.040
d.	Large bowel (non-contiguous with the ileocecal junction)	3/47 (6.38%)	2/18 (11.11%)	0.522
2.	Bowel Wall Thickening on CT-EC/CT-EG			
a.	Incidence of bowel wall thickening	43/47(91.48%)	17/18(94.44%)	0.689
b.	Pattern of enhancement of bowel wall thickening	-	-	-
i	Homogeneous enhancement	32/43(74.41%)	7/17 (41.17%)	0.015
ii	Mucosal hyper-enhancement	7/43 (16.27%)	2/17 (11.76%)	0.659
iii	Mucosal and serosal enhancement with submucosal oedema (mural stratification)	4/43 (9.3%)	8/17 (47.05%)	0.001
c.	Strictures	23/43(53.48%)	15/17(88.23%)	0.011
d.	Proximal bowel dilatation	16/43(37.20%)	10/17(58.82%)	0.128
e.	Skip lesions	6/43 (13.95%)	10/17(58.82%)	0.000
3.	Extra-Intestinal Involvement on CT-EC/CT-EG			
a.	Lymphadenopathy	24/47(51.06%)	2/18 (11.11%)	0.003
b.	Lymph node calcification	4/47 (8.51%)	0/18 (0%)	0.200
c.	Lymph node necrosis	3/47 (6.38%)	0/18 (0%)	0.271
d.	Increased mesenteric vascularity (comb sign) ⁷	1/47 (2.12%)	8/18 (44.4%)	0.000
e.	Mesenteric fat stranding	1/47 (2.12%)	4/18 (22.2%)	0.006
f.	Ascites	2/47 (4.25%)	1/18 (5.55%)	0.825
g.	Cocoon formation	3/47 (6.38%)	0/18 (0%)	0.271
h.	Vertebral involvement	2/47 (4.25%)	0/18 (0%)	0.373

Table 2. CT-EC/CT-EG Findings in Patients of Intestinal Tuberculosis and Crohn's Disease

Out of 150 patients included in this study, 71 patients (47%) did not have any findings on radiological or other investigations. Forty-seven patients had a final diagnosis of intestinal tuberculosis and 18 had a final diagnosis of Crohn's disease. Fourteen patients had other final diagnoses including ulcerative colitis (n=1), duodenal ulcers (n=5), strictures of unknown aetiology (n=4), parasitic infections- amoebiasis, strongyloidiasis, ascariasis (n=3) and appendicitis (n=1).

In this study, intestinal tuberculosis had a younger mean age (34.87 years) at presentation when compared to Crohn's disease (44.22 years). Symptoms of abdominal distention, vomiting and diarrhoea were found to be commoner in Crohn's disease when compared to intestinal tuberculosis. However, no symptom was found to be specific for either intestinal tuberculosis or Crohn's disease.

Bowel wall thickening was noted in 43/47 (91.48%) patients of intestinal tuberculosis and 17/18 (94.44%) patients of Crohn's disease on CT-EC/CT-EG. Four cases of intestinal tuberculosis that did not have bowel wall thickening on CT-EC/CT-EG showed ileo-colonic ulcers on ileo-colonoscopy. Two of these patients had increased levels of adenosine deaminase in ascitic fluid and 2 patients showed favourable response to empirical therapy with ATT. One patient of Crohn's disease who had no finding on CT-EC/CT-EG, showed aphthous ulcers in the terminal ileum and IC junction and was started on empirical therapy for Crohn's disease and showed a favourable response.

Jejunal involvement was found to be significantly more common ($p=0.044$) in cases of Crohn's disease when compared to patients with intestinal tuberculosis. There was no significant difference in ileal involvement between intestinal tuberculosis and Crohn's Disease ($p=0.218$). Contiguous involvement of terminal ileum, ileocecal junction and adjacent colon was significantly commoner in intestinal tuberculosis as compared to Crohn's disease ($p=0.040$).

Homogenous enhancement pattern of bowel wall thickening was significantly commoner ($p=0.015$) in cases of intestinal tuberculosis (74.41% cases) when compared to Crohn's disease (41.17% cases). Mucosal and serosal enhancement with submucosal oedema (mural stratification) pattern of bowel wall thickening was found to be significantly commoner ($p=0.001$) in cases of Crohn's disease (47.05% cases) when compared to intestinal tuberculosis (9.3% cases). Mucosal hyper enhancement pattern of bowel wall thickening showed no significant difference ($p=0.659$) between intestinal tuberculosis (16.27% cases) and Crohn's disease (11.76% cases). Six patients with final diagnosis other than intestinal tuberculosis or Crohn's disease also showed bowel wall thickening on CT-EC / CT-EG. Of these, homogenous enhancement pattern was observed in 4 cases of strictures of undetermined aetiology and 1 case of appendicitis. Mucosal hyper enhancement pattern was seen in 1 patient with ileocecal involvement due to *E. Histolytica*.

Strictures ($p=0.011$) and skip lesions (multiple non-contiguous sites of involvement) ($p=0.000$) were significantly more common in Crohn's disease when compared to intestinal tuberculosis.

Pattern of Extra-Intestinal Involvement

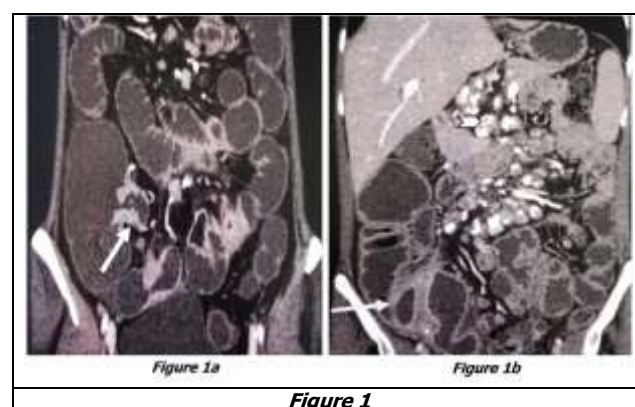
Intestinal tuberculosis cases showed enlargement of mesenteric and retroperitoneal lymph nodes. Crohn's disease patients showed enlargement of mainly mesenteric lymph nodes. Abdominal lymphadenopathy was found to be significantly commoner ($p=0.003$) in intestinal tuberculosis (51.06% cases) when compared to Crohn's disease (11.1%

cases). Of intestinal tuberculosis patients with abdominal lymphadenopathy, 4 cases had calcified lymph nodes and 3 had necrotic lymph nodes. Necrotic and calcified lymphadenopathy was not observed in cases of Crohn's disease. Loco-regional ileo-colonic and mesenteric non necrotic lymphadenopathy was seen in 1 case of appendicitis in this study.

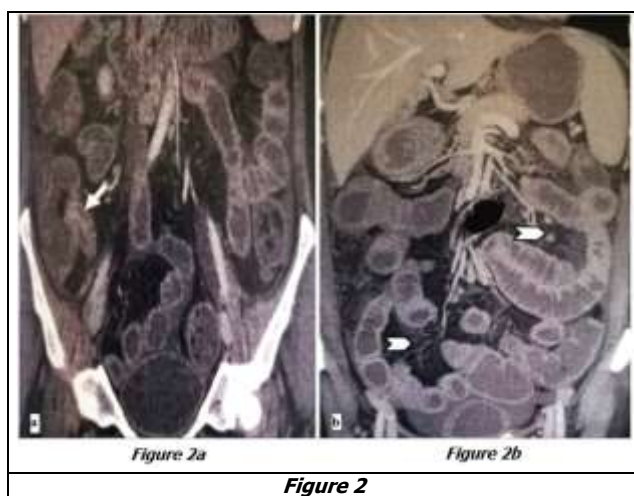
Mesenteric fat stranding was significantly more common ($p=0.006$) in Crohn's disease (22.2% cases) when compared to intestinal tuberculosis (2.12% cases). Mesenteric fat stranding was also observed in 1 patient with appendicitis in this study. Increased mesenteric vascularity (Comb sign)⁷ was significantly more common ($p=0.000$) in Crohn's disease (44.4% cases) when compared with intestinal tuberculosis (2.12% cases). Ascites was seen in 2 cases of intestinal tuberculosis and 1 case of Crohn's disease. Abdominal cocoon formation (encapsulation of the small bowel by a fibrous membrane),⁸ was observed in 3 cases with intestinal tuberculosis. In 2 other cases of intestinal tuberculosis there was involvement of the intervertebral disc with paravertebral collections. Enteroliths were seen in 2 cases of intestinal tuberculosis and an appendicolith was seen in 1 case of appendicitis. A loculated mesenteric abscess was seen in one case of Crohn's disease and 1 case with *E. histolytica* infestation of ileo-colic region showed a right lobe liver abscess.

CT-EC/CT-EG in The Detection of Intestinal Tuberculosis and Crohn's Disease

Among 47 and 18 patients with a final diagnosis of intestinal tuberculosis and Crohn's disease respectively, all of whom had undergone CT-EC/CT-EG, bowel lesions were detected in 43 patients of intestinal tuberculosis and 17 patients of Crohn's disease on CT-EC/CT-EG. The sensitivity of CT-EC/CT-EG for detecting bowel involvement in cases of intestinal tuberculosis and Crohn's disease was 91.48% and 94.44% respectively. Amongst 43 patients with a final diagnosis of intestinal tuberculosis and 15 patients with a final diagnosis of Crohn's disease who had under gone both CT-EC/CT-EG and UGIE/ileo-colonoscopy, the sensitivity of CT-EC/CT-EG for the detection of intestinal tuberculosis and Crohn's disease was 90.7% and 86.7% respectively. The sensitivity of UGIE/ileo-colonoscopy for detection of intestinal tuberculosis and Crohn's disease was 83.7% and 66.7% respectively.



- (a) Coronal reformatted CT enterography image in a case of intestinal tuberculosis showing homogenously enhancing mural thickening of terminal ileum and ileocecal junction (arrow). An adjacent mesenteric lymph node showing central necrosis is also seen.
- (b) Coronal reformatted CT enterography image in another case of intestinal tuberculosis showing homogenously enhancing mural thickening of terminal ileum and ileocecal junction (arrow). Multiple enlarged and calcified mesenteric lymph nodes are also seen (arrow head).



- (a) Coronal reformatted CT enterography image in a case of Crohn's disease showing stratified mural thickening of terminal ileum, ileocecal junction and cecum (arrow).
- (b) Coronal reformatted maximum intensity projection CT enterography image in the same patient showing increased mesenteric vascularity adjacent to involved jejunal and terminal ileal loops (arrow heads). Few homogenously enhancing non necrotic mesenteric lymph nodes are also seen.

DISCUSSION

Few studies have evaluated the role of CT-EC/CT-EG in the differentiation of intestinal tuberculosis from Crohn's Disease. CT-EC/CT-EG are appropriate diagnostic tests when intestinal tuberculosis or Crohn's disease is suspected because they can assess bowel changes, the mesentery, abdominal lymph nodes, and other abdominal organs.^{4,9} In this study we evaluated CT-EC/CT-EG findings in patients with a final diagnosis of intestinal tuberculosis or Crohn's disease based on the findings of other investigations (radiological, endoscopic, histopathological, microbiological and body fluid examination) or response to empirical therapy for intestinal tuberculosis or Crohn's disease.

In this study, symptoms of abdominal distention, vomiting and diarrhoea were found to be commoner in Crohn's disease when compared to intestinal tuberculosis. Zhao XS, et al (2014) found diarrhoea, weight loss, perianal disease, haematochezia to be significantly commoner in Crohn's disease and fever and night sweats to be commoner in intestinal tuberculosis.¹⁰ Kedia S, et al (2015) found anorexia, constipation and partial intestinal obstruction to be commoner in intestinal tuberculosis.¹¹ No symptom was found to be specific to either intestinal tuberculosis or Crohn's disease in our study as well as in other previous studies.^{10,11}

In this study, contiguous involvement of terminal ileum, ileo-cecal junction and adjacent colon, homogenous pattern of enhancement of bowel wall thickening and enlarged mesenteric and retroperitoneal lymph nodes were significantly more common in intestinal tuberculosis. Calcified lymph nodes (n=4), necrotic mesenteric and retroperitoneal lymphadenopathy (n=3), cocoon formation (n=3) and vertebral involvement (n=2) were specific to intestinal tuberculosis. Zhao XS, et al (2014) found right side colonic involvement to be significantly commoner in intestinal tuberculosis and found necrotic and calcified lymphadenopathy and peritoneal changes to be specific for intestinal tuberculosis.¹⁰ Calcified lymph nodes and necrotic lymphadenopathy were also observed to be specific for intestinal tuberculosis in other studies when differentiating intestinal tuberculosis from Crohn's disease.¹²⁻¹⁴ A comparison of incidence of associated extra-intestinal findings on CT-EC/CT-EG in the abdomen in intestinal tuberculosis and Crohn's disease as observed in different studies is listed in Table 3.

In this study, Jejunal involvement, mural stratification pattern of enhancement of bowel wall thickening, strictures, skip lesions, increased mesenteric vascularity (comb sign),⁷ mesenteric fat stranding (phlegmon), loculated abscess were significantly more common in Crohn's Disease. Besides these findings, ileal involvement, left colonic, rectal and perianal involvement have been observed to be commoner in Crohn's disease when compared to intestinal tuberculosis in other studies.^{10,12}

Involvement of a particular region of the bowel or pattern of enhancement of bowel wall thickening was not found to be specific for either intestinal tuberculosis or Crohn's disease in our study. Kalra N, et al (2014)⁶ found homogenous mural enhancement to be the commonest pattern in intestinal tuberculosis while Choi D, et al (2003)¹⁵ found mural stratification pattern of enhancement of bowel wall thickening to be the commonest pattern in Crohn's disease. Zhao XS, et al (2014) did not find any significant difference in patterns of bowel wall enhancement between intestinal tuberculosis and Crohn's disease.¹⁰

	This Study (2019)			Kedia S, et al (2015) ¹¹			Zhang T, et al (2015) ¹²			Mao R, et al (2014) ¹⁴			Zhao XS, et al (2014) ¹⁰			Park YH, et al (2013) ¹³		
	ITB*	CD#	p	ITB	CD	p	ITB	CD	p	ITB	CD	p	ITB	CD	p	ITB	CD	p
Lymphadenopathy	51.06%	11.11%	0.003	20%	1.9%	<0.01	-	-	-	-	-	-	-	-	-	27.3%	53.7%	-
Lymph node calcification	8.51%	0%	0.200	-	-	-	6.5%	0	0.018	28.9%	0%	-	6.4%	0%	0.015	9.1%	0%	0.169
Lymph node necrosis	6.38%	0%	0.271	-	-	-	35.5%	0%	<0.001	28.9%	0%	-	29.8%	0%	<0.001	9.1%	0%	0.169
Comb sign ⁷	2.12%	44.4%	0.000	20%	44.45%	0.01	32.3%	91.3%	<0.001	7.9%	80.6%	<0.001	29.8%	95%	<0.001	9.1%	74.1%	0.001
Mesenteric fat stranding	2.12%	22.2%	0.006	20%	13%	0.33	0%	14.1%	0.018	39.5%	52.2%	0.208	0%	29.1%	<0.001	-	-	-
Fibro-fatty proliferation	-	-	-	12%	18.5%	0.36	-	-	-	5.3%	37.3%	<0.001	19.1%	48.2%	<0.001	9.1%	46.3%	0.039
Ascites	4.25%	5.55%	0.825	-	-	-	29%	7.6%	0.002	-	-	-	29.8%	5%	<0.001	27.3%	20.4%	0.691
Cocoon formation	6.38%	0%	0.271	-	-	-	-	-	-	-	-	-	-	-	-	-	-	-
Vertebral involvement	4.25%	0%	0.373	-	-	-	-	-	-	-	-	-	-	-	-	-	-	-
Table 3. Comparison of Incidence of Associated Extra-Intestinal Findings in the Abdomen on CT-EC/CT-EG Between Intestinal Tuberculosis and Crohn's Disease																		
*Intestinal tuberculosis, #Crohn's disease.																		

In this study, the sensitivity of CT-EC/CT-EG for detecting bowel involvement in cases of intestinal tuberculosis and Crohn's disease was 91.48% and 94.44% respectively. Ray D, et al (2013) observed a sensitivity of 93.75% for CT-EC in diagnosing small bowel tuberculosis.¹⁶ Previous studies have demonstrated a sensitivity of more than 85% for CT-EC/CT-EG in detecting Crohn's disease.¹⁷ The sensitivity of UGIE/ileo-colonoscopy for detecting bowel involvement in cases of intestinal tuberculosis and Crohn's disease in our study was 83.72% and 64.28% respectively. CT-EC/CT-EG were found to be more sensitive than UGIE/ileo-colonoscopy for detecting bowel lesions in cases of intestinal tuberculosis and Crohn's disease in our study. This can be explained by the limitations of UGIE and ileo-colonoscopy which cannot evaluate the small bowel between the duodeno-jejunal flexure and terminal ileum while CT-EC/CT-EG allow evaluation of all regions of the bowel. Four out of 47 cases of intestinal tuberculosis and 1 out of 17 cases of Crohn's disease which could not be detected by CT-EC/CT-EG were detected on ileo-colonoscopy. This suggests that, use of both CT-EC/CT-EG and ileo-colonoscopy increases the sensitivity of detection of bowel lesions in intestinal tuberculosis and Crohn's disease.

CONCLUSIONS

CT-EC/CT-EG are sensitive investigations for the detection of the bowel lesions in intestinal tuberculosis and Crohn's disease and can be used as the initial investigation for the detection of bowel lesions when there is a clinical suspicion of intestinal tuberculosis or Crohn's disease. No site of involvement in the bowel or pattern of enhancement of bowel wall thickening is specific to either intestinal tuberculosis or Crohn's disease. However, associated extra-intestinal findings on CT-EC/CT-EG and findings on other investigations (radiological, endoscopic, histopathological, microbiological, body fluid examination) can help to differentiate between intestinal tuberculosis and Crohn's disease.

REFERENCES

- [1] Das K, Ghoshal UC, Dhali GK, et al. Crohn's disease in India: a multicenter study from a country where tuberculosis is endemic. Dig Dis Sci 2009;54(5):1099-1107.
- [2] Ye Z, Lin Y, Cao Q, et al. Granulomas as the most useful histopathological feature in distinguishing between Crohn's disease and intestinal tuberculosis in endoscopic biopsy specimens. Medicine (Baltimore) 2015;94(49):e2157.
- [3] Pulimood AB, Amarapurkar DN, Ghoshal U, et al. Differentiation of Crohn's disease from intestinal tuberculosis in India in 2010. World J Gastroenterol 2011;17(4):433-443.
- [4] Sharma R, Madhusudhan KS, Ahuja V. Intestinal tuberculosis versus Crohn's disease: clinical and radiological recommendations. Indian J Radiol Imaging 2016;26(2):161-172.
- [5] Ilangoan R, Burling D, George A, et al. CT enterography: review of technique and practical tips. Br J Radiol 2012;85(1015):876-886.
- [6] Kalra N, Agrawal P, Mittal V, et al. Spectrum of imaging findings on MDCT enterography in patients with small bowel tuberculosis. Clin Radiol 2014;69(3):315-322.
- [7] Meyers MA, McGuire PV. Spiral CT demonstration of hypervascularity in Crohn's disease: "vascular jejunitization of the ileum" or the "comb sign". Abdom Imaging 1995;20(4):327-332.
- [8] Rastogi R. Abdominal cocoon secondary to tuberculosis. Saudi J Gastroenterol 2008;14(3):139-141.
- [9] Elsayes KM, Al-Hawary MM, Jagdish J, et al. CT enterography: principles, trends, and interpretation of findings. Radiographics 2010;30(7):1955-1970.
- [10] Zhao XS, Wang ZT, Wu ZY, et al. Differentiation of Crohn's disease from intestinal tuberculosis by clinical and CT enterographic models. Inflamm Bowel Dis 2014;20(5):916-925.

- [11] Kedia S, Sharma R, Nagi B, et al. Computerized tomography-based predictive model for differentiation of Crohn's disease from intestinal tuberculosis. *Indian J Gastroenterol* 2015;34(2):135-143.
- [12] Zhang T, Fan R, Wang Z, et al. Differential diagnosis between Crohn's disease and intestinal tuberculosis using integrated parameters including clinical manifestations, T-SPOT, endoscopy and CT enterography. *Int J Clin Exp Med* 2015;8(10):17578-17589.
- [13] Park YH, Chung WS, Lim JS, et al. Diagnostic role of computed tomographic enterography differentiating Crohn's disease from intestinal tuberculosis. *J Comput Assist Tomogr* 2013;37(5):834-839.
- [14] Mao R, Liao WD, He Y, et al. Computed tomographic enterography adds value to colonoscopy in differentiating Crohn's disease from intestinal tuberculosis: a potential diagnostic algorithm. *Endoscopy* 2015;47(4):322-329.
- [15] Choi D, Jin LS, Ah CY, et al. Bowel wall thickening in patients with Crohn's disease: CT patterns and correlation with inflammatory activity. *Clin Radiol* 2003;58(1):68-74.
- [16] Ray D, Thukral BB, Gupta R, et al. Small bowel tuberculosis by multidetector CT enteroclysis. *Jpn J Radiol* 2013;31(7):471-479.
- [17] Santos CHM, Menezes JNS, Nunes TF, et al. CT enterography in the evaluation of Crohn's disease. *J Coloproctol* 2015;35(4):217-222.