

# CORRELATION OF INTRAOPERATIVE FROZEN SECTION DIAGNOSIS WITH HISTOPATHOLOGICAL SECTIONS IN DIAGNOSIS OF CENTRAL NERVOUS SYSTEM TUMOURS- A STUDY OF 30 CASES

Ankita Narendra Tamhane<sup>1</sup>, Samarth Akhilesh Shukla<sup>2</sup>, Sourya Acharya<sup>3</sup>, Kishor M. Hiwale<sup>3</sup>, Arvind S. Bhake<sup>4</sup>, Sandeep Iratwar<sup>5</sup>

<sup>1</sup>Assistant Professor, Department of Pathology, Jawaharlal Nehru Medical College, Sawangi (Meghe) Wardha.

<sup>2</sup>Professor, Department of Pathology, Jawaharlal Nehru Medical College, Sawangi (Meghe) Wardha.

<sup>3</sup>Professor, Department of Medicine, Jawaharlal Nehru Medical College, Sawangi (Meghe) Wardha.

<sup>4</sup>Professor, Department of Pathology, Jawaharlal Nehru Medical College, Sawangi (Meghe) Wardha.

<sup>5</sup>Professor and HOD, Department of Pathology, Jawaharlal Nehru Medical College, Sawangi (Meghe) Wardha.

<sup>6</sup>Professor and HOD, Department of Neurosurgery, Jawaharlal Nehru Medical College, Sawangi (Meghe) Wardha.

## ABSTRACT

### BACKGROUND

There are two main types of tumours- malignant or cancerous tumours and benign tumours. Cancerous tumours can be divided into primary tumours that start within the brain and secondary tumours that have spread from somewhere else known as brain metastasis tumours. Primary CNS tumours represent 2% of estimated new cancers occurring in adults. The incidence of all adult primary brain tumours in the United States is 11.8 per 1,00,000 persons per year. Frozen Section (FS) diagnosis is a useful diagnostic technique for diagnosis of tumours of central nervous system as it guides a surgeon with appropriate therapeutic decision-making on most occasions.

### MATERIALS AND METHODS

In this retrospective study, we reviewed the reports of all CNS lesions from July 2016 to August 2017 in the Department of Pathology Jawaharlal Nehru Medical College, Sawangi (M), Wardha. Specimens were received from the OT complex of Neurosurgery Department of Acharya Vinoba Bhave Rural Hospital, Sawangi (M), Wardha. A total of 30 cases were studied. The tissue was frozen in a cryostat (-25°C) and 6-7µ sections were prepared and stained with rapid Haematoxylin and Eosin (H and E). The slides were examined under a light microscope by one or more general pathologists. The same specimen along with some more resected specimen were formalin fixed, additional representative sections were taken for paraffin embedding and routine H and E staining.

### RESULTS

When frozen section diagnosis was correlated with histopathological diagnosis, it was found that amongst 30 cases, 21 frozen section diagnosis correlated with the standard histopathological diagnosis, which accounted for 70% diagnosis of the total cases. The sensitivity was calculated as 70%.

### CONCLUSION

The final diagnoses were based on permanent sections and IHC studies. On correlation, the 'p' value was found to be > than 0.005, which is significant. These findings are concordant with the findings of our study.

### KEYWORDS

MIB-1 Labelling Index, Oligodendroglioma.

**HOW TO CITE THIS ARTICLE:** Tamhane AN, Shukla SA, Acharya S, et al. Correlation of intraoperative frozen section diagnosis with histopathological sections in diagnosis of central nervous system tumours- A study of 30 cases. J. Evid. Based Med. Healthc. 2017; 4(89), 5307-5311. DOI: 10.18410/jebmh/2017/1060

### BACKGROUND

A brain tumour occurs when abnormal cells form within the brain. There are two main types of tumours- malignant or cancerous tumours and benign tumours. Cancerous tumours

*Financial or Other, Competing Interest: None.*

*Submission 30-10-2017, Peer Review 06-11-2017,*

*Acceptance 11-11-2017, Published 13-11-2017.*

*Corresponding Author:*

*Dr. Ankita Narendra Tamhane,*

*Assistant Professor, Department of Pathology,*  
*Jawaharlal Nehru Medical College, Sawangi, (Meghe), Wardha.*

*E-mail: ankitatamhane9988@gmail.com*

*DOI: 10.18410/jebmh/2017/1060*



can be divided into primary tumours that start within the brain and secondary tumours that have spread from somewhere else known as brain metastasis tumours.<sup>1</sup>

Primary CNS tumours represent 2% of estimated new cancers occurring in adults. The incidence of all adult primary brain tumours in the United States is 11.8 per 1,00,000 persons per year. They are more common among whites and men. Various diagnostic methods have been used for the diagnosis of tumours of central nervous system. Intraoperative diagnosis of tumours of central nervous system is done by squash cytology, imprint cytology and frozen section diagnosis.

Frozen Section (FS) diagnosis is a useful diagnostic technique for diagnosis of tumours of central nervous system as it guides a surgeon with appropriate therapeutic decision making on most occasions.<sup>2,3</sup> In patients with Central Nervous System (CNS) lesions, rapid intraoperative diagnosis helps the surgeon to determine the best procedure and the endpoint of the operation studies have confirmed the accuracy of FS diagnosis for assessment of the CNS lesions with acceptable sensitivity retrospectively study the reliability of FS diagnosis for CNS lesions in three hospitals over a period of one year.<sup>4,5</sup>

### Aims and Objectives

In this retrospective study, we reviewed the reports of all CNS lesions from July 2016 to August 2017 in the Department of Pathology, Jawaharlal Nehru Medical College, Sawangi (M), Wardha. Specimens were received from the OT Complex of Neurosurgery Department of Acharya Vinoba Bhave Rural Hospital, Sawangi (M), Wardha, a total of 30 cases were studied.

### MATERIALS AND METHODS

During intraoperative consultation, fresh specimens were examined grossly for size and consistency. Based on sample size, representative sections were taken by an attending pathologist. The tissue was frozen in a cryostat (-25°C) and 6-7µ sections were prepared and stained with rapid Haematoxylin and Eosin (H and E). The slides were examined under a light microscope by one or more general pathologists. The same specimen along with some more resected specimen were formalin fixed, additional representative sections were taken for paraffin embedding and routine H and E staining. The definitive diagnosis was made after a thorough microscopic examination of all slides. Histological diagnosis was made according to the criteria set

forth in pathology textbooks for diagnosis of CNS lesions. For histological typing of tumours, WHO recommendations were followed.<sup>6,7</sup>

The reports of frozen and permanent sections were evaluated according to the status of benignancy, malignancy and histological type of the lesions. The results from the permanent sections were used as a gold standard. A definitive diagnosis was deferred to paraffin section analysis when the sample was too small for proper evaluation.

The overall sensitivity was calculated. FS were determined according to the type of the lesions and the accuracy of histological tumour types.

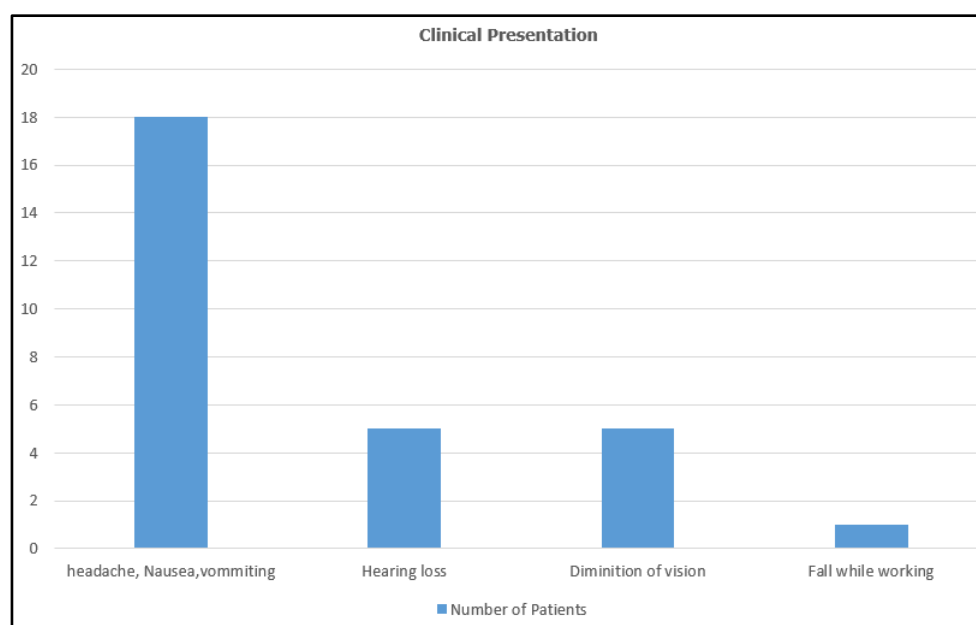
All statistical analyses were performed. To describe data, we used percentage of cases diagnosed on histopathology. To evaluate the agreement of the methods, we utilised sensitivity.

In this study, no ethical issues were involved as only pathology reports were reviewed retrospectively and all patients were anonymous. The articles used as references are valid and the information taken are reported unchanged.

### OBSERVATIONS AND RESULTS

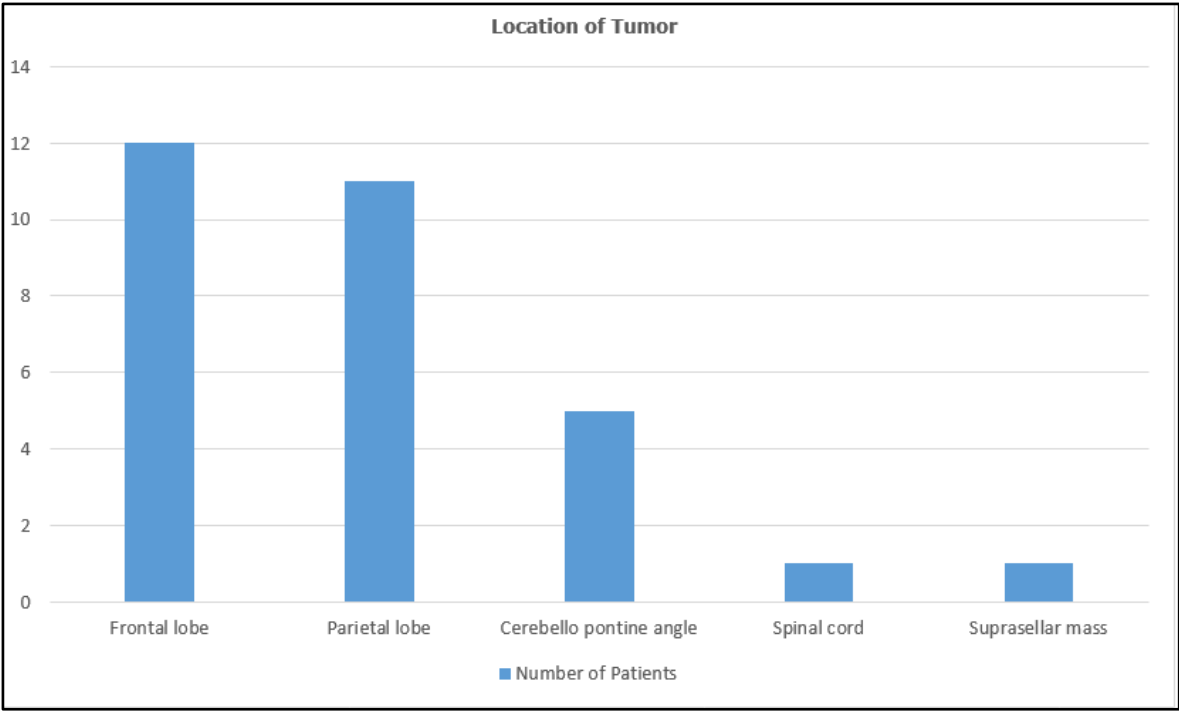
During the study period, 30 cases of central nervous system tumours were studied. The specimens were obtained from the OT Complex of the Neurosurgery Department, Acharya Vinoba Bhave Rural Hospital and were processed in the frozen section room AVBRH. Permanent histopathological sections were processed at the Department of Pathology, JNMC, Wardha. The age group of patients ranged from 12-76 years. 18 (60%) were males and 12 (40%) were females.

The majority of tumours, i.e. 18 cases presented with headache, nausea and vomiting, 5 cases of patients presented with hearing loss, 5 cases of patients presented with diminution of vision, 1 patient presented with back pain and 1 had a fall while working.



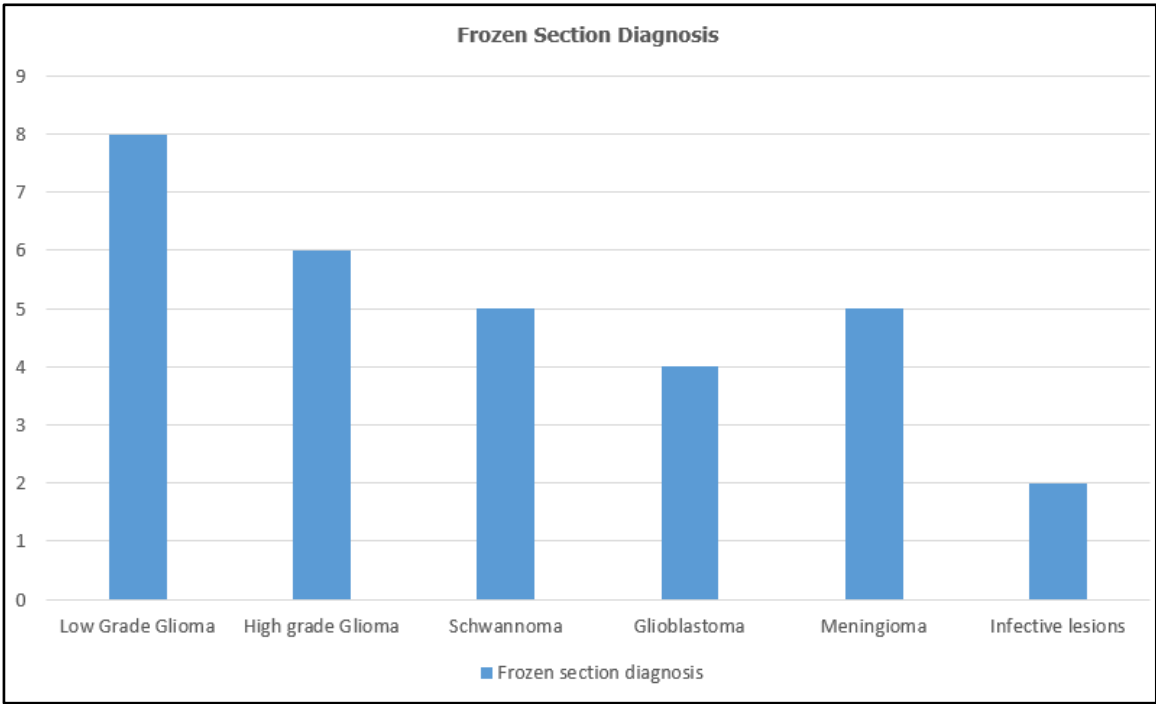
**Graph 1. Clinical Presentation**

12 cases were located in frontal lobe, 11 cases in the parietal lobe, 5 cases were located in the cerebello-pontine angle, 1 case was located at D1 and D2 of spinal cord and 1 was located in the suprasellar area.



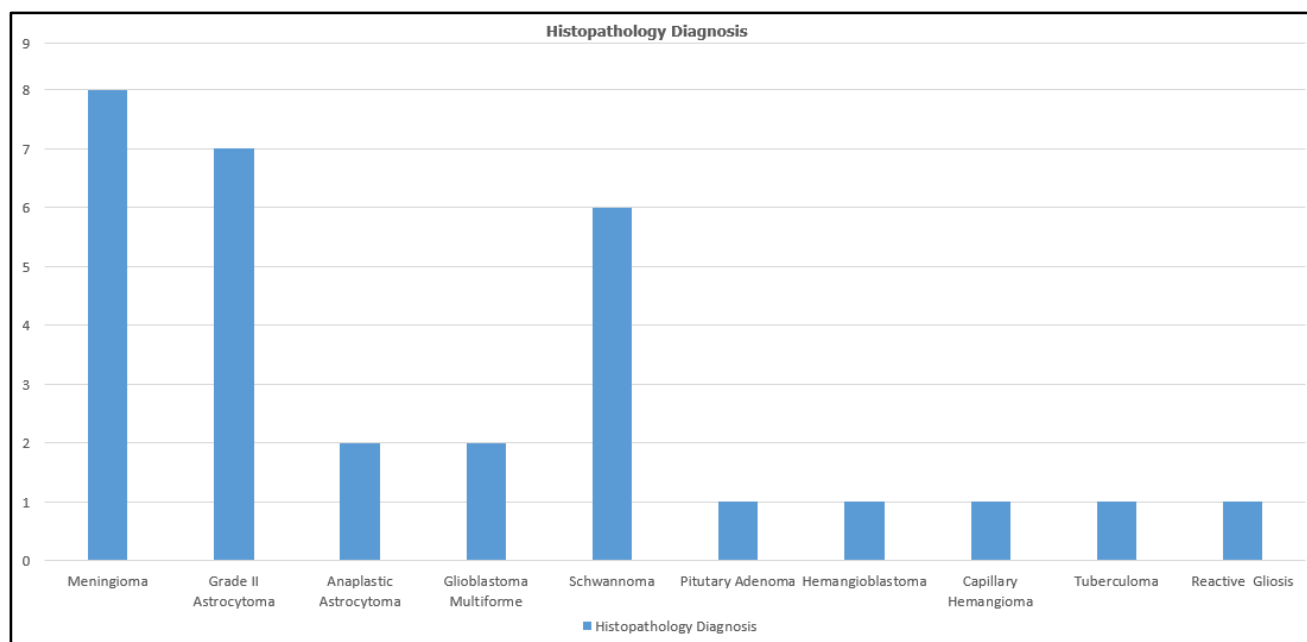
Graph 2. Location of Tumour

Frozen section diagnosis was carried out on the above cases, 8 cases were diagnosed as low-grade glioma, 6 cases were diagnosed with high-grade glioma, 5 were diagnosed as schwannoma, 2 were diagnosed as infective lesion and 5 cases were of meningioma and 4 cases of GBM.



Graph 3. Frozen Section Diagnosis

On histopathology, 8 cases were diagnosed as meningioma, 7 were grade II astrocytoma, 2 were anaplastic astrocytomas, 2 were diagnosed as glioblastoma multiforme, 6 were diagnosed as schwannoma, 1 was diagnosed as pituitary adenoma, 1 spinal tumour was diagnosed as capillary haemangioma, 1 case was diagnosed as haemangioblastoma, 1 case was diagnosed with tuberculoma and 1 case was diagnosed as reactive gliosis.



**Graph 4. Histopathology Diagnosis**

When frozen section diagnosis was correlated with histopathological diagnosis, it was found that amongst 30 cases, 21 frozen section diagnosis correlated with the standard histopathological diagnosis, which accounted for 70% diagnosis of the total cases. In rest of the cases, 2 cases of high-grade glioma diagnosed on frozen was diagnosed as glioblastoma multiforme on histopathology. One case of low-grade glioma on frozen was diagnosed as pituitary adenoma on histopathology. One was diagnosed as infective lesion on frozen section, which turned out to be capillary haemangioma. One was diagnosed as normal brain tissue on frozen section diagnosis, which was diagnosed as reactive gliosis on histopathology. One case of grade III astrocytoma on histopathology was diagnosed as low-grade glioma on frozen section diagnosis. Three cases, which were given as high-grade glioma on frozen section diagnosis was diagnosed as GBM on histopathology. The sensitivity was calculated as 70%.

## DISCUSSION

The present study is based on study of tumours of central nervous system in a tertiary healthcare centre. The present study emphasises on the utility of frozen section diagnosis for tumours of central nervous system in comparison to histopathological diagnosis. In the present study, 21 cases of tumours of central nervous system diagnosed on frozen section correlated with the final histopathology diagnosis.

In a study conducted by Thomas P Plesac et al at the Department of Anatomic Pathology, Cleveland Clinic Foundation, Cleveland, Ohio, authors studied 2156 cases of which in 57, i.e. 2.7% discrepancy in diagnosis was found. Twelve (21.1%) of 57 discrepancies involved errors in classification of spindle cell lesions, most commonly confusing schwannomas or meningiomas with other lesions. Twelve (21.1%) of 57 cases involved errors in differentiating oligodendrogliomas from astrocytomas. Nine (15.8%) of 57 discrepancies involved errors in the diagnosis of CNS

lymphoma. Eight (14.0%) of 57 cases involved errors in differentiating reactive from neoplastic processes, most frequently gliosis versus glioma. Four (7.0%) of 57 discrepancies involved errors in the over grading of tumours. The remaining 12 (21.1%) of 57 cases included an assortment of other discrepancies. Overall, it was concluded that frozen section of CNS neoplastic lesions is a good way for diagnosis of these lesions because of the high accuracy of frozen section diagnosis. These findings correlated with the findings of our study.<sup>4</sup>

In a study conducted by Radiya Al Ajmi et al at Department of Histopathology, Sultan Qaboos University Hospital, Muscat, Oman; authors studied 261 cases for the time period of 5 years. The most common diagnosis was glioblastoma (grade IV) and meningioma (grade I-II) forming 45.6% of cases. Fifty-three cases were subjected to intraobserver agreement of histological diagnosis. There was nearly perfect intraobserver agreement on histopathology (ICC = 0.9). Out of 261 cases, 224 cases showed a strong agreement between the FS diagnosis and final histological diagnosis (ICC = 0.747). A discrepancy between the FS and final diagnosis were found in eight cases. The disagreement did not relate to any specific tumour type. However, in three cases, the discrepancy was in the grading of the glioma. In 29 cases, a definite opinion could not be given on FS as the samples examined were nonrepresentative. The above findings simulated the findings of our study where we found a significant correlation in frozen section diagnosis and histopathological diagnosis.<sup>8</sup>

In a study by Yuji Uematsu et al at the School of Health and Nursing Science, Wakayama Medical University, Japan, the authors studied 180 cases of intracranial lesions excluding pituitary lesions. The correlation between the intraoperative diagnosis and the final diagnosis overall was seen in 172 of 180 cases proving a high diagnostic sensitivity of 95.6%. No correlation was seen in 8 cases (4.4%). The diagnostic inaccuracy was seen in the grading of gliomas and

the diagnosis of undifferentiated malignant tumours such as undifferentiated metastatic carcinomas, Primitive Neuroectodermal Tumours (PNETs) and sarcomas. It was also recognised in rare types of histology such as gliomatosis and xanthomatous lesions. These results suggested that the intraoperative rapid diagnosis was quite useful, but that we should also maintain a cautious attitude. These findings correlated with findings of present study.<sup>9</sup>

In a study by Bita Geramizadeh et al conducted at Department of Pathology, Transplant Research Centre, Shiraz University of Medical Sciences, Shiraz, Iran, they conducted a correlation between intraoperative diagnosis and histopathology for all the tumours of the body emphasising on the fact that maximum discrepancy was found in tumours of central nervous system. They studied a total of 759 cases of which only 25 showed discrepancy. 505 cases were from the Central Nervous System (CNS); of these, 14 showed discordant diagnoses between frozen and permanent sections (2.8%). These findings are similar to that of the findings of our study.<sup>10</sup>

In a study by Malieh Khodami et al, Paediatric Pathology Research Centre, Shahid Beheshti University of Medical Sciences (SBUMS), Tehran, Iran, authors correlated the findings of frozen section diagnosis with histopathological diagnosis in 273 cases. They found a significant concordance between it comprising concordance in 166 of the cases. The accuracy rate was 99.5%, sensitivity was 91.4%, specificity was 99.7% and positive and negative predictive values were 88.4% and 99.8%, respectively.<sup>11</sup>

In a study by Al Haidari Sharifabadi et al, Pathology and Laboratory Medicine Department, Imam Khomeini Hospital Complex, Tehran University of Medical Sciences, Tehran, Iran, a total of 157 patients with CNS lesions underwent open surgical biopsy or excision in our centre during a period of 2 years (2012-2013). All specimens were studied cytologically; of these specimens, 146 cases were also examined by frozen section. Cytology and frozen section slides were studied separately by two general pathologists who were blind to final diagnoses. The final diagnoses were based on permanent sections and IHC studies. On correlation, the 'p' value was found to be > than 0.005, which is significant. These findings are concordant with the findings of our study.<sup>12</sup>

## CONCLUSION

Frozen sections are suitably apt for intraoperative diagnosis of tumours of central nervous system and helps in differentiating benign and malignant lesions effectively. Only

limitation of frozen section diagnosis is in grading and differentiation of tumours of central nervous system.

## REFERENCES

- [1] Burger PC, Scheitauer BW, Vogel FS. Surgical pathology of the nervous system and its coverings. 3<sup>rd</sup> edn. New York: Churchill Livingstone 1991.
- [2] Taxy JB, Anthony G. Biopsy interpretation: the frozen section. 1st edn. China: Lippincott Williams & Wilkins 2010:301-303.
- [3] Somerset HL, Kleinschmidt-DeMasters BK. Approach to the intraoperative consultation for neurosurgical specimens. *Adv Anat Pathol* 2011;18(6):446-449.
- [4] Regragui A, Riffi AA, Maher M, et al. Accuracy of intraoperative diagnosis in central nervous system tumours: report of 1315 cases. *Neurochirurgie* 2003;49(2-3 Pt 1):67-72.
- [5] Plesec TP, Prayson RA. Frozen section discrepancy in the evaluation of central nervous system tumours. *Arch Pathol Lab Med* 2007;131(10):1532-1540.
- [6] Burger PC, Scheithauer BW. Tumours of the central nervous system. In: AFIP Atlas of Tumour Pathology Series 4. Washington DC: American Registry of Pathology 2007.
- [7] Louis DN, Ohgaki H, Wiestler OD, et al. The 2007 WHO classification of tumours of the central nervous system. *Acta Neuropathol* 2007;114(2):97-109.
- [8] Al-Ajmi R, Al-Kindi H, George M, et al. Correlation of intraoperative frozen section report and histopathological diagnosis of central nervous system tumours - A six-year retrospective study. *Oman Med J* 2016;31(6):414-420.
- [9] Uematsu Y, Owai Y, Okita R. The usefulness and problem of intraoperative rapid diagnosis in surgical neuropathology. *Brain Tumour Pathology* 2007;24(2):47-52.
- [10] Geramizadeh B, Larijini TR, Owji SM, et al. Accuracy of intraoperative frozen section consultation in south of Iran during four years. *Indian J Pathol Microbiol* 2010;53(3):414-417.
- [11] Khoddami M, Akbarzadeh A, Mordai A, et al. Diagnostic accuracy of frozen section of central nervous system lesions: a 10-year study. *Iran J Child Neurol* 2015;9(1):25-30.
- [12] Sharifabadi AH, Haeri H, Zeinalizadeh M, et al. Intra operative consultation of central nervous system lesions. Frozen section, cytology or both? *Pathol Res Pract* 2016;212(3):179-184.