

Correlation of Fine Needle Aspiration Cytology with Histopathological Findings in the Diagnosis of Thyroid Swellings – A One Year Study in a Tertiary Care Hospital, Hyderabad

Keerthana Muppidi¹, Vidya Kedarisetti², Kanya Kumari Mahankali³

^{1, 2, 3} Department of Pathology, Mamata Academy of Medical Sciences, Bachupally, Hyderabad, Telangana, India.

ABSTRACT

BACKGROUND

Most of the thyroid swellings are non-neoplastic and with normal thyroid hormone. So, it doesn't require any surgical excision, even though the thyroid swelling is an indication for surgical excision. The present study was done to evaluate the accuracy of fine needle aspiration cytology (FNAC) for the thyroid swellings and correlate it with the histopathological findings.

METHODS

This is a prospective study. A total of 47 cases were studied. Fine needle aspiration cytology was done, slides were made and studied. Histopathological examination of the corresponding 47 cases was also done and correlated with FNAC findings. Sensitivity, specificity and accuracy were calculated.

RESULTS

Age of the patients varied from 20 - 69 yrs. Most of them were in the age group of 30 - 39 years and 50 - 59 years. The ratio of male to female was 1:4.9. Swelling of the neck was the most common presentation in most of the patients. On FNAC 33 (70.2 %) cases were diagnosed as colloid nodular goitre, 04 (8.5 %) as autoimmune thyroiditis, 08 (17.0 %) as follicular neoplasm, 01 (2.1 %) as suspicious of malignancy, 01 (2.1 %) as papillary carcinoma. On histopathological examination 25 (53.2 %) cases were diagnosed as colloid nodular goitre, 01 (2.1 %) as fibrous thyroiditis, 01 (2.1 %) as Graves' disease, 07 (14.9 %) as Hashimoto's' thyroiditis, 06 (12.8 %) as follicular adenoma, 01 (2.1 %) as follicular carcinoma, 04 (8.5 %) as papillary carcinoma and 02 (4.2 %) as NIFTP (non-invasive follicular thyroid neoplasm with papillary like nuclear features). The overall sensitivity was 69.2 %, specificity was 97.0 % and accuracy was 89.3 %.

CONCLUSIONS

FNAC is a minimally invasive, highly accurate and cost-effective procedure. FNAC helps the clinician to diagnose malignant lesions with confidence. It has high rates of specificity and accuracy but comparatively has less sensitivity. However, it is very important for the management of patients with thyroid swelling.

KEYWORDS

Fine Needle Aspiration, Prospective Study, Sensitivity, Specificity, Thyroid Swelling

Corresponding Author:
Dr. Keerthana Muppidi,
Villa No: 25, Anthem Villas,
Gundlapochampally, Near Kompally,
Medchal Road, Secunderabad – 500014,
Telangana, India.
E-mail: Keerthana1990@gmail.com

DOI: 10.18410/jebmh/2021/239

How to Cite This Article?
Muppidi K, Kedarisetti V, Mahankali KK.
Correlation of fine needle aspiration
cytology with histopathological findings
in the diagnosis of thyroid swellings – a
one-year study in a tertiary care hospital,
Hyderabad. J Evid Based Med Healthc
2021;8(18):1246-1251. DOI:
10.18410/jebmh/2021/239

Submission 24-12-2020,
Peer Review 01-01-2021,
Acceptance 13-03-2021,
Published 03-05-2021.

Copyright © 2021 Keerthana Muppidi
et al. This is an open access article
distributed under Creative Commons
Attribution License [Attribution 4.0
International (CC BY 4.0)]

BACKGROUND

Disorders of the thyroid gland are most common among the diseases of the endocrine glands. They may range from malignant, benign tumours to inflammatory (autoimmune), infectious and metabolic disorders. Thorough knowledge of the anatomy, physiology and pathological features of the thyroid gland is necessary for proper management. Most of the thyroid gland disorders can be treated well by medical or surgical management. It is a challenging task to all the clinicians in knowing the exact nature of the thyroid lesions and implementing exact and adequate management to the patients. Thyroid lesions are common in countries where iodine intake is low in the diet. The thyroid disease is more common in females with a female to male ratio of 1.2 to 4.3. The thyroid lesions may indicate an underlying malignancy and sometimes they may cause cosmetic disfigurement. So, thyroid lesions need immediate evaluation and treatment.

Fine needle aspiration cytology (FNAC) is a useful evaluation method in assessment of palpable and non-palpable thyroid masses. It gives us a morphological view of the lesion, thereby becoming the most reliable test for preoperative evaluation of thyroid lesions. It is an outpatient procedure with no mortality or morbidity. Fine needle aspiration cytology (FNAC) has become the dominant method in the evaluation of thyroid nodules, being fast, reliable, safe, minimally invasive, cost effective and reaching high sensitivity and specificity.¹ The lesions in thyroid are varied ranging from inflammation to neoplasm. FNAC of thyroid helps us to categorise the lesions which require surgical intervention and those which do not.^{2,3,4}

Currently many investigations like ultrasound, thyroid nuclear scan and FNAC are available to evaluate thyroid lesions. But FNAC is the gold standard investigation to know the type of thyroid lesion and other investigations provide additional information, so can be used along with FNAC. It is often used as the initial screening test for diagnosis of thyroid nodules.⁵ In a study conducted at Mayo Clinic it showed that there was a drop in patients requiring thyroid surgery after introduction of FNAC and the cost to investigate the thyroid swellings also decreased.

This helps in avoiding unnecessary thyroid surgeries in non-neoplastic conditions of thyroid. However, the limitations of FNAC are the representativeness of area, adequacy of material aspirated and the quality of slide preparation. This may result in false positive and false negative results. If these disadvantages are overcome, FNAC is the best modality for detecting thyroid lesions.

The present study was done to evaluate the role of FNAC in diagnosing thyroid lesions and to correlate the clinical findings with FNAC diagnosis and histopathological diagnosis.

METHODS

The present study is a prospective study conducted for a period of 1 year from August 2019 to July 2020 at Department of Pathology, Mamata Academy of Medical Sciences, Bachupally, Hyderabad. A total of 47 cases were

included and both FNAC and histopathological slides were studied. FNAC was performed with 23-gauge needles, smears were fixed with 95 % alcohol solution. FNAC was done under all aseptic measures and slides were made and stained with Haematoxylin & Eosin and PAP stain. Giemsa stain was not done. In 5 cases ultrasound guided FNAC was done. FNAC reporting was done using Bethesda grading system.

Thyroid specimens after surgery were sent from the department of general surgery for histopathological examination. Thyroid specimens were fixed in 10 % formalin. Grossing was done and representative tissues were processed and embedded in paraffin. Slides were made and stained with H & E.

Written informed consent was taken from the patients who were included in the study. Correlation of histopathological findings was performed with FNAC.

Inclusion Criteria

All patients with thyroid swellings, irrespective of their age and sex who have undergone fine needle aspiration cytology of the swelling, followed by its subsequent histopathological examination were included in the study.

Exclusion Criteria

Patients in whom either of one (histopathological examination / FNAC) was not available were excluded.

Statistical Analysis

The data was first entered in the excel sheet and statistical analysis was done using the SPSS software and data were expressed in percentages and evaluated. Calculation of the sensitivity, specificity, accuracy, positive predictive value and negative predictive value were done.

RESULTS

A total of 47 cases were studied. The age of the patients ranged from 20 to 69 years. Majority were middle aged individuals. 09 (19.1 %) were in the age group of 20 to 29 years, 12 (25.5 %) in 30 to 39 years, 13 (27.6 %) in 40 - 49 years, 12 (25.5 %) in 50 - 59 years and 01 (2.1 %) in 60 - 69 years' age group. Majority were females i.e., 82.9 % (39) and males were 17 % (08). Male to female ratio was 1:4.9.

		Number of Cases (%)
Type of swelling	Diffuse swelling	04 (8.5)
	Solitary nodule (right / left)	26 (55.3)
	Multinodular	17 (36.2)
Duration of swelling	< 1 month	07 (14.9)
	1 month - 1 year	29 (61.7)
	1 - 2 year	10 (21.3)
	> 2 years	01 (2.1)
Presenting complaint	Swelling	35 (74.5)
	Pain	06 (12.8)
	Difficulty in swallowing	03 (6.4)
	Signs and symptoms of hypothyroidism	02 (4.3)
	Signs and symptoms of hyperthyroidism	01 (2.1)

Table 1. Clinical Signs and Symptoms of Thyroid Swellings

Type of Lesion on FNAC		Number of Patients N (%)
Non-neoplastic lesions (37)	Colloid nodular goitre	33 (70.2)
	Autoimmune thyroiditis	04 (8.5)
Neoplastic lesions (10)	Follicular neoplasms	08 (17.0)
	Suspicious of malignancy	01 (2.1)
	Papillary carcinoma thyroid	01 (2.1)
Type of Lesion on Histopathology		Number of Patients N (%)
Non-neoplastic lesions (34)	Colloid nodular goitre	25 (53.2)
	Fibrous thyroiditis	01 (2.1)
	Graves' disease	01 (2.1)
	Hashimoto's' thyroiditis	07 (14.9)
Neoplastic lesions (13)	Follicular Adenoma	06 (12.8)
	Follicular carcinoma	01 (2.1)
	Papillary thyroid carcinoma	04 (8.5)
	NIFTP	02 (4.2)

Table 2. FNAC and Histopathological Diagnosis of Thyroid Swellings

*NIFTP - Non-invasive follicular thyroid neoplasm with papillary like nuclear features

FNAC	Histopathology		Total
	Neoplastic	Non-Neoplastic	
Neoplastic	09	01	10
Non-neoplastic	04	33	37
Total	13	34	47

Table 3. Correlation of Cytology and Histopathology Diagnosis (N = 47)

Sensitivity	69.2 %
Specificity	97.0 %
Accuracy	89.3 %
Positive predictive value	90.0 %
Negative predictive value	89.1 %

Table 4. Statistical Analysis

FNAC Diagnosis	No. of Cases	Histopathological Diagnosis	No. of Cases	Remark
Colloid nodular goitre	33	Colloid nodular goitre	24	True negatives
		Fibrous thyroiditis	01	True negative
		Graves' disease	01	True negative
		Hashimoto's' thyroiditis	03	True negative
		Follicular adenoma	03	False negatives
		Papillary thyroid carcinoma	01	False negative
Autoimmune thyroiditis	04	Hashimoto's' thyroiditis	04	True negatives
Follicular neoplasm	08	Follicular adenoma	03	True positives
		Papillary thyroid carcinoma	02	True positives
		Follicular carcinoma	01	True positive
		NIFTP	02	True positives
Suspicious of malignancy	01	Nodular goitre	01	False positive
Malignancy	01	Papillary thyroid carcinoma	01	True positive

Table 5. FNAC and Histopathological Correlation

FNAC reporting was done by Bethesda grading system. On FNAC out of 47 cases, 37 were diagnosed as non-neoplastic which included colloid nodular goitres (33) and autoimmune thyroiditis (04). 2 out of 33 colloid goitres showed cystic change. 10 out of 47 were diagnosed as neoplastic which included follicular neoplasms (08), suspicious of malignancy (01) and papillary carcinoma thyroid (01). In histopathological examination 34 out of 47 were diagnosed as non-neoplastic which included colloid nodular goitre, fibrous thyroiditis, Graves' disease, and Hashimoto's' thyroiditis. 13 out of 47 were diagnosed as neoplastic which included follicular adenomas (06), follicular carcinoma (01), non-invasive follicular thyroid neoplasm with papillary like nuclear features (NIFTP) (02) and papillary carcinomas (04).

DISCUSSION

In the present study, FNAC features of the thyroid swellings were reported using the Bethesda grading system and correlated with histopathological findings, to determine the

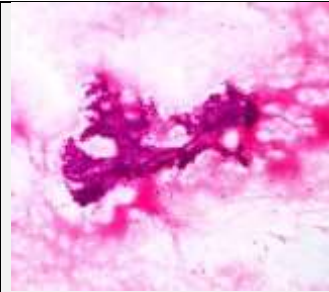
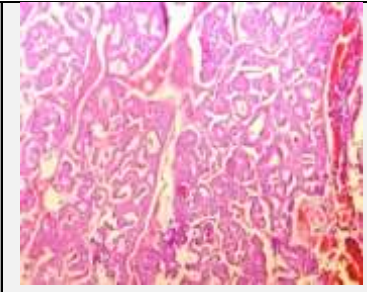

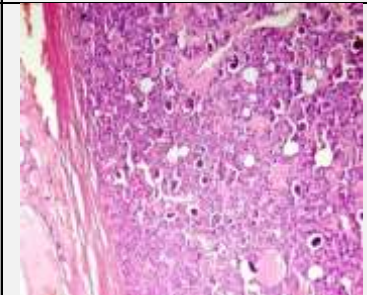
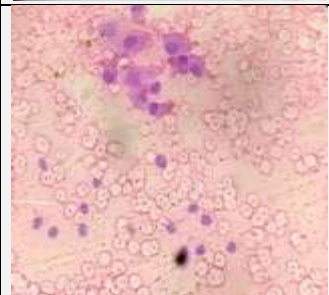
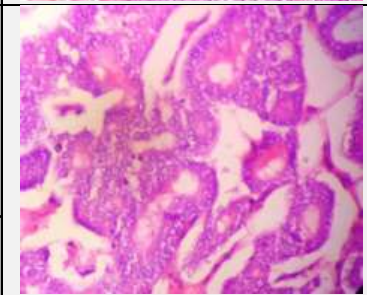
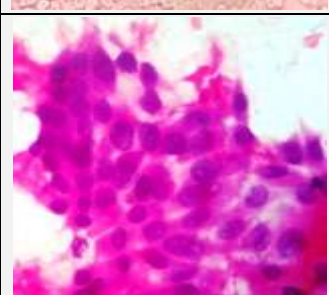
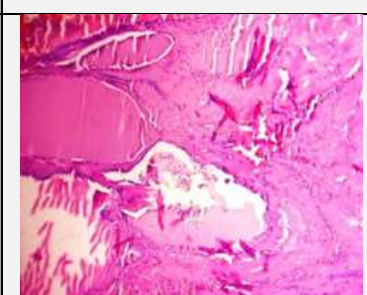
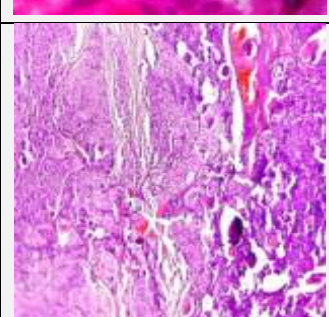
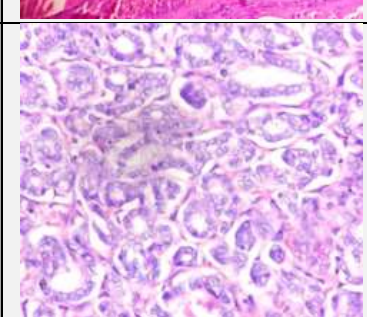
diagnostic accuracy of FNAC. A total of 47 cases of thyroid lesions who underwent FNAC with subsequent histopathological examination were included in the study and all the lesions were analysed with their history, FNAC findings and histopathology. In the present study, age of the patients ranged from 20 - 70 years. The highest number of cases were seen in the age group of 40 - 49 years (27.6 %) followed by the age group of 30 - 39 years (25.5 %) and 50 - 59 years (25.5 %) which was almost similar to Kumar S, et al.⁶ study.

There was a female predominance with a F:M ratio of 4.9:1 in our study which was almost similar to Kumar S. et al.⁶ and C.P. Luck et al.⁷ studies. One case which was diagnosed as nodular goitre with cystic change on FNAC was found to be papillary carcinoma of thyroid on histopathological examination. This error occurred because FNAC was done from a cystic area resulting in plenty of cyst macrophages and few thyroid follicular cells so the diagnosis of papillary carcinoma of thyroid was missed and was misinterpreted and the diagnosis of benign lesion was made. Cystic change in thyroid swellings is the common cause of pitfall in diagnosis by FNAC. In such cases of mainly cystic papillary carcinomas, chances of false negative reporting are done by FNAC. Over 40 % of the cystic neoplasms may be missed by FNAC. Amatya et al.⁸ and Fernandes H et al.⁹ also found a similar misdiagnosis in their study.

In some papillary thyroid carcinomas, the nuclear changes are subtle and focal. This is particularly true of the macrofollicular variant, which can be difficult to distinguish from a benign follicular nodule.¹⁰ Out of 4 false negative cases, 03 were diagnosed as follicular adenoma on histopathology which were given as nodular goitre on FNAC. In all the three cases patients presented with single nodular thyroid swelling and on FNAC they showed focal repetitive microfollicular arrangement, scant colloid and cyst macrophages were not evident. These findings lead to an erroneous diagnosis on FNAC. Clary et al.¹¹ also have referred to this inter observer variability in their study. 04 cases given as autoimmune thyroiditis on FNAC were diagnosed as Hashimoto's' thyroiditis on histopathological examination. The cytologic diagnosis of Hashimoto's' thyroiditis is usually straightforward.

In the present study autoimmune thyroiditis was found only in females in the age group of 30 to 40 years. But the final diagnosis was with thyroid hormonal analysis. On FNAC, 10 cases were diagnosed as neoplastic lesions which included 08 cases of follicular neoplasm, 01 case as suspicious of malignancy and 01 as papillary carcinoma of thyroid. 9 out of 10 cases diagnosed as neoplastic on cytology were proven to be neoplastic by histopathology as well. One case which was diagnosed as suspicious of malignancy on FNAC because of nucleomegaly, focal nuclear overlapping and nuclear pseudo inclusions was diagnosed as multinodular goitre on histopathology. This resulted in one false positive case in the present study.

Sometimes a nodule in a multinodular goitre or a follicular adenoma is composed mainly of micro follicles or trabeculae and is erroneously reported as suspicious of malignancy by FNAC.

	<p>Figure 1a. (Left) Photomicrograph of FNAC of Papillary Carcinoma of Thyroid Showing Thyroid Follicular Cells Arranged in Papillary Pattern (H & E 10X)</p>		<p>Figure 1b. (Right) Histopathology of Papillary Carcinoma of Thyroid Showing Papillary Arrangement with Fibrovascular Cores and Ground Glass Nuclei. (H & E 40X) (True Positive)</p>
	<p>Figure 1c. (Left) Photomicrograph of FNAC of Follicular Neoplasm Showing Thyroid Follicular Cells Arranged in Repetitive Microfollicular Arrangement with Scant Colloid (H & E 40X)</p>		<p>Figure 1d. (Right) Histopathology Showing Intact Capsule and Mainly Microfollicular Arrangement (H & E 40X) (True Positive)</p>
	<p>Figure 1e. (Left) Photomicrograph of FNAC Diagnosed as Nodular Goitre with Cystic Change Showing Mainly Cyst Macrophages and Few Thyroid Follicular Cells (H & E 40X)</p>		<p>Figure 1f. (Right) Histopathology Diagnosed as Papillary Carcinoma Showing Ground Glass Nuclei and Papillary Arrangement (H & E 40X) (False Negative)</p>
	<p>Figure 1g. (Left) Photomicrograph of FNAC Diagnosed as Suspicious of Malignancy Showing Nucleomegaly, and Nuclear Grooves (H & E 40X).</p>		<p>Figure 1h. (Right) Histopathology Diagnosed as Nodular Goiter Showing Macrofollicles Filled with Colloid and Areas of Haemorrhage (H & E 40X) (False Positive)</p>
	<p>Figure 1i. Photomicrograph of Histopathology of Follicular Carcinoma Showing Capsular Invasion and Microfollicular Arrangement (H & E 40X)</p>		<p>Figure 1j. Photomicrograph of Histopathology of Non-Invasive Follicular Neoplasm with Papillary Like Nuclear Features (NIFTP) Showing Follicular Arrangement and Ground Glass Nuclei (H & E 40X)</p>

This is a well-known limitation of thyroid FNAC. However, in place of FNAC there is no alternative reliable investigation to help in reducing the reporting of false suspicious cases. Follicular adenomas are the most common causes for false positive reporting by FNAC.

Out of 08 cases diagnosed as follicular neoplasm in FNAC, in histopathology 03 were diagnosed as follicular adenoma, 01 was diagnosed as follicular carcinoma as it showed capsular invasion, 02 were diagnosed as papillary thyroid carcinoma and 02 cases were given as non-invasive follicular thyroid neoplasm with papillary like nuclear features (NIFTP).

Here the distinction between follicular adenoma and follicular carcinoma by FNAC was not possible. One case given as follicular neoplasm in FNAC was diagnosed as a follicular variant of papillary carcinoma of thyroid. In this case on FNAC, follicular arrangement of thyroid cells was seen but papillary thyroid carcinoma nuclear features were not evident.

In the present study FNAC of the thyroid lesions had a sensitivity of 69.2 % and specificity of 97.0 %. The overall diagnostic accuracy was 89.3 % in the present study.

Results of various previous studies showed the sensitivity of thyroid cytology ranged approximately from 60 % to 92 %.

In the present study, sensitivity of thyroid cytology was 69.2 % which is close to that of Bamanikar et al.¹² study.

Specificity of thyroid cytology ranged from approximately 72 % to 98 % in different previous studies. In the present study, the specificity of thyroid cytology was 97.0 % which is close to the Bamanikar et al.¹² Chaudhari S et al.¹³ Md Iqbal Karim et al.¹⁴ studies.

The accuracy of FNAC of thyroid showed by previous studies ranged from 80 % to 97 %. In the present study, the accuracy of thyroid cytology was 89.3 % which was slightly close to the other studies like Chaudhari Set al.¹³ and Bamanikar et al.¹²

In the present study positive predictive value was 90 % and negative predictive value was 89.1 % whereas FNAC had a positive predictive value of 95.6 % and negative predictive value of 94.2 % in C.P. Luck et al.⁷ study. Positive predictive value and negative predictive values were 98.7 % and 76.6 % in Kessler et al.¹⁵ study, 92.8 % and 94.7 % in Afroze et al.¹⁶ study.

Authors Name	Publication Year	No. of Cases	Sensitivity (%)	Specificity (%)	Accuracy (%)
Mandal et al. ¹⁷	2011	120	90	84.6	97.0
Pinky pandey et al. ¹⁸	2012	447	57.14	90	80.28
Bamanikar et al. ¹²	2014	300	65	98	94.2
Chaudhari S et al. ¹³	2015	52	90	96	94
Tazeen Jeelani et al. ¹⁹	2018	400	92.2	72	83.5
Md Iqbal Karim et al. ¹⁴	2019	60	90.2	98.2	97.1
Present study	2020	47	69.2	97.0	89.3

Table 6. Statistical Comparison of the Present Study with Previous Studies

CONCLUSIONS

FNAC is a rapid, efficient, cost-effective, relatively painless procedure and produces an early result with a high diagnostic accuracy. FNAC is more specific than sensitive.

Many factors can interfere in obtaining accurate results by FNAC. These include inadequate sampling, reporting error due to the inexperience of the pathologist. Sample can be inadequate due to multiple reasons in case of FNAC of the thyroid swelling which includes aspiration from sclerotic, calcified nodule, or nodule with cystic degeneration in large areas and haemorrhagic aspirates due to rich vascularity of thyroid gland.

The accuracy of diagnostic FNAC can be increased if correlated with ultrasound findings and should be ultrasound guided wherever possible. In the present study the correlation between the FNAC and sonography findings were not done and this may be the cause of discordance between FNAC and histopathology report found in a few cases. Many factors may contribute to discordance between FNAC and histopathology, but in the present study the main factor was the sampling error.

FNAC is not the final diagnostic tool for thyroid lesion. However, it is an important step in the management of those with thyroid lesion.

Data sharing statement provided by the authors is available with the full text of this article at jebmh.com.

Financial or other competing interests: None.

Disclosure forms provided by the authors are available with the full text of this article at jebmh.com.

REFERENCES

- [1] Ashcraft MW, Van Herle AJ. Management of thyroid nodules. I: history and physical examination, blood tests, X-ray tests and ultrasonography. *Head and Neck Surgery* 1981;3(3):216-230.
- [2] Das KD, Khanna CM, Tripathi RP, et al. Solitary nodular Goiter: review of cytomorphologic features in 441 cases. *Acta Cytol* 1999;43(4):563-574.
- [3] Afroze N, Kayani N, Hasan SH. Role of fine needle aspiration cytology in the diagnosis of palpable thyroid lesions. *Indian J Pathol Microbiol* 2002;45(3):241-246.
- [4] Handa U, Garg S, Mohan H, et al. Role of fine needle aspiration cytology in diagnosis and management of thyroid lesions: a study on 434 patients. *J Cytol* 2008;25(1):13-17.
- [5] Oertel YC. Fine-needle aspiration and the diagnosis of thyroid cancer. *Endocrinology and Metabolism Clinics of North America* 1996;25(1):69-91.
- [6] Kumar S, Aqil S, Dahar A. Role of fine needle aspiration cytology in thyroid diseases. *J Surg Pak* 2008;13(1):22-25.
- [7] Luck CP, Jamunarani S, Madasamy B, et al. Evaluation of diagnostic accuracy of FNAC and correlation with histopathology in thyroid lesions. *Trop J Path Micro* 2017;3(2):96-101.
- [8] Amatya BB, Joshi AR, Singh SK, et al. A study of fine needle aspiration cytology of head and neck masses and their corroboration by histopathology. *Postgraduate Medical Journal of National Academy of Medical Sciences* 2009;6:52-60.
- [9] Fernandes H, D'Souza CRS, Thejaswini BN. The role of fine needle aspiration cytology in palpable head and neck masses. *Journal of Clinical and Diagnostic Research* 2009;(3):1719-1725.
- [10] Chung D, Ghossein RA, Lin O. Macrofollicular variant of papillary carcinoma: a potential thyroid FNA pitfall. *Diagn Cytopathol* 2007;(9)35:560-564.
- [11] Clary KM, Condel JL, Liu Y, et al. Interobserver variability in the fine needle aspiration biopsy diagnosis of follicular lesions of the thyroid gland. *Acta Cytologica* 2005;49(4):378-382.
- [12] Bamanikar S, Soraisham P, Jadhav S, et al. Cyto-histology and clinical correlation of thyroid gland lesions: a 3 year study in a tertiary hospital. *Clin Cancer Invest J* 2014;3(3):208-212.
- [13] Chaudhari S, Hatwal D, Bhat P, et al. cytological evaluation of thyroid lesions and its correlation with histopathology: a prospective study. *Int J Sci Stud* 2015;3(8):132-135.
- [14] Md Iqbal K, Rosen N, Nikolay S, et al. A study on evaluation of solitary nodular thyroid lesions by FNAC

- and its histopathological correlation. Bangladesh Journal of Medical Science 2019;18(4):789-795.
- [15] Kessler A, Gavriel H, Zahav S, et al. Accuracy and consistency of fine-needle aspiration biopsy in the diagnosis and management of solitary thyroid nodules. Israel Medical Association Journal 2005;7(6):371-373.
- [16] Afroz N, Kayani N, Hasan SH. Role of fine needle aspiration cytology in diagnosis of palpable thyroid lesions. Indian Journal of Pathology and Microbiology 2002;45(3):241-246.
- [17] Mandal S, Barman D, Mukherjee A, et al. Fine needle aspiration cytology of thyroid nodules – evaluation of its role in diagnosis and management. J Indian Med Assoc 2011;109(4):258-261.
- [18] Pandey P, Dixit A, Mahajan NC. Fine-needle aspiration of the thyroid: a cytohistologic correlation with critical evaluation of discordant cases. Thyroid Research and Practice 2012;9(2):32-39.
- [19] Tazeen J, Danish R, Wajahat-Un N, et al. Histopathological and cytological correlation of thyroid nodules with emphasis on the Bethesda system for reporting thyroid cytology a 7 year study. International Journal of Contemporary Medical Research 2018;5(1):28-31.