

COMPARISON BETWEEN LAPAROSCOPIC SUTURE RECTOPEXY AND ALTEMEIER'S PROCEDURE FOR THE MANAGEMENT OF COMPLETE RECTAL PROLAPSE- A SINGLE CENTER RETROSPECTIVE OBSERVATIONAL STUDY

Balakrishna Nanjundappa Setty¹, Sushrutha C. Suresh², Sathish Obalanarasimhaiah³, Aravinda Nirmala Kotresh⁴, Savitha Krishnagouda Karlwad⁵, Venugopal Hunasanahalli Giriappa⁶, Vinay Boppasamudra Nanjegowda⁷, Nagesh Nayakarahalli Swamygowda⁸

¹Assistant Professor, Department of Surgical Gastroenterology, Bangalore Medical College and Research Institute, Bangalore.

²Assistant Professor, Department of Surgical Gastroenterology, Bangalore Medical College and Research Institute, Bangalore.

³Senior Resident, Department of Surgical Gastroenterology, Bangalore Medical College and Research Institute, Bangalore.

⁴Resident, Department of Surgical Gastroenterology, Bangalore Medical College and Research Institute, Bangalore.

⁵Senior Resident, Department of Surgical Gastroenterology, Bangalore Medical College and Research Institute, Bangalore.

⁶Associate Professor, Department of Surgical Gastroenterology, Bangalore Medical College and Research Institute, Bangalore.

⁷Professor, Department of Surgical Gastroenterology, Bangalore Medical College and Research Institute, Bangalore.

⁸Professor and HOD, Department of Surgical Gastroenterology, Bangalore Medical College and Research Institute, Bangalore.

ABSTRACT

BACKGROUND

Rectal prolapse is defined as protrusion of rectal wall through the anal canal. It is further classified into 3 different categories based on the extent of rectal prolapse called partial thickness (mucosal) rectal prolapse when only the mucosa is prolapsed through the anal verge, complete rectal prolapse (procidentia) involves full thickness of rectal wall prolapsing out of the anal verge and internal rectal prolapse (rectal intussusception) involves intussusception of the rectum into the anal canal without protrusion beyond the anal verge. Rectal prolapse can be partial to begin with and may or may not progress to complete rectal prolapse.

The aim of our study is to analyse and compare two surgical techniques laparoscopic suture rectopexy and Altemeier's procedure available for the management of rectal prolapse along with the outcomes of both in a single centre.

MATERIALS AND METHODS

The study was conducted in Department of Surgical Gastroenterology, Bangalore Medical College and Research Institute, Karnataka. It's a retrospective observational study conducted between August 2012 and May 2016. The presenting feature, intraoperative events, postoperative course, complications and follow up were noted with regard to faecal incontinence, constipation and recurrent prolapse.

RESULTS

A total of 35 patients were included in this study. The male-to-female ratio was 1.7:1. The presenting feature being intermittent rectal prolapse in 31 (88%), irreducible rectal prolapse in 2 (5.7%) and 2 (5.7%) patients were operated for recurrent rectal prolapse. The presenting symptom in the patients were constipation in 14 (40%), incontinence in 5 (14.28%) and solitary rectal ulcer syndrome in 3 (8.6%). 20 patients (57.14%) underwent laparoscopic suture rectopexy with conversion to open in two patients. 15 (42.8%) patients underwent Altemeier's procedure. The average total duration of hospital stay for patients with suture rectopexy was 3.05263 days and for Altemeier's procedure was 5.73333 days with a statistically significant difference (p value <0.001). Morbidity in the suture rectopexy group was seen in 3 patients and in Altemeier's group in 7 patients. No recurrence was seen in our follow up of 1 to 2 years.

CONCLUSION

Successful treatment of rectal prolapse is accomplished by restoration of both the anatomy and physiology of the rectum. Although, no significant differences were seen in randomised studies, the treatment should be individualised to attain satisfactory results in terms of postop bowel movements and to prevent recurrences. In our study, we observed that the patients undergoing laparoscopic suture rectopexy had higher incidence of constipation postoperatively and patients undergoing Altemeier's had higher incidence of incontinence postoperatively.

KEYWORDS

Laparoscopic Suture Rectopexy, Altemeier's Procedure, Rectal Prolapse.

HOW TO CITE THIS ARTICLE: Setty BN, Suresh SC, Obalanarasimhaiah S, et al. Comparison between laparoscopic suture rectopexy and Altemeier's procedure for the management of complete rectal prolapse- A single center retrospective observational study. J. Evid. Based Med. Healthc. 2017; 4(44), 2685-2690. DOI: 10.18410/jebmh/2017/534

*Financial or Other, Competing Interest: None.
Submission 15-05-2017, Peer Review 19-05-2017,
Acceptance 28-05-2017, Published 31-05-2017.*

Corresponding Author:

*Dr. Balakrishna Nanjundappa Setty,
Assistant Professor, Department of Surgical Gastroenterology,
Bangalore Medical College and Research Institute,
Bangalore-560002.*

E-mail: drbalakrishna@live.com

DOI: 10.18410/jebmh/2017/534



BACKGROUND

Rectal prolapse is defined as protrusion of rectal wall through the anal canal. It is further classified into 3 different categories based on the extent of rectal prolapse called partial thickness (mucosal) rectal prolapse when only the mucosa is prolapsed through the anal verge, complete rectal prolapse (procidentia) involves full thickness of rectal wall prolapsing out of the anal verge and internal rectal prolapse (rectal intussusception) involves intussusception of the rectum into the anal canal without protrusion beyond the anal verge. Rectal prolapse can be partial to begin with and may or may not progress to complete rectal prolapse.

Rectal prolapse occurs in extremes of ages and women are more commonly affected than men representing 80-90% of the affected population.¹ Patients with rectal prolapse present with wide range of symptoms such as mass protruding per anus, bleeding per rectum, constipation, faecal incontinence and painful irreducible mass per rectum.

Multiple aetiological factors have been proposed for rectal prolapse like deep cul-de-sac, redundant sigmoid colon and defective posterior anchorage of the rectum to the sacrum, long rectal mesentery, sacral defects and obstetric injuries to the anal sphincters.² In addition, neurological and connective tissue disorders can result in the condition. As a result of the breadth of causes, no perfect treatment option has been determined.

Many surgical techniques are available in the treatment of rectal prolapse. The various approaches used can be divided into abdominal and perineal.³ The goal of any surgical option advocated for the treatment of rectal prolapse is to restore the altered anatomy and to re-establish the capacitative function of the rectum. Abdominal procedures despite having higher postoperative complications are associated with lower recurrence rates and are preferred in younger and healthier patients who can tolerate general anaesthesia and prolonged surgery.⁴ Perineal procedures though associated with higher chances of recurrence are best suited for elderly, frail patients with multiple comorbidities who cannot tolerate a major abdominal procedure and general anaesthesia.⁵ With the development of laparoscopic surgery along with the recovery benefits of laparoscopic surgery, the opportunity to utilise the open abdominal approach have been decreased, thus making laparoscopic surgery as the standard of care in fit patients for rectal prolapse. Here is an observational study comparing two surgical techniques used for treatment of rectal prolapse, laparoscopic suture rectopexy and

Altemeier's procedure along with its outcome and long-term results.

MATERIALS AND METHODS

The study was conducted in Department of Surgical Gastroenterology, a Tertiary Referral Government Hospital, Bangalore Medical College and Research Institute, Karnataka, during the period from August 2012-May 2016. It is a retrospective observational study conducted between August 2012 and May 2016. From each of the patient involved in the study group, the following information were collected regarding demographic details like age, sex, presenting features, intraoperative events, postoperative course, complications, retrospectively from prospectively maintained database and medical records of the hospital. The follow up was done for each patient for a period of one to two years and analysed with regard to the following parameters like faecal continence, constipation and recurrent prolapse.

Inclusion Criteria were-

- Rectal prolapse visible with or without straining.
- Aged 11 years and older.

Exclusion Criteria were-

- Patients who underwent abdominal or perineal procedures other than suture rectopexy and Altemeier's procedure.
- Age less than 10 yrs.
- Patients who had previous abdominal surgery for causes other than rectal prolapse.

Outcomes of Interest

The primary outcomes evaluated were-

- 1) Recurrence of rectal prolapse. Recurrence was defined as the circular protrusion of rectal mucosa through the anal canal and was evaluated by history, clinical examination including examination of patients while performing a straining manoeuvre in a sitting position.
- 2) Postoperative morbidity.
- 3) Postoperative bowel habits incontinence or constipation.

The secondary outcomes of interest were-

- 1) Operative time.
- 2) Surgical site infections.
- 3) Total duration of hospital stay.

Preoperative Assessment-

Patients presenting to the outpatient department with chief complaints and history suggestive of rectal prolapse were included in the study. In each patient, the details of bowel habits were noted and constipation was defined as per Rome III criteria and graded as per Cleveland Clinic Constipation Score (CCCS), faecal incontinence was graded as per Werner's scoring system (the sum of 5 parameters is determined TNT are scored on a scale from 0 (absent) to 4 (daily) frequency of incontinence to gas, liquid and solid, of

need to wear pad and of lifestyle changes. A score of 0 means perfect control, a score of 20 complete incontinence). All patients were examined clinically both in lying down and squatting position. If prolapse was not evident in resting position, patients were asked to "bear down" in squatting position. In all patients relevant blood investigations were performed. Patients with reducible rectal prolapse were subjected to full length colonoscopy to look for any associated organic pathologies, which could entirely change the management strategy of rectal prolapse.

Patients received balanced polyethylene solution for bowel preparation preoperatively, one day prior to surgery and prophylactic antimicrobial therapy was given at the time of induction of anaesthesia.

Decision for laparoscopic suture rectopexy or Altemeier's procedure as the treatment modality for an individual was as per the clinical judgement of the senior colorectal surgeons in the department and the senior anaesthetist. Patients with reducible rectal prolapse, fit to undergo general anaesthesia underwent laparoscopic suture rectopexy and patients with irreducible prolapse, incarcerated prolapse who needed emergency surgery, unfit for general anaesthesia underwent Altemeier's procedure.

Surgical Technique

Laparoscopic Suture Rectopexy

The surgery was performed under general anaesthesia. Patients were catheterised and placed in Trendelenburg position. We used a four-port technique using two 10 mm and two 5 mm ports. The dissection was started by opening peritoneum on right side of rectum using harmonic scalpel/diathermy after identifying right ureter and safeguarding it. Then, dissecting rectum from presacral fascia in holy plane of safety staying close to rectum to avoid injury to autonomic nerves and presacral venous plexus. On left side dissection was done after identifying left ureter. Dissection was carried out downwards till pelvic floor. The anterior peritoneal fold in the rectovesical pouch were cut, lifting the rectum completely from sacral hollow. The lateral ligaments were not cut during the procedure. The rectum was hitched by suturing the mesorectum to the sacral promontory with 2-0 Prolene using one suture on either side.

Altemeier's Procedure

After subjecting the patient to regional anaesthesia, the patient was placed in lithotomy position. The prolapse was reduced and the dentate line was identified. One cm proximal to the dentate line, a full thickness incision was made and the dissection was continued proximally until the peritoneal reflection was identified. The peritoneum was opened and further redundancy of the sigmoid colon was assessed and the same redundant segment was sequentially devascularised. The redundant segment was excised and coloanal anastomosis was performed using 2.0 polyglactin (Vicryl) suture.

RESULTS

The total number of patients in our study group were 35 in number during the study period. Among the 35 patients, males were 22 (62.8%) in number and females were 13 (37.1%) in number. In our study, the male-to-female ratio of patients with rectal prolapse was found to be 1.7:1 compared to that of the west where females predominate with a ratio of 6:1.⁶ This distribution is consistent with previous studies reported from India.^{7,8} The average age of presentation with the symptoms of rectal prolapse (mass protruding per rectum) for females was 49.51 yrs. and for males was 50.41 suggesting no significant difference. The presenting feature being intermittent rectal prolapse in 31 (88%) patients, irreducible rectal prolapse in 2 (5.7%) patients, 2 (5.7%) were operated for recurrent rectal prolapse. The presenting symptoms in the patients were as follows- constipation in 14 (40%), incontinence in 5 (14.28%) and solitary rectal ulcer syndrome was diagnosed in 3 (8.6%) patients.

Out of the 35 patients, 20 patients (57.14%) underwent laparoscopic suture rectopexy. Out of these 20 patients, 18 (51.4%) patients had complete laparoscopic suture rectopexy and two (5.7%) underwent conversion from laparoscopic to open suture rectopexy because of bleeding and adhesions. The remaining 15 (42.8%) patients underwent perineal procedure- Altemeier's procedure. The average total duration of stay for patients with suture rectopexy was 3.05263 days and for Altemeier's procedure was 5.73333 days. Applying the Mann-Whitney Rank sum test for comparison of the length of hospital stay in both the groups, laparoscopic suture rectopexy and Altemeier's procedure showed a statistically significant difference (p value <0.001). Morbidity in the suture rectopexy group was seen in 3 patients (1 developed new-onset constipation, 1 had persistence constipation, 1 had paralytic ileus). Morbidity in Altemeier's group was seen in 7 patients (2 had wound infections, 1 developed new-onset incontinence, 2 had persistent incontinence, 1 paralytic ileus and 1 pelvic abscess). No recurrence was seen in any of our patients operated in either of the group patients either laparoscopic rectopexy or with Altemeier's procedure during our follow up period of 1 to 2 years.

As the surgical procedure was selected irrespective of the preoperative bowel habits of the 20 number of patients undergoing laparoscopic suture rectopexy, 1 developed new-onset constipation and 1 had persistent constipation. In the Altemeier's group, 1 patient developed new-onset incontinence and 2 had persistence incontinence. No mortality and no major morbidity was noted. No recurrence was noted in our follow up period of 2 years.

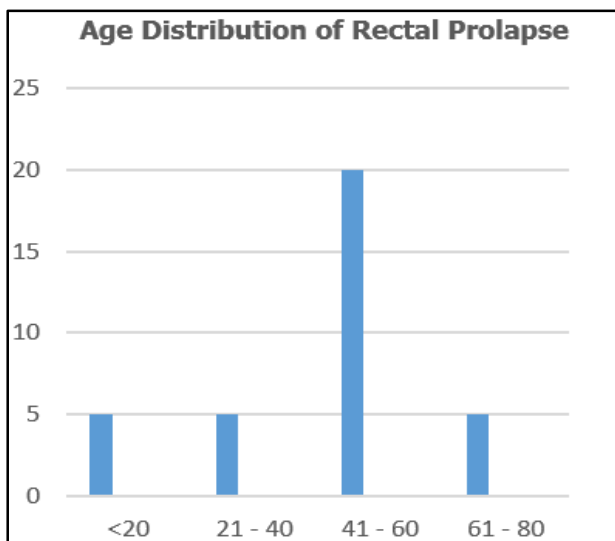


Figure 1. Age Distribution of Rectal Prolapses

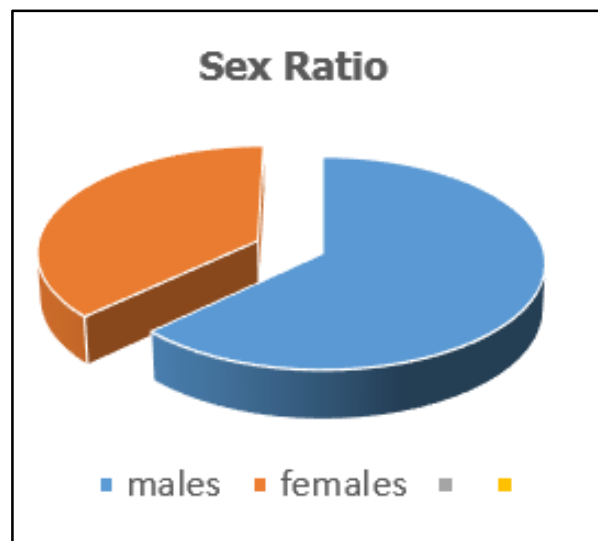


Figure 2. Sex Ratio

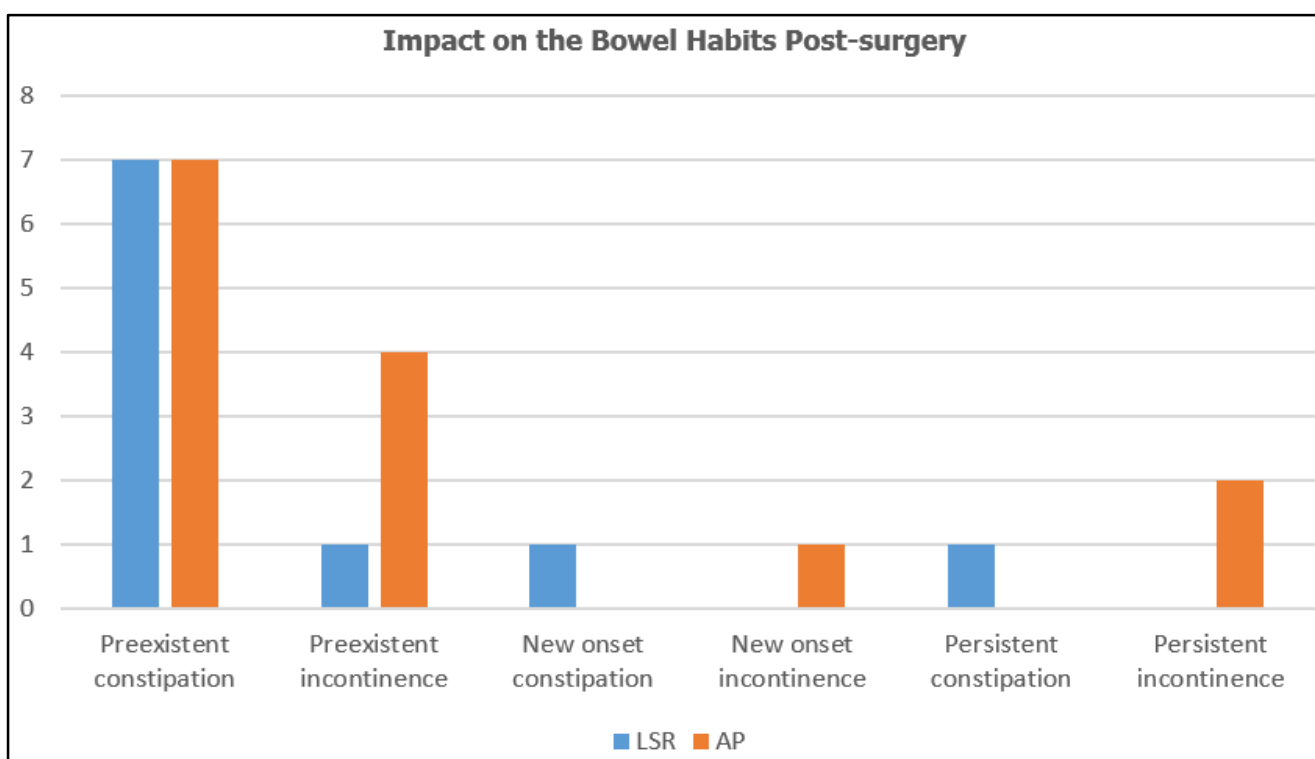


Figure 3. Impact on the Bowel Habits Post Surgery

DISCUSSION

Rectal prolapse is a rare disease. Rectal prolapse is described as the disease of elderly females in western literature,⁶ but in our study, there is slight predominance of male compared to females with ratio of 1.7:1. This distribution is consistent with previous studies reported from India.^{7,8} There are many modalities of treatment available for the treatment of rectal prolapse. Both abdominal and perineal procedures are available for treatment of rectal prolapse and have been evolved during the years. The goal of any surgery in rectal prolapse is the correction of the anatomical defect, improvement of bowel function and prevention of de novo functional problems. The problem of complete rectal prolapse is formidable with no clear predominant treatment of choice. A variety of abdominal

surgical procedures have been practised both open and laparoscopic. Laparoscopic procedures for complete prolapse have become the operations of choice because of the benefits of minimally-invasive surgery along with comparative rates of recurrence.⁹ The advantages of laparoscopic rectopexy over open rectopexy are all short term, but there is no evidence of any adverse effect on long-term outcomes, hence making it the approach of choice.¹⁰ Majority of them include mobilisation of the rectum followed by fixation of the rectum to the sacrum either by sutures or by a mesh. Laparoscopic suture rectopexy has slight edge in improvement of continence over mesh rectopexy by the fact that mesh interferes in rectal distensibility as compared to sutures only.¹¹ Ripstein’s mesh rectopexy has a 7% chance of mesh erosion and rectal stenosis.¹² It’s also known that

the incidence of large bowel obstruction, ureteral injury, rectovaginal fistula is significantly high with Ripstein's mesh rectopexy. Similarly, the use of ventral mesh rectopexy though seems a simple technique in view of no posterior mobilisation of the rectum and comparable recurrence rates to that of posterior mesh rectopexy is associated with very high rate of new-onset constipation of 14.4%¹³ and hence minimally-invasive abdominal procedures incorporating the posterior fixation of the rectum are the procedures of choice for rectal prolapse patients.¹⁴ Hence, in our study, patients who were fit to undergo general anaesthesia, laparoscopic suture rectopexy was used as the procedure of choice to treat rectal prolapse.

The perineal procedures are used in elderly and frail patients who cannot tolerate general anaesthesia. The perineal procedures commonly used are Delorme's and Altemeier's proctosigmoidectomy. The perineal procedures commonly chosen for mucosa only prolapse or a short segmental full thickness prolapse are Delorme's procedure. The Delorme's procedure, which is more of an anatomical correction in the form of mucosal sleeve resection and imbrication of the rectal musculature is associated with a higher rate of recurrence of 10-15% compared to abdominal approaches and also associated with increased risk for urinary retention and faecal impaction.¹⁵ The Altemeier's procedure chosen more commonly for elderly patients with significant comorbidities is associated with significantly higher rates of recurrence 18% and postoperative continence is unpredictable.¹⁶ A study S.D. Werner and colleagues has clearly shown the reduced incidence of incontinence with the addition of levatorplasty.¹⁷

A rare complication of rectal prolapse is the strangulation (2-4%)^{18,19} and irreducibility. When the incarcerated rectal prolapse cannot be manually reduced, a few techniques may help the bowel return to its anatomic position such as sedation, Trendelenburg position and topical application of salt and sucrose, which may decrease bowel oedema and enable reduction. A strapping can be combined in order to maintain the reduction.¹⁹ The definitive treatment of the prolapse is then carried out later. Failing to reduce or in case of necrosis, the only treatment is an emergent surgery.^{18,19} The intervention of choice is the Altemeier's procedure.^{18,19} Hence, in our study, patients who were not fit to undergo general anaesthesia and who had irreducible rectal prolapse Altemeier's procedure was used as the treatment of choice.

In our study, constipation was present in 7 of 20 patients in suture rectopexy group out of which one patient had new-onset constipation and other patient had persistence constipation during follow up period. Constipation is a common problem after rectopexy particularly after prosthetic mesh rectopexy.²⁰ Studies have demonstrated that constipation increased from 10-47% and suggested a link with denervation of the left colon from rectum with possible kinking at the rectosigmoid junction, a redundant unresected sigmoid colon. This maybe especially so because the lateral ligaments containing the parasympathetic inflow to the left colon maybe cut during mobilisation. The use of posterior mesh rectopexy to induce fibrosis and promote

fixation is associated with sepsis and a higher incidence of constipation.²⁰ Suture rectopexy has been shown to be equally effective as mesh rectopexy in preventing recurrence, but avoids problems of postoperative sepsis and increased constipation.²¹

In spite of the varied surgical approaches and procedures advocated for the treatment of rectal prolapse, no significant differences were observed in the randomised comparisons with regard to the chosen surgical procedure to correct the prolapse as shown by PROSPER (prolapse surgery perineal rectopexy) trial conducted by A. Senapathi and colleagues.²² The right answer probably does not lie in a single operation, but in tailoring the most appropriate treatment to each individual patient. However, the laparoscopic approach was not specifically examined in this trial.

Laparoscopic surgery has revolutionised surgical practice over the years. Many operations that would have previously resulted in prolonged hospital admissions are managed within either the 'Short Stay' or even the 'Day Care' units. The impact of shorter lengths of stay has a beneficial effect on both patients' expectations and allocation of finite healthcare resources. By virtue of its minimally-invasive character with the lack of large wounds, recovery times are significantly reduced compared with open procedures. Laparoscopic application to rectopexy, therefore makes it a realistic option for daycare surgery. This is also seen in our study that the length of hospital stay was less in laparoscopic group was 3.05263 days and for Altemeier's procedure was 5.73333 days with a significant p value of <0.001. Hence, laparoscopic suture rectopexy is the surgical procedure of choice in all patients with rectal prolapse who can withstand general anaesthesia.

CONCLUSION

Rectal prolapse although a benign disease is associated with formidable morbidity in the form of persistent perineal pain, uneasiness, mucus and bloody discharge and occasionally irreducibility and incarceration. Laparoscopic suture rectopexy because of its safety in experienced hands and comparable recurrent prolapse rates with other abdominal procedures and with an added advantage of less associated morbidity due to the procedure and shorter duration of hospital stay can be considered as the procedure of choice for patients who can tolerate general anaesthesia and constipation not dominating the symptomatology. Altemeier's procedure is the procedure of choice, which can be done in spinal anaesthesia for irreducible/incarcerated prolapse as it usually occurs in elderly frail patient who have associated comorbidities and cannot withstood general anaesthesia. Except for the increased postoperative incontinence, which may be further reduced with added levatorplasty is best suited for patients who are too frail to tolerate general anaesthesia and even in fit patients with incarcerated prolapse. Hence, it's the individualised surgical procedure, which considers the fitness of the patient and the predominant pre-existent symptoms, which excels the

surgical approaches in the management of rectal prolapse with good short and long-term outcomes.

The right answer probably does not lie in a single operation, but in tailoring the most appropriate treatment to each individual patient.

REFERENCES

- [1] Hein JA, Wong WD. Rectal prolapse. In: Mazier WP, Levien, DH, Luchtefeld MA, et al, eds. *Surgery of the colon, rectum and anus*. Philadelphia: WB Saunders 1995:515.
- [2] Harmston C, Jones OM, Cunningham C, et al. The relationship between internal rectal prolapse and internal anal sphincter function. *Colorectal Dis* 2011;13(7):791-795.
- [3] Uhlig BE, Sullivan ES. The modified Delorme operation: its place in surgical treatment for massive rectal prolapse. *Dis Colon Rectum* 1979;22(8):513-521.
- [4] Murad-Regadas SM, Pinto RA. Treatment of rectal prolapse. *Seminars in Colon and Rectal Surgery* 2016;27(1):33-39.
- [5] Takesue Y, Yokoyama T, Murakami Y, et al. The effectiveness of perineal rectosigmoidectomy for the treatment of rectal prolapse. *Surg Today* 1999;29(3):290-293.
- [6] Safar B1, Vernava AM 3rd. Abdominal approaches for rectal prolapse. *Clin Colon Rectal Surg* 2008;21(2):94-99.
- [7] Bakshi G, Ranka S, Agarwal S, et al. Modified mesh rectopexy: a study. *J Postgrad Med* 2000;46(4):265-267.
- [8] Mehendale VG, Chaudhari NC, Shenoy SN, et al. Devadhar's operation for complete rectal prolapse: 25 years' experience. *Indian J Gastroenterol* 2005;24(1):9-11.
- [9] Purkayastha S, Tekkis P, Athanasiou T, et al. A comparison of open vs laparoscopic abdominal rectopexy for full-thickness rectal prolapse: a meta-analysis. *Dis Colon Rectum* 2005;48(10):1930-1940.
- [10] Solomon MJ, Young CJ, Eyere AA, et al. Randomised clinical trial of laparoscopic versus open abdominal rectopexy for rectal prolapse. *Br J Surg* 2002;89(1):35-39.
- [11] Gourgiotis S, Baratsis S. Rectal prolapse. *Int J Colorectal Dis* 2007;22(3):231-243.
- [12] Kuijpers HC. Treatment of complete rectal prolapse: to narrow, to wrap, to suspend, to fix, to encircle, to plicate or to resect? *World J Surg* 1992;16(5):826-830.
- [13] Samaranyake CB, Luo C, Plank AW, et al. Systematic review on ventral rectopexy for rectal prolapse and intussusception. *Colorectal Dis* 2010;12(6):504-512.
- [14] Varma M, Rafferty J, Buie WD, et al. Practice parameters practice parameters for the management of rectal prolapse. *Dis Colon Rectum* 2011;54(11):1339-1346.
- [15] Senapati A, Nicholls RJ, Thomson JP, et al. Results of Delorme's procedure for rectal prolapse. *Dis Colon Rectum* 1994;37(5):456-460.
- [16] Altomare DF, Binda G, Ganio E, et al. Long-term outcome of Altemeier's procedure for rectal prolapse. *Dis Colon Rectum* 2009;52(4):698-703.
- [17] Chun SW, Pikarsky AJ, You SY, et al. Perineal rectosigmoidectomy for rectal prolapse: role of levatorplasty. *Tech Coloproctol* 2004;8(1):3-8.
- [18] Berney CR. Complicated incarcerated rectal prolapse: a surgical challenge in an elderly patient on antiplatelet agents. *AMJ* 2010;10(3):691-693.
- [19] Voulimeneas I, Antonopoulos C, Alifierakis E, et al. Perineal rectosigmoidectomy for gangrenous rectal prolapse. *World J Gastroenterol* 2010;16(21):2689-2691.
- [20] Sayfan J, Pinho M, Alexander-Williams J, et al. Sutured posterior abdominal rectopexy with sigmoidectomy compared with Marlex rectopexy for rectal prolapse. *Br J Surg* 1990;77(2):143-145.
- [21] Carter AE. Retrosacral suture fixation for complete prolapse rectum in the elderly, the frail and the demented. *Br J Surg* 1983;70(9):522-523.
- [22] Senapati A, Gray RG, Middleton LJ, et al. PROSPER: a randomised comparison of surgical treatments for rectal prolapse. *Colorectal Dis* 2013;15(7):858-868.