

CEREBRAL INFARCTION IN A YOUNG FEMALE FOLLOWING SNAKE BITE

Rajesh Reddy Venkata Komatla¹, Nagendran C², Krishna Teja Boggarapu³

¹Post Graduate, Department of General Medicine, Mahadevappa Rampure Medical College, Kalaburagi, Karnataka.

²Post Graduate, Department of General Medicine, Mahadevappa Rampure Medical College, Kalaburagi, Karnataka.

³Resident, Department of General Medicine, Mahadevappa Rampure Medical College, Kalaburagi, Karnataka.

ABSTRACT

Cerebral complications, particularly ischaemic infarcts after snake bites are rare.

Multiple mechanisms are involved in cerebral infarction following snake envenomation. Possible mechanisms include: (1) Anticoagulant and procoagulant effects of snake venom leading to microthrombi, (2) Direct cardiotoxic effects of venom causing dysrhythmias, leading to cardiac thromboembolism and (3) Severe vascular spasm, hypotension and hyperviscosity caused by hypovolaemia. We report a case of a 35-year-old female patient who presented to our casualty with history of snake bite. Following which, she developed bleeding from puncture site with deranged PT INR and anti-snake venom was given. The following day, patient developed right-sided monoplegia with Broca's aphasia and repeat PT INR came back normal. Imaging showed an ischaemic infarct in left middle cerebral artery territory. Patient was treated accordingly and discharged with residual deficit after a week. Patient is under followup and doing well.

KEYWORDS

Snake Bite, Female, Young, Cerebral Infraction.

HOW TO CITE THIS ARTICLE: Komatla RRV, Nagendran C, Boggarapu KT. Cerebral infarction in a young female following snake bite. J. Evid. Based Med. Healthc. 2016; 3(51), 2647-2648. DOI: 10.18410/jebmh/2016/580

INTRODUCTION: In India, more than 20,00,000 snake bites are reported annually, of which 35,000 to 50,000 victims ultimately die.^[1] Russell's viper, *Vipera russelli siamensis*, is the leading cause of fatal snake bite in India.^[2] Common clinical manifestations are local cellulitis, renal failure, and haemorrhagic manifestations including pituitary and intracranial haemorrhage. Cerebral infarction following Russell's viper bite is an unusual complication.

CASE REPORT: A 35-year-old female patient presented to our emergency department with history of snake bite on her right foot associated with severe local pain. Local examination showed two deep fang marks, oedema and erythema. Neurological examination at the time of admission was normal.

Treatment was immediately started with polyvalent anti-snake venom (ASV) after a test dose laboratory data showed: Mild leucocytosis, microscopic haematuria, prolonged bleeding time (5.00 min) and clotting time (12.00 min), prolonged prothrombin time (3 min; control 16 sec) and activated plasma thromboplastin time (180 sec; control 36 sec). Clotting time was corrected in about 24 hours. Prothrombin time and activated plasma thromboplastin time were normalised by fourth day. Meanwhile, on the second day of admission, patient developed sudden right upper limb weakness and speech disturbances. Neurological examination revealed right monoplegia and expressive aphasia.

Brain computed tomography (CT) scan and magnetic resonance imaging (MRI) showed acute ischaemic infarct in the left middle cerebral artery (MCA) territory. Magnetic resonance angiography of the cerebral circulation revealed no abnormalities. Colour Doppler study showed no arterial or venous thrombosis in the lower limbs. Workup for other stroke risk profiles like electrocardiogram (ECG), lipid profile including lipoprotein (a), serum homocysteine, proteins C and S, and antithrombin III, carotid Doppler and 2D echocardiography were normal. Patient was treated accordingly and she showed improvement in the motor power and speech at the time of discharge on the tenth day.

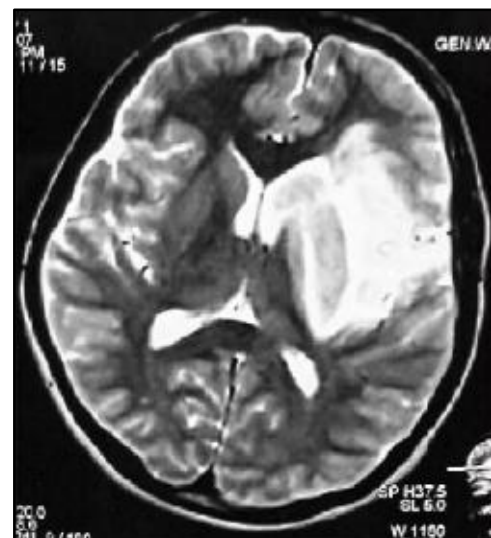


Fig. 1: MRI Brain showing Acute Infarct in Left Middle Cerebral Artery Territory

DISCUSSION: Cerebral complications, in particular ischaemic complications, after a snake bite are rare. Only very few case reports of cerebrovascular complications following viper bite have been reported,^{[3],[4],[5]} majority of which are haemorrhagic strokes.^[3]

Financial or Other, Competing Interest: None.

Submission 02-06-2016, Peer Review 15-06-2016,

Acceptance 22-06-2016, Published 27-06-2016.

Corresponding Author:

Dr. Rajesh Reddy Venkata Komatla,

#G6 Amulya Towers, Saibaba Road, Chandramouli Nagar,
Guntur-7, Andhra Pradesh.

E-mail: raajeshkomatla@gmail.com

DOI: 10.18410/jebmh/2016/580

Our patient developed right monoplegia, expressive aphasia with left MCA territory infarct. Bashir and Jinkins reported one such case of a patient in whom envenomation with Russell's viper resulted in hemiplegia and aphasia, consistent with a middle cerebral artery infarction.^[4] Viper snake venom is a complex toxin with dominant effects on haemostatic mechanisms, which in large doses may cause massive intravascular coagulation resulting in cerebral infarction.

Possible Thrombotic Mechanisms Include:

1. Direct action of the venom on vascular endothelial cells.^[4]
2. Toxic vasculitis caused by certain Viperinae species.^[5]
3. Hemorrhagins, the complement mediated toxic components of Viperidae snake venom resulting in severe vascular spasm, endothelial damage, and increased vascular permeability.^[4] leading to vascular occlusion.^[5]
4. Hypercoagulation caused by procoagulants in the venom, such as arginine, esterase, and hydrolase.^{[4],[5]}
5. Hyperviscosity caused by hypovolaemia and hypoperfusion secondary to hypotension.

In some cases, the cerebral infarction may be totally unrelated and may be the manifestation of an inherent deficiency of protein C, protein S, and antithrombin III.^[6] In our present case, patient was young, had no vascular risk factor and MR angiography was normal. We feel that the possible mechanism for the cerebral infarction in our patient was toxic vasculitis or toxin-induced vascular spasm and endothelial damage. Studies showed better outcomes with immediate ASV treatment. In a study, on victims with envenomation by *Bothrops lanceolatus* by Thomas et al. of the 70 patients who received ASV within 6 hours none developed thrombotic complications; whereas of the 33 patients had not received ASV or received ASV after 8 hours

of envenomation, 14% developed thrombotic complications and 4 of the 14 patients who had not received ASV died.^[7]

Contrary to the aforementioned study, our patient despite adequate treatment with ASV within 1 hour of envenomation developed delayed cerebral infarction on the second day.

CONCLUSION: To conclude, one should work up for possible cerebral infarction in a victim of viper envenomation and focal deficit. Our case also illustrates the need to watch for possible thrombotic complications following snake bite, even in patients who are treated immediately with adequate ASV.

REFERENCES

1. David AW. Guidelines for the clinical management of snake-bites in the south-east Asia region. Asia, New Delhi: World Health Organization, Regional Office for South East 2005:1-67.
2. Warrell DA. Snake venoms in science and clinical medicine. 1. Russell's viper: biology, venom and treatment of bites. *Trans R Soc Trop Med Hyg* 1989;83(6):732-740.
3. Mosquera A, Idrovo LA, Tafur A, et al. Stroke following *Bothrops* spp. snakebite. *Neurology* 2003;60:1577-1580.
4. Bashir R, Jinkins J. Cerebral infarction in a young female following snake bite. *Stroke* 1985;16(2):328-330.
5. Murthy JM, Kishore LT, Naidu KS. Cerebral infarction after envenomation by viper. *J Comput Assist Tomogr* 1997;21(1):35-37.
6. Kumar V, Cortan RS, Robbins SL. Basic pathology. 5th edn. Bangalore: Prism books PVT 1992:69-70.
7. Thomas L, Tyburn B, Ketterlé J, et al. Prognostic significance of clinical grading of patients envenomed by *Bothrops lanceolatus* in Martinique. *Trans R Soc Trop Med Hyg* 1998;92:542-545.