

CALCAR PRESERVING OSTEOTOMY IN CEMENTED BIPOLAR HEMIARTHROPLASTY FOR UNSTABLE TROCHANTERIC FRACTURES

Mohammed Ashraf¹, Jayachandran N², Jinumon Mathew³, Rajeev K. S⁴

¹Professor & HOD, Department of Orthopaedics, Government T.D. Medical College, Alleppey, Kerala, India.

²Assistant Professor, Department of Orthopaedics, Government T.D. Medical College, Alleppey, Kerala, India.

³Senior Resident, Department of Orthopaedics, Government T.D. Medical College, Alleppey, Kerala, India.

⁴Junior Resident, Department of Orthopaedics, Government T.D. Medical College, Alleppey, Kerala, India.

ABSTRACT

INTRODUCTION

Intertrochanteric fractures in osteoporotic bones which are grossly comminuted are highly unstable and difficult to treat. Conservative treatment with traction and prolonged immobilisation lands up with many complications and often fatality. Rate of failure with internal fixation has been found to be high, especially in osteoporotic bones. Revision osteosynthesis is technically demanding and it leads to complications, a second surgical procedure for revision synthesis, arthroplasty or removal of a symptomatic implant is again a risky procedure in elderly patients with lot of comorbidities. The aim of this study was to assess the efficacy of a cemented bipolar hemiarthroplasty with calcar preserving intracapsular osteotomy in the management of unstable trochanteric fractures in elderly patients with osteoporosis.

Hemiarthroplasty in unstable trochanteric fractures have been described in the past with varying outcome. The reasons for poor outcome were shortening, varus positioning and abductor insufficiency. This was mainly due to the deficient medial support due to the removal of lesser trochanter and calcar.

Recently, free calcar grafting excised from the removed neck for medial support was reported, but in our technique we are preserving the calcar and lesser trochanter with all its soft tissue and muscle attachments.

MATERIALS AND METHODS

52 patients with mean age 71.4 (range from 65 to 89) who underwent cemented bipolar hemiarthroplasty with calcar preserving osteotomy for unstable intertrochanteric fractures were prospectively evaluated. Posterior approach was used in all patients. Harris hip score was used for the clinical evaluation. The mean followup period was 5 years.

RESULT

In our study, which was done on 52 cases which had a mean age 71.4 years. The average Harris hip score was 81. Excellent to fair results were obtained at followup in 50 (96%) cases, and in 2(4%) cases the results were poor. Average hospital stay was 14 days. There were 2 cases of a superficial operative site infection and aseptic sinus formation, 2 cases with abductor deficiency, Trendelenburg gait and anterior thigh pain. There was no case with loosening of the prosthesis, dislocation, break in the cement or sinking of the prosthesis.

CONCLUSION

The gold standard of treatment of intertrochanteric fractures in young patients is osteosynthesis. But the treatment of unstable intertrochanteric fractures in elderly patients with severe osteoporosis differs from the treatment of patients with other proximal femoral fractures. These fractures are better treated with cemented hemiarthroplasty than with internal fixation. Besides an early ambulation and less hospital stay, cemented bipolar hemiarthroplasty provides stable and mobile hips. Weight bearing can be started earlier than in other methods of treatment, which prevents any recumbency related complications

KEYWORDS

Trochanteric fractures, Bipolar Hemiarthroplasty, Calcar Preservation, Proximal femoral nail, Hip screw.

HOW TO CITE THIS ARTICLE: Ashraf MM, Jayachandran N, Mathew J, et al. Calcar preserving osteotomy in cemented bipolar hemiarthroplasty for unstable trochanteric fractures. J. Evid. Based Med. Healthc. 2016; 3(31), 1414-1421.

DOI: 10.18410/jebmh/2016/324

INTRODUCTION: Intertrochanteric fractures are major cause of disability and death in elderly world over. The

Financial or Other, Competing Interest: None.

Submission 24-03-2016, Peer Review 04-04-2016,

Acceptance 16-04-2016, Published 18-04-2016.

Corresponding Author:

Dr. Mohammed Ashraf,

Orthopaedic Surgeon, Jannath, Evangelical Church Road,

M. O. Ward, Alleppey-688001

E-mail: drashraf369@yahoo.com

DOI: 10.18410/jebmh/2016/324

incidence of all hip fractures is approximately 80 per 100,000 persons and is expected to double over the next 50 years as the population ages. Intertrochanteric fractures make up 45% of all hip fractures.^{1,2,3,4,5}

Intertrochanteric fractures in osteoporotic bones which are grossly comminuted are highly unstable and difficult to treat.^{6,7} Conservative treatment with traction and prolonged immobilisation lands up with many complications and often fatality. Rate of failure with internal fixation has been found

to be high, especially in osteoporotic bones. Re-operation rates are up to 11% in PFN and 28% in DHS. Articular penetration and distal shaft fracture by the screws are also common. Osteosynthesis needs 2nd operation for revision,⁸ removal or arthroplasty. Revision osteosynthesis is technically demanding and it leads to complications.^{9,10,11,12,13,14,15} The aim of this study was to assess the efficacy of cemented bipolar hemiarthroplasty with calcar preserving osteotomy in the management of unstable intertrochanteric fractures in elderly patients.

Unstable osteoporotic intertrochanteric femur fractures of elderly patients are associated with high rates of morbidity and mortality due to the need for prolonged immobilisation, implant related complications and need for second operation.

These old age patients generally have many associated diseases like diabetes mellitus, hypertension, etc. In these patients due to combination of osteoporosis and instability, early resumption to full weight bearing is difficult even after so called stable fixation. Hence because of prolonged immobilisation, complications like deep vein thrombosis, hypostatic pneumonia, pressure sores, dehydration, atelectasis, metabolic disturbances, etc. are likely.

Stable fractures can be easily treated with osteosynthesis with predictable results. However, the management of unstable intertrochanteric (Evans type III or IV and AO/OTA type 31-A2.2 and 2.3) fractures in elderly patients is a challenge because of difficulty in obtaining anatomical reduction, retention of reduction and associated high rates of morbidity and mortality. In osteosynthesis of the comminuted intertrochanteric fractures, fixation of all fragments are neither possible nor feasible. The posteromedial fragments are generally present which makes the fracture very unstable.

Conventional cemented bipolar arthroplasty rather than internal fixation could perhaps return these patients to their pre-injury level of activity more quickly, thus obviating the postoperative complications caused by immobilisation or failure of the implant. There are many published reports in the past on this technique.^{16,17,8,18,19} Suboptimal outcome in these studies is due to removal of the supporting posteromedial comminuted area along with the head and neck and filling the void with cement. Complications like implant subsidence, varus positioning, abductor insufficiency, limb shortening, etc. are very common. Moreover preoperative technical complications like limb length and version assessment, tissue trauma and blood loss and a difficult THR later have also been reported.

We are describing a simple and successfully practiced technique to retain the lesser trochanter-calcar complex thereby reducing the chance of all the possible preoperative and postoperative reported complications.

MATERIALS AND METHODS:

Study Design: Prospective study.

Study Period: 5 years (2011-2015).

Study Setting: Department of Orthopaedics, Govt. Medical College, Alleppey, Kerala, India.

Study Sample: Patients above 65 years with unstable intertrochanteric fractures were classified according to AO/OTA classification.

Exclusion Criteria: Stable trochanteric fractures, pathological fractures, spastic patients, non-ambulatory patients. Patients with life threatening comorbid conditions also excluded.

Methods of collection of data: After proper history taking, clinical examination and radiological workup, patients with an unstable intertrochanteric fracture are selected. They are treated with cemented bipolar hemiarthroplasty with calcar preserving osteotomy and followed up at 1 week, 1 month, 3 months, and 6 months and evaluation was done using Harris Hip Score (HHS).⁵

Study Procedure: Clinically and radiologically diagnosed unstable intertrochanteric fractures were admitted and prepared for anaesthesia and surgery after proper consent. Patient will be put on non-adhesive skin traction and admitted in ward. Special care will be taken to prevent bed sore, hypostatic pneumonia, metabolic encephalopathy and venous thrombosis. After pre-anaesthetic checkup and anaesthesia fitness, all the patients were treated with cemented bipolar hemiarthroplasty with calcar preservation as early as possible usually within 4-7 days under regional anaesthesia. Then patient is discharged within one week by completing the course of antibiotics and wound inspection. Sutures were removed on 14th day. Then patient is followed up on 1 month, 3 months and 6 months and yearly thereafter and hip function is assessed on each visit. The results are evaluated with the help of criteria suggested by Harris hip score considering following factors: Pain, support, walked distance, sitting, using public transportation, stairs, put on shoes and socks, absence of deformity, range of motion.

52 cases of unstable intertrochanteric fractures treated with hemiarthroplasty in this institution between 2011 and 2015 were studied prospectively. There were 40 females and 12 males. All patients were above the age of 65 years (range 65-89 years). The fractures were classified according to AO/OTA and Evans classification. Only AO/OTA type 31-A2.2 and 31-A2.3 and Evans type III or IV fractures were included in this study.

Operative Technique-Calcar Preserving Osteotomy:

All cases were operated by using a standard Moore's posterior approach in lateral position by the senior author. Procedure was done under regional anaesthesia.

Care should be taken not to rotate the limb too much externally to prevent the opening up of trochanteric fracture surface. Trochanter may be secured temporarily to the shaft with Ethibond or steel wire to prevent further displacement. Short rotators and capsule divided as usual for hemiarthroplasty. Neck of femur is exposed and a cut was taken in the neck with a saw or osteotome approximately 1 cm above lesser trochanter. Now essentially the trochanteric fracture is converted to into an intracapsular fracture.

Femoral head is removed and measured. Now all the fragments are held together by the enveloping soft tissue alone or aided by the Ethibond or steel wire.

In 16 cases, the greater trochanter was the fracture en masse and was reattached to the main shaft using steel wires. In 8 cases where the greater trochanter was coronally split, a tension band was applied beneath the gluteus medius tendon and a bony tunnel was drilled in the distal greater trochanter. In 7 cases, the greater trochanter was found to be severely comminuted; here Ethibond sutures were used to suture together the trochanter pieces and the soft tissue to make a stable construct. In 21 cases, fragments were holding together by the intact gluteal musculature and adjacent soft tissue. The lesser trochanter pieces were left attached to the strong capsulomuscular attachments.

Femoral canal was broached with appropriate anteversion. Assessment of version and limb length will not be a problem in most of the cases since lesser trochanter-calcus complex is in position though fractured. A fixed bipolar prosthesis was then inserted and trial reduction was done. With the trial prosthesis in situ, traction was applied to the leg and compared with the opposite leg for limb length equality.

After confirming the leg length and anteversion, cemented implant was inserted into the femur and joint was reduced. Since all the fragments are preserved, shortening is not a problem but anteversion assessment must be done carefully by referencing femoral bicondylar plane. After checking stability, wound was closed in layers including short rotators over suction drain.

The patients were allowed to sit within 24 hours. We encouraged the patients to sit, stand and supervised assisted partial weight bearing after 48 hours. Walking with walking frame started on 3rd postop day in most of the cases. In minority of cases, ambulation was delayed due to pain or lack of patient motivation.

Patients were examined postoperatively at 1 month, 3 months, 6 months, 1 year, and thereafter annually. At each followup visit, a clinicoradiological examination was done and the patient was evaluated using the Harris hip score (HHS) and were graded as <70 poor, 70-79 Fair, 80-89 Good and 90-100 Excellent. Clinical and radiographic assessment of the hip were analysed at each followup to note evidence of loosening.

RESULTS: In our study which was done on 52 cases which had a mean age 71.4 years, the average Harris hip score was 82. Excellent to fair results were obtained at followup in 50 (96%) cases, and in 2(4%) cases the results were poor. Average hospital stay was 14 [pre and postop] days. There were 2 cases of a superficial surgical site infection and aseptic sinus formation which were promptly treated with proper antibiotics, 2 cases with abductor deficiency and Trendelenburg gait. These patients had 1 cm shortening and varus positioning of the prosthesis, 2 cases with anterior thigh pain. There was no case with loosening or dislocation of the prosthesis.

One patient lost to followup after 3 months.

The patients started full weight bearing at an average 7 days after surgery. The average stay in the hospital was 14 days.

DISCUSSION: Intertrochanteric fractures in the elderly pose certain special problems related to the bone quality, fracture geometry and associated comorbidities. In this age group, the fracture configuration is generally comminuted with presence of extensive osteoporosis.²⁰ There is a problem of correct and accurate placement of the implant and hold of the implant hence prolonged immobilisation is required for achieving complete union. There is a possibility of failure of either fracture union or implant construct shortening, varus-external rotation deformity, implant failure, articular screw penetration and screw related shaft fractures⁷ are common complications of DHS and PFN.^{6,21,22,23} The need for a second operation ranges from 11 to 28% after osteosynthesis.^{24,25,26,27} These poor results prompted frequent modification of implants for osteosynthesis and the best is yet to come.²⁸ On the other hand, there is a need for rapid full weight bearing mobilisation of this group of patients as they are generally medically compromised due to age and associated diseases. In addition, these patients may not have adequate psychomotor skills required for graded and protected weight bearing which is needed after internal fixation. Hence there are two conflicting requirements that need to be addressed to in a balanced way. So, till date, the treatment of unstable intertrochanteric femur fractures in osteoporotic elderly patients is still controversial. Extensive literature is available in forms of randomised trials and comparative studies.

Conventional cemented hemiarthroplasty has been described and practiced with variable outcome in many centres.^{27,29,16,8,30} Complications like technical difficulty, blood loss,^{17,14} shortening, varus positioning, abductor insufficiency, implant subsidence and dislocation have been reported. This is due to the deficient medial support due to removal of lesser trochanter and calcar.

Haentjens et al³⁰ reported 37 cases with 2 dislocations one periprosthetic fracture.

Stern and Goldstein³¹ reported 29 patients with 2 cases of implant subsidence and pain.

Rodop et al series had 5 cases of limb length discrepancy out of 54 cases.

Zhang et al¹⁴ reported 19 cases of prosthetic replacement out of which 3 cases are dislocated.

In our series, since we are preserving the LT –calcar complex, no patient had dislocation or significant limb length discrepancy.

Calcar reconstruction has been attempted by cement, but with possible subsidence and failure.

Another option described is calcar prosthesis (Leinbach prosthesis).³¹ Both the above procedures are technically difficult and associated with more bone removal and blood loss. Moreover, revision will be technically difficult.

Recently C.J Thakkar et al³² described calcar grafting where whole head, neck, lesser trochanter and calcar was removed en block. Then, calcar excised and put back as free

graft. But failure chances are high due to graft absorption, subsidence, nonunion and displacement.

CALCAR PRESERVING OSTEOTOMY: All the limitations of conventional hemiarthroplasty, calcar prosthesis and calcar grafting are avoided by this simple and easily reproducible technic. By this osteotomy, we are essentially converting an extracapsular fracture into an intracapsular fracture.

The preserved vascular, live and viable calcar will unite with the shaft early. Till that time it will be held by the cemented prosthesis. This will avoid the complications of a free cortical hard calcar graft with the possibility of absorption, nonunion and graft subsidence apart from the technical difficulty of calcar graft procurement.

In conventional cemented hemiarthroplasty, calcar is reconstructed by the cement which may break or subside on weight bearing. This is also prevented by our procedure.

When compared to calcar prosthesis which is technically difficult, expensive and needs special inventory, our described procedure is inexpensive and simple.

Early mobilisation is possible and the technique provides immediate stability and mobility thereby avoiding the problems of recumbency. Surgical time and required skills are at par with the standard hemiarthroplasty, early weight bearing is possible, so morbidity of immobilisation can be decreased. Preserved lesser trochanter and calcar incorporate early with the shaft. There were no cases of pressure sores, pneumonia or any respiratory complications postoperatively. None of the patients developed deep venous thrombosis (DVT).

CONCLUSION: Thus, in conclusion, primary cemented bipolar hemiarthroplasty with calcar preserving osteotomy does provide a stable, pain-free, and mobile joint with the possibility of early ambulation so as to prevent the morbidity and mortality of elderly bedridden patients.

Though our observation provides promising result, a larger prospective randomised multicentric study on primary cemented hemiarthroplasty with calcar preserving osteotomy for unstable osteoporotic trochanteric fractures will be needed. Primary cemented calcar preserving bipolar hemiarthroplasty may be used as a better alternative treatment for unstable osteoporotic intertrochanteric fractures in elderly patients for early ambulation and good functional results.

Functional Outcome:

Time period	Average Harris Hip Score
6 weeks	58
3 months	75
6 months	84
12 months	90

Table 1: Post op Harris Hip Score on followup

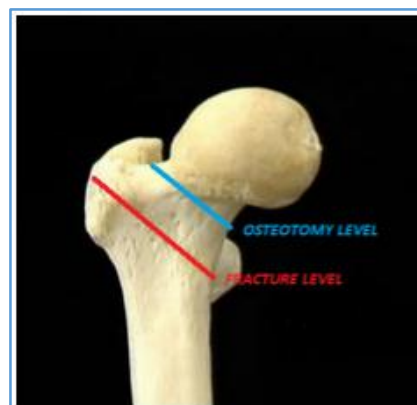


Fig. 1: Bone model showing level of fracture in red and level of calcar preserving osteotomy in blue

Conventional Bipolar	Calcar preserving osteotomy
More bone removed	Calcar preserved
More blood loss	Less tissue trauma
Limb length problem	Length maintained
Version assessment difficult	Easy
Varus and subsidence common	Less common
Revision is difficult	More bone preserved
Abductor dysfunction is more	No or minimal

Table 2: Comparison of conventional and calcar preserving hemiarthroplasty

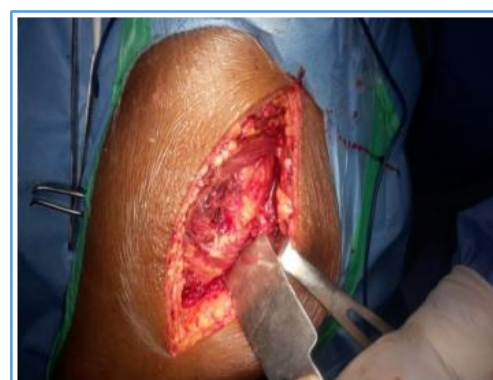

Fig. 2: Posterior approach

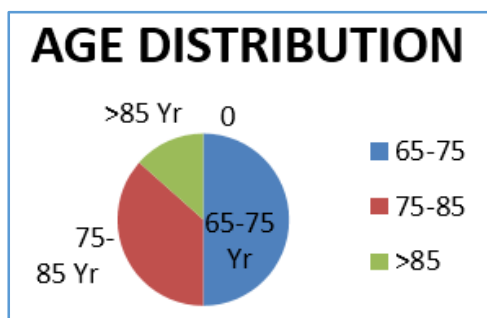


Chart 1: Age distribution

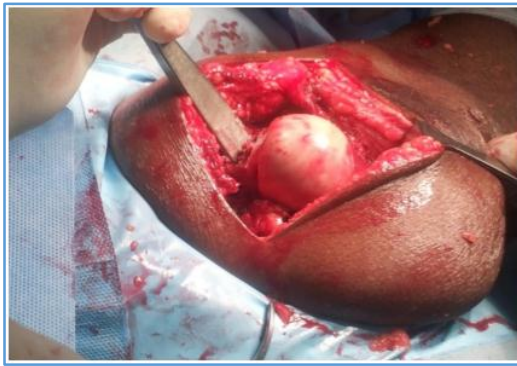

Fig. 3: Calcar preserving osteotomy

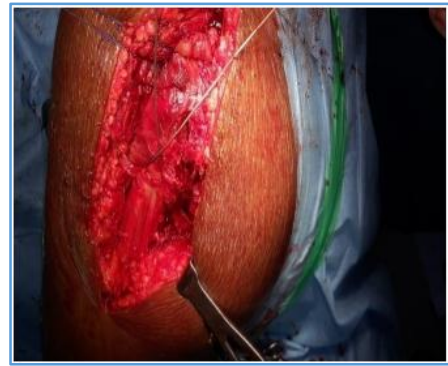

Fig. 7: Greater Trochanter reconstruction using steel wire

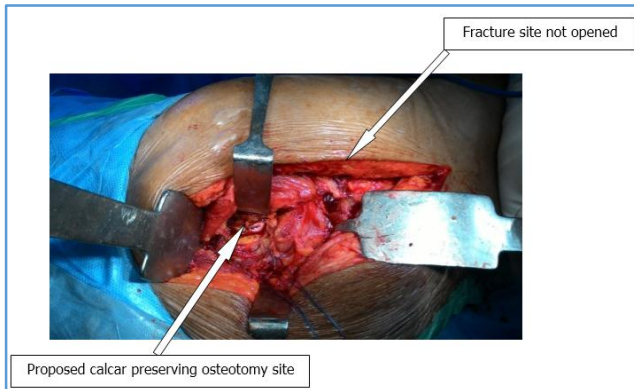


Fig. 4: Division of capsule and lateral rotators

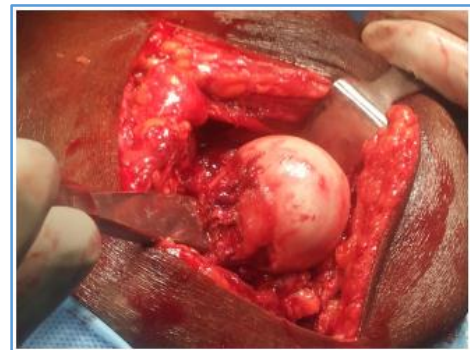

Fig. 8: Calcar preserving osteotomy at trans-cervical level

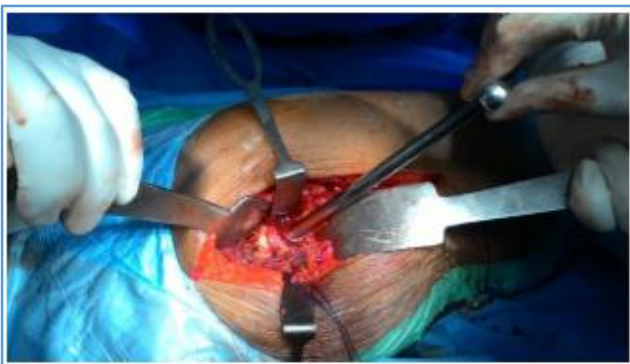

Fig. 5: Extraction of head with corkscrew extractor

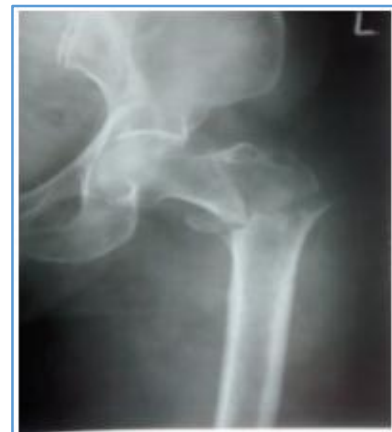

Fig. 9: Preop x-ray of unstable trochanteric fracture in a 72-year-old lady

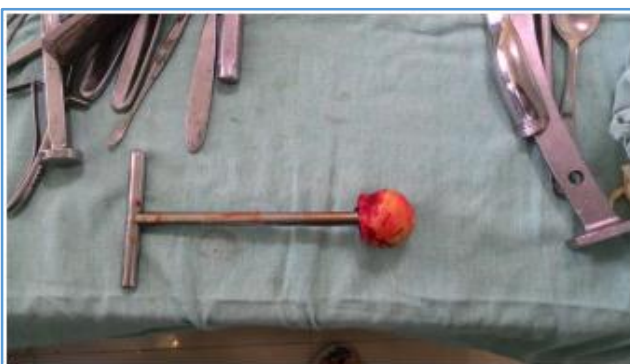


Fig. 6: Extracted head after calcar preserving osteotomy

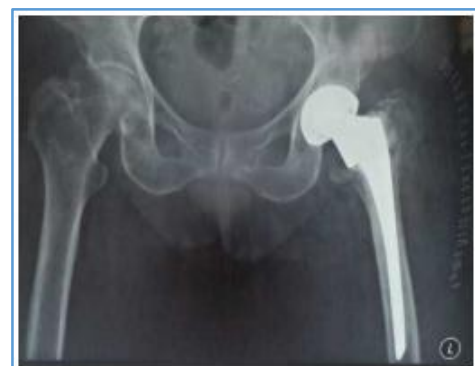

Fig. 10: Postop x-ray after calcar preserving cemented bipolar hemiarthroplasty

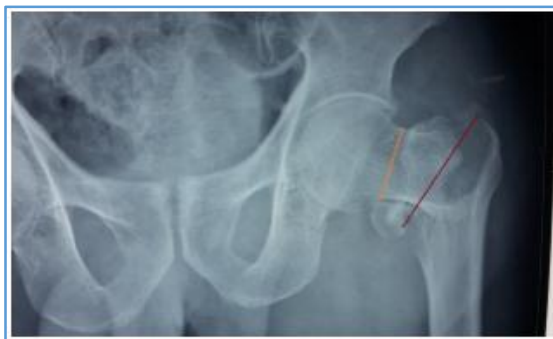

Fig. 11: Level of osteotomy in yellow, level of fracture in red

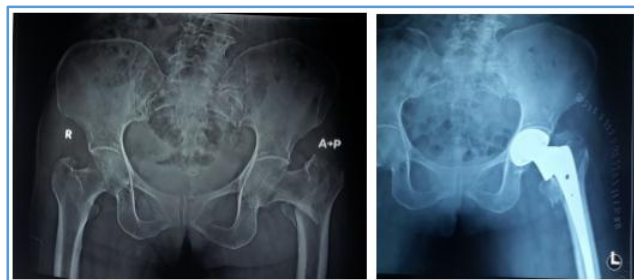


Fig. 15: Unstable trochanteric fracture preoperative and postoperative x-ray following hemiarthroplasty with calcar preserving osteotomy

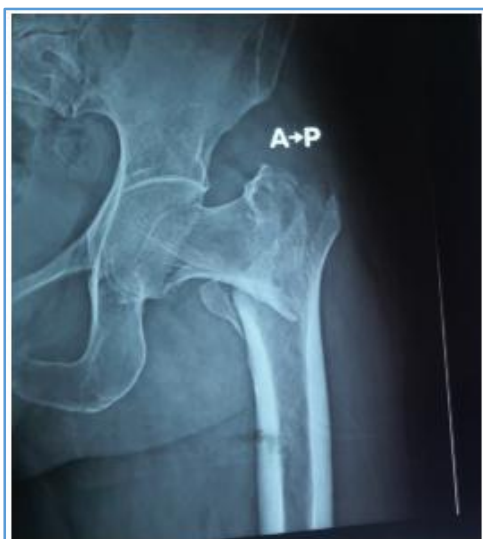

Fig. 12: Unstable trochanteric fracture with lateral wall comminution

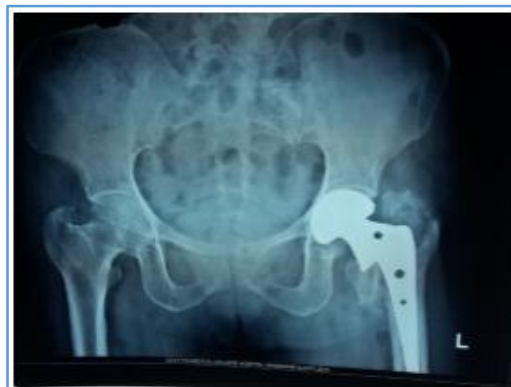

Fig. 16: Unstable trochanteric fracture treated with calcar preserving cemented bipolar hemiarthroplasty

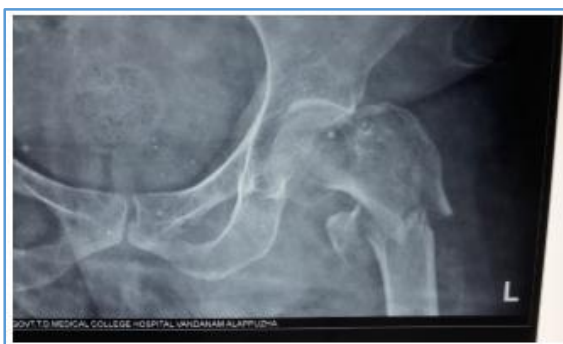

Fig. 13: Osteoporotic comminuted unstable trochanteric fracture

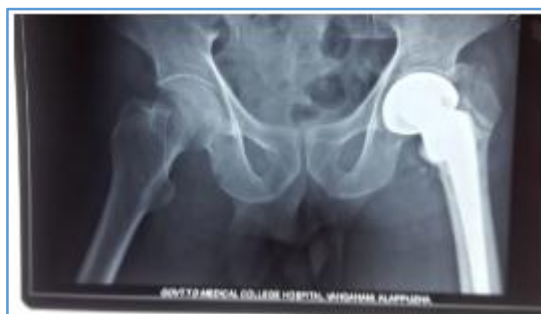

Fig. 17: Unstable trochanteric fracture treated with calcar preserving cemented bipolar hemiarthroplasty

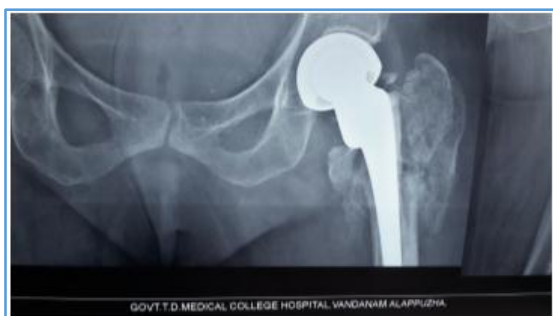

Fig. 14: Post-operative early medial callus formation

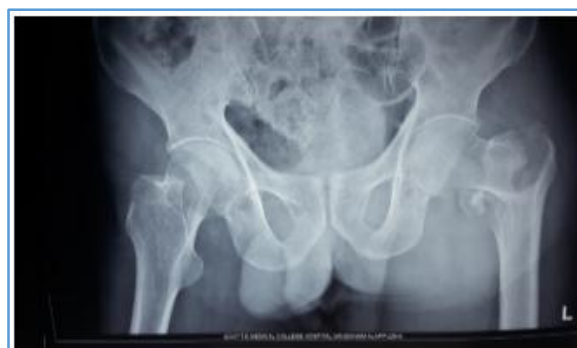

Fig. 18: Unstable Intertrochanteric fracture

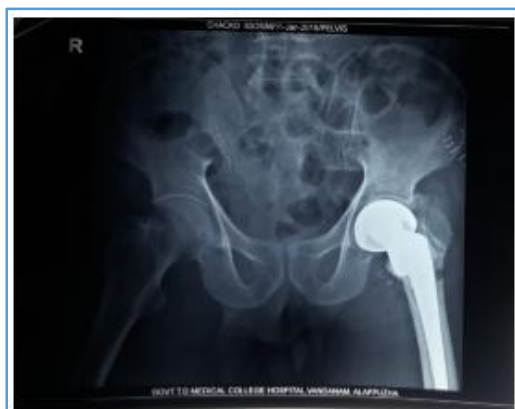

Fig. 19: Unstable trochanteric fracture treated with calcar preserving cemented bipolar hemiarthroplasty

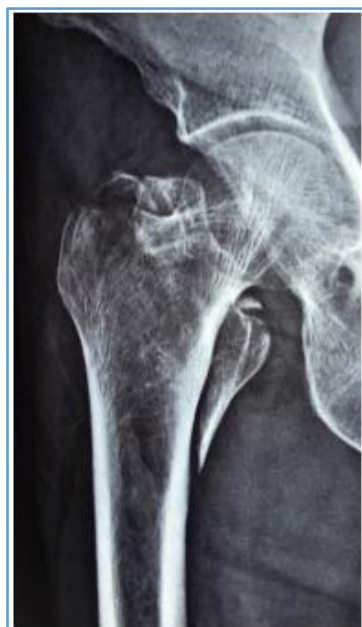

Fig. 20: Unstable trochanteric fracture preoperative x-ray

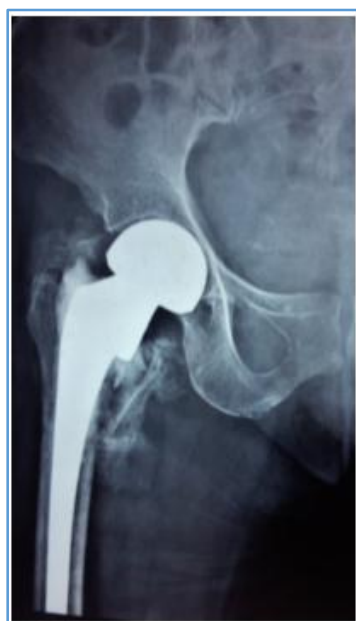

Fig. 21: Early medial callus formation following calcar preserving osteotomy. 8 weeks postoperative

Post-operative hip movement range	Range
Flexion	95-110
Abduction	15-25
Adduction	13-20
External rotation	15-25

Table 3

REFERENCES:

1. Koval KJ, Zuckerman JD. Hip fractures are an increasingly important public health problem. Clin Orthop Relat Res 1998;348(2).
2. Rockwood PR, Horne JG, Cryer C. Hip fractures: a future epidemic? J Orthop Trauma 1990;4(4):388-393.
3. Hedlund R, Lindgren U. Trauma type, age, and gender as determinants of hip fracture. J Orthop Res 1987;5(2):242-246.
4. Bergström U, Björnstig U, Stenlund H, et al. Fracture mechanisms and fracture pattern in men and women aged 50 years and older: a study of a 12-year population-based injury register. Osteoporos Int 2008;19(9):1267-1273.
5. Harris WH. Arthritis hip treated by mold arthroplasty. An end result survey using a new method of result evaluation. J Bone Joint Surg Am 1969;51:737-755.
6. Steinber GG, Desai SS, Kornwicz NA, et al. The intertrochanteric hip fracture. A retrospective analysis. Orthopedics 1988;11(2):265-273.
7. Norris R, Bhattacharjee D, Parker MJ. Occurrence of secondary fracture around intramedullary nails used for trochanteric hip fractures: a systematic review of 13,568 patients. Injury 2012;43:706-711.
8. Chan KC, Gill GS. Cemented hemiarthroplasties for elderly patients with intertrochanteric fractures. Clin Orthop Relat Res 2000;371:206-215.
9. Moller BN, Lucht U, Grymer F, et al. Instability of trochanteric hip fractures following internal fixation: a radiographic comparison of the Richards sliding screw-plate and the McLaughlin nail-plate. Acta Orthop Scand 1984;55(5):517-520.
10. Flores LA, Harrington IJ, Martin H. The stability of intertrochanteric fractures treated with a sliding screw plate. J Bone Joint Surg Br 1990;72(1):37-40.
11. Sernbo I, Fredin H. Changing methods of hip fracture osteosynthesis in Sweden: an epidemiological enquiry covering 46,900 cases. Acta Orthop Scand 1993;64(2):173-174.
12. Larsson S, Friberg S, Hansson LI. Trochanteric fractures: Mobility, complications, and mortality in 607 cases treated with the sliding-screw plate. Clin Orthop Relat Res 1990;260:232-241.
13. Davis TR, Sher JL, Horsman A, et al. Intertrochanteric femoral fractures: mechanical failure after internal fixation. J Bone Joint Surg Br 1990;72(1):26-31.
14. Zhang B, Chiu KY, Wang M. Hip arthroplasty for failed internal fixation of intertrochanteric fractures. J Arthroplasty 2004;19(3):329-333.

15. Davis TR, Sher JL, Horsman A, et al. Intertrochanteric femoral fractures: mechanical failure after internal fixation. *J Bone Joint Surg Br* 1990;72(1):26-31.
16. Broos PL, Rommens PM, Deleyn PR, et al. Per trochanteric fractures in the elderly: are there indications for primary prosthetic replacement? *J Orthop Trauma* 1991;5(4):446-451.
17. Green S, Moore T, Proano F. Bipolar prosthetic replacement for the management of unstable intertrochanteric hip fractures in the elderly. *Clin Orthop Relat Res* 1987;224:169-177.
18. Gingras MB, Clarke J, Everts MC. Prosthetic replacement in femoral neck fractures. *Clin Orthop Relat Res* 1980;152:147-157.
19. Haidukewych GJ, Berry JB. Hip arthroplasty for salvage of failed treatment of intertrochanteric hip fractures. *J Bone Joint Surg Am* 2003;85A(5):899-904.
20. Singh M, Nagrath AR, Maini PS. Changes in trabecular pattern of the upper end of the femur as an index of osteoporosis. *J Bone Joint Surg Am* 1970;52(3):457-467.
21. Wolfgang GL, Bryant MH, O'Neill JP. Treatment of intertrochanteric fracture of the femur using sliding screw plate fixation. *Clin Orthop Relat Res* 1982;163:148-58.
22. Hsueh KK, Fang CK, Chen CM, et al. Risk factors in cut out of sliding hip screw in inter trochanteric fractures: an evaluation of 937 patients. *Int Orthop* 2010;34(8):1273-1276.
23. Bendo JA, Weiner LS, Strauss E, et al. Collapse of intertrochanteric hip fractures fixed with sliding screws. *Orthop Rev* 1994;Suppl:30-37.
24. Kaufer H, Matthews LS, Sonstegard D. Stable fixation of intertrochanteric fractures: a biomechanical evaluation. *J Bone Joint Surg Am* 1974;56(5):899-890.
25. Thomas AP. Dynamic hip screws that fail. *Injury* 1991;22(1):45-46.
26. Simpson AH, Varty K, Dodd CA. Sliding hip screws: modes of failure. *Injury* 1989;20(4):227-31.
27. Kim WY, Han CH, Park JI, et al. Failure of intertrochanteric fracture fixation with a dynamic hip screw in relation to pre-operative fracture stability and osteoporosis. *Int Orthop* 2001;25(6):360-362.
28. Parker MJ, Handoll HH. Gamma and other cephalocondylic intramedullary nails versus extramedullary implants for extracapsular hip fractures in adults. *Cochrane Database Syst Rev* 2010;8(9). CD000093; doi: 10.1002/14651858.CD000093.pub5.
29. Sinno K, Sakr M, Girard J, et al. The effectiveness of primary bipolar arthroplasty in treatment of unstable intertrochanteric fractures in elderly patients. *N Am J Med Sci* 2010;2(12):561-568.
30. Haentjens P, Casteleyn PP, De Boeck H, et al. Treatment of unstable intertrochanteric and subtrochanteric fractures in elderly patients. Primary bipolar arthroplasty compared with internal fixation. *J Bone Joint Surg Am* 1989;71(8):1214-1225.
31. Stern MB, Angerman A. Comminuted intertrochanteric fractures treated with a Leinbach prosthesis. *Clin Orthop Relat Res* 1987;218:75-80.
32. Thakkar CJ, Thakkar S. Calcar femoral grafting in the hemiarthroplasty of the hip for the unstable intertrochanteric fractures. *Indian J orthop* 2015;49(6):602-609.