

BREAST DISEASES, AN ISSUE DURING PREGNANCY AND LACTATION. OUR EXPERIENCE!

Prabhjit Kour¹, Sanjay Bhat², Kalyan Dutt³, Saurabh Sharma⁴, Saku⁵, Pallavi⁶

¹Assistant Professor, Department of Obstetrics & Gynaecology, ASCOMS & Hospital, Jammu.

²Consultant Medicine, Department of Medicine, ASCOMS & Hospital, Jammu.

³Professor, Department of Medicine, ASCOMS & Hospital, Jammu.

⁴Senior Resident, Department of Medicine, ASCOMS & Hospital, Jammu.

⁵Senior Resident, Department of Medicine, ASCOMS & Hospital, Jammu.

⁶Senior Resident, Department of Medicine, ASCOMS & Hospital, Jammu.

⁷Senior Resident, Department of Medicine, ASCOMS & Hospital, Jammu.

ABSTRACT**AIM OF THE STUDY**

To study the various breast conditions during pregnancy and lactation.

MATERIALS AND METHODS

This was a cross sectional descriptive study conducted at various nursing homes in Jammu region during the period of one year (2011–2012). All pregnant/Lactating women with breast related problems were enrolled for the study. A detailed clinical examination was carried out on the first visit and all relevant investigations were carried out.

RESULTS

Majority of cases were of infective etiology like mastitis (94.11%) out of which 60 were lactating and 20 were pregnant, they all got treated with antibiotics and analgesics. Antibiooma and abscesses was noted in 1% each, they were drained surgically. Galactocele was noted in one lactating female (1.16%). Only one patient (1.17%). was noted to have a mass lesion on clinical examination which proved to be malignant on FNAC.

CONCLUSION

Invariably, most breast disorders during pregnancy or lactation will ultimately prove to be benign. Nevertheless, the possibility of cancer should be kept in mind so as to intervene earliest possible without any risk to mother or fetus.

KEYWORDS

Pregnancy, Lactation, Breast diseases, Carcinoma.

HOW TO CITE THIS ARTICLE: Kour P, Bhat S, Dutt K, et al. Breast diseases, an issue during pregnancy and lactation. Our experience! J. Evid. Based Med. Healthc. 2016; 3(21), 927-930. DOI: 10.18410/jebmh/2016/210

INTRODUCTION: During pregnancy, the body changes its physiological and homeostatic mechanisms to ensure the normal foetal development. Levels of progesterone and oestrogens rise continually throughout pregnancy, suppressing the hypothalamic axis and subsequently the menstrual cycle. Likewise, mammary glands, the size and weight of which approximately doubles as glandular elements proliferate under hormonal stimulation. Both lobular and alveolar growth occur. Mammary blood flow doubles. Small amounts of colostrum are produced prior to delivery. After delivery, placental and ovarian hormonal inhibition of lactation is released, and prolactin stimulates galactopoietic. The mechanical stimulus of suckling allows lactation to continue virtually indefinitely. When nursing is stopped, milk stagnates and lactation ceases within 48 hours. Involution of the breasts follows.

During this course, the major problems encountered often are part of a spectrum of inflammatory and infectious complications or there may be some benign lesions-like, lactating adenoma, galactocele, gigantomastia, and benign bloody nipple discharge. Nevertheless, malignancy must be excluded by a thorough work-up.

Pregnancy-associated masses are usually discovered by patient, s self-examination, and the clinician should proceed to fine-needle aspiration or biopsy, rather than mammography, which has poor sensitivity during pregnancy and lactation because of increased breast density. Management of a new breast mass in pregnancy should maximize diagnostic accuracy and minimize the chances of missing PABC, yet avoid harm to the foetus or interruption of lactation.

STUDY DESIGN: This was a cross sectional descriptive study conducted at various nursing homes in Jammu region during the period of one year (2011–2012). All pregnant/Lactating women with breast related problems were enrolled for the study. A detailed clinical examination was carried out on the first visit and all relevant investigations were carried out. A total of 85 patients were seen during this period, out

Submission 12-02-2016, Peer Review 25-02-2016,
Acceptance 04-03-2016, Published 14-03-2016.

Corresponding Author:

Dr. Prabhjit Kour,

Department of Obstetrics & Gynaecology,
ASCOMS Hospital, Sidhra, Jammu-180017.

E-mail: drkalyandutt@gmail.com

DOI: 10.18410/jebmh/2016/210

of which 62 were lactating and 23 were pregnant. The age ranged from 20 to 38 years. The majority of cases were of infective aetiology like Mastitis (94.11%) out of which 60 were lactating and 20 were pregnant, they all got treated with antibiotics and analgesics. Antiboma and abscesses was noted in 1% each, they were drained surgically. Galactocele was noted in one lactating female (1.16%).

Only one patient (1.17%) was noted to have a mass lesion on clinical examination which proved to be malignant on FNAC. The patient was followed till delivery and later referred to an oncologist.

Data Analysis:

Column 1	No. of cases	Pregnancy	Lactation
Mastitis	80(94.11%)	20(86.95%)	60(96.77%)
Galactocele	2(2.35%)	0	1(1.61%)
Antibioma	1(1.17%)	1(4.34%)	0
Abscesses	1(1.17%)	1(4.34%)	1(1.61%)
Carcinoma	1(1.17%)	1(4.34%)	0
Total	85	23(27.05%)	62(72.94%)

TABLE 1

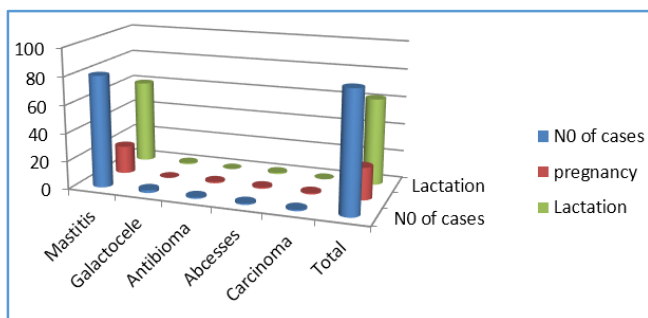


Figure 1

DISCUSSION: A pregnancy-related breast disorder is defined as a diagnosis made during pregnancy, within one year post-partum or during lactation.^[1,2] Clinical presentation as a palpable mass becomes a source of great anxiety for the woman and her family. The main differential diagnoses for palpable breast masses in pregnant or lactating women include: fibroadenoma, lactational adenoma, mastitis with or without abscess formation, antibioma, galactocele and normal breast tissue with lactational change. Invariably the lesions are infectious or inflammatory but clinical differential diagnosis should be kept wide open so as not to miss the malignancy.³

Infective Lesions:

Puerperal Mastitis/Abscess Disease: Puerperal mastitis occurs during pregnancy, lactation or weaning but is rare during pregnancy. A breast abscess is a localised collection of pus within the breast. It often forms as a complication of mastitis, however, it is estimated that only approximately 5-11% of lactating women with infectious mastitis will develop breast abscess.^[4,5]

The clinical presentation of a breast abscess is similar to that of mastitis. It tends to present with fever and

malaise, focal painful inflammation of the breast, and with a tender, palpable, fluctuant mass.

The primary organisms responsible for infection are staphylococcus aureus, followed by streptococcus. These organisms originate from the feeding infant’s nose/throat and enter via epithelial disruption of the nipple or surrounding areola. The presence of stagnant milk is important as it provides a culture medium for these bacteria. Ultrasound is used to investigate whether abscess formation has occurred, and for image-guided abscess drainage. Malignancy must be ruled out with tissue sampling if a patient’s condition does not improve with antibiotic therapy. The earlier classification of sporadic (endemic) versus epidemic mastitis is still used but has given way to a recognition that these infections form a spectrum of illnesses, depending upon the virulence of the infecting organism and the degree of bacterial colonization of the milk. Epidemic mastitis is a hospital-acquired infection caused by virulent strains of Staphylococcus aureus.^[5] This infection is rare, and it usually occurs within 4 days of delivery. Even with prompt antibiotic therapy, progression to abscess formation may occur. In contrast, non-epidemic or sporadic mastitis is a milder infection with less virulent organisms and generally responds well to treatment without hospitalization may be required, however, if the infection fails to respond.^[5,6]

Keeping the breast empty of milk promotes healing by helping to drain the culture medium that facilitates growth of organisms. Hence, the earlier recommendation that breast-feeding should be stopped while mastitis is being treated have been superseded by the knowledge that breast-feeding is generally not harmful to the infant-when using appropriate antibiotics-and may speed resolution of the infectious process. Milk leukocyte counts and cultures guide antibiotic therapy selection and help in gauging the severity of the infection and progress of treatment. Even when frank abscess formation occurs, serial aspirations may be a useful alternative to surgical drainage in selected cases.^[6] When an abscess is drained surgically, it is important to break down loculations and to biopsy the wall of the cavity to exclude the rare case of carcinoma masquerading as an abscess. General anaesthesia is usually required. Treatment failure may be indicated by persistence or progression of symptoms, often followed by impaired lactation.

Benign Lesions of Pregnancy: Benign breast lesions most likely to develop in pregnant women include lactating adenomas, breast infarcts, and gigantomastia. In addition, benign lesions that are commonly found in women in general-for example, fibroadenoma, breast hamartoma, and axillary breast tissue-may increase in size during pregnancy.

Lactating Adenomas: Also termed lactating nodules or nodular lactational hyperplasia, lactating adenomas are discrete, round, well-demarcated masses unique to pregnancy. Despite the name, lactating adenomas are more common during pregnancy than during lactation.

Consequently, the alternative term "breast tumour of pregnancy" has been suggested.^[7,8] Lactating adenomas typically present as painless, often rather sizable, palpable masses. The most common location is the breast periphery, often in the upper outer quadrant (where the bulk of breast tissue is distributed). The histology is characteristic; lobulated masses of acini or lobules are densely packed together with little intervening stroma. Diagnostic fine-needle aspiration cytology (FNAC) is an acceptable method of diagnosis.

Breast Infarcts: Infarcts may occur in fibroadenomas, hamartomas, lactating adenomas, or even in the regions of hypertrophic breast tissue. The aetiology is believed to be vascular insufficiency related to significantly increased metabolic demands. A pre-existing mass may suddenly increase in size, or a new mass may appear where none was previously palpable. Differentiating these lesions from cancer is more difficult than with lactating adenomas. Generally, biopsy is required.^[8,9,10]

Gigantomastia: In about 1 in 100,000 pregnancies, the normal increase in size and weight of the breasts is exaggerated to enormous proportions.^[11] The resulting hypertrophy is not only grotesquely deforming, but also may preclude ambulation or progress to skin ulceration, infection, or massive bleeding from dilated subcutaneous veins; these complications may be life threatening. The aetiology is unknown, but the disease is believed to represent an abnormal end-organ (breast) response to the normal rise in progesterone level as pregnancy progresses. Biopsy is recommended only when a discrete, suspicious region of abnormality is detected.^[12,13] Breast-feeding is not advised, because the hypertrophy may continue to increase. Reduction mammoplasty is generally necessary, because the breasts do not revert to normal size even after involution occurs.

Bloody Nipple Discharge: During the third trimester of pregnancy, proliferative changes within the ducts of the breasts may lead to bloody discharge from the nipple. This occurs when proliferative spurs of epithelium that extend into the ducts are traumatized, resulting in bleeding. Breast-feeding is not contraindicated, and the bleeding often ceases with the onset of nursing. Cytology of the discharge is apt to be misleading, as proliferative changes are typical for pregnancy and may be mistaken for neoplastic alterations. Biopsy is required only if the bloody discharge persists more than 2 months after delivery, localizes to 1 duct, or is associated with a palpable mass.^[14,15]

Galactoceles: They can occur during lactation but, more commonly, are noted after cessation of lactation, when the milk is allowed to stagnate within the breast. These smooth, mobile, often tender masses are localized collections of milk. There is no known relationship between galactoceles and the large cysts often seen in fibrocystic breast disease. Aspiration is both diagnostic and curative, yielding fluid milk

when performed during lactation or soon after cessation, and yielding more thickened, cheesy material from older lesions aspirated at a time remote from lactation. Several aspirations may be required. Ice packs and good mechanical support of the breast with a well-fitting brassiere are helpful. Mammography is rarely indicated, as aspiration is both diagnostic and curative. There is, however, a characteristic mammographic appearance best seen on an erect mediolateral view (which may show layering of fat density over water density). Older lesions containing thickened material may demonstrate a mixed water-fat density similar to that seen in mammary hamartoma. Surgery is rarely required.

Pregnancy-Associated Breast Cancer:

Incidence: Pregnancy-associated breast cancer (PABC) is defined as cancer diagnosed during pregnancy or within 1 year of delivery. It complicates 1 in 3000 deliveries in the US. The incidence of PABC is expected to increase as large numbers of women in developed countries defer childbearing into their 30s and 40s. Most PABC present as a painless mass, which in 90% of cases is discovered by the patient herself. Many series have documented significant delay in diagnosis (averaging 5 to 7 months, but as long as 18 months), with the responsibility for this delay ascribed to both patient and physician.^[16] Difficulty in palpating masses within the engorged and enlarged breasts, a tendency to attribute a mass to inflammation or mastitis, inadequate follow-up by the physician or patient, and reluctance to biopsy a questionable mass may all be involved.^[17] Any pregnant patient with a suspicious mass should be referred to a surgeon for evaluation by FNAC or biopsy. The radio-dense nature of the breast tissue in pregnant and lactating women significantly decreases the sensitivity of mammography. Ultrasound is emerging as an increasingly useful diagnostic tool, particularly in confirming the presence of borderline-palpable masses in PABC. Histologic confirmation by FNAC or biopsy is necessary before one can conclude that a given mass is benign or malignant.^[18,19,20]

CONCLUSION: Invariably, most breast disorders during pregnancy or lactation will ultimately prove to be benign. Nevertheless, the possibility of cancer should be kept in mind so as to intervene earliest possible without any risk to mother or fetus.

REFERENCES:

1. Guyton and Hall. Textbook of Medical physiology. Philadelphia: Saunders. Chapter 82, 2005;11th ed:page 1027.
2. Rosen PP. Rosen's breast pathology. Lippincott Williams & Wilkins; 2009.
3. Ulitzsch D, Nyman MK, Carlson RA. Breast abscess in lactating women: US-guided treatment. Radiology 2004;232:904–909.
4. Peters J. Mastitis puerperalis—causes and therapy. Zentralbl Gynakol 2004;126:73–76.

5. Marshall B, Hepper J, Zirbel C. Sporadic puerperal mastitis: an infection that need not interrupt lactation. *JAMA* 1975;233:1377-1379.
6. Strauss A, Middendorf K, Muller-Egloff S, et al. Sonographically guided percutaneous needle aspiration of breast abscesses—a minimal-invasive alternative to surgical incision. *Ultraschall Med* 2003;24:393–398.
7. Behrndt VS, Barbakoff D, Askin FB, et al. Infarcted lactating adenoma presenting as a rapidly enlarging breast mass. *AJR Am J Roentgenol* 1999;173:933–935.
8. Baker TP, Lenert JT, Parker J, et al. Lactating adenoma: a diagnosis of exclusion. *Breast J.* 2001;7:354–357. Doi: 10.1046/j.1524-4741.2001.
9. Akdur NC, Gozel S, Donmez M, et al. Spontaneous infarction of multiple fibroadenoma in a postlactational woman: case report. *Turkiye Klinikleri Journal of Medical Sciences* 2012;32:1429–1432. doi: 10.5336/medsci.2010-2209.
10. Oh YJ, Choi SH, Chung SY, et al. Spontaneously infarcted fibroadenoma mimicking breast cancer. *J Ultrasound Med* 2009;28:1421–1423.
11. Antveski BM, Smilevski DA, Stojovski MZ, et al. Extreme gigantomastia in pregnancy: case report and review of literature. *Arch Gynecol Obstet* 2007;275:149–53.
12. Swelstad MR, Swelstad BB, Rao VK, et al. Management of gestational gigantomastia. *Plast Reconstr Surg* 2006;118:840–8.
13. Shoma A, Elbassiony L, Amin M, et al. "Gestational gigantomastia": a review article and case presentation of a new surgical management option. *Surg Innov* 2011;18(1):94-101.
14. Kline TS, Lash SR. The bleeding nipple of pregnancy and postpartum: a cytologic and histologic study. *Acta Cytolog (Phila.)* 1984;8:336-340.
15. Dewitt JE. Management of nipple discharge by clinical findings. *Am J Surg* 1985;149:789-792.
16. Ishida T, Yokoe T, Kasumi F, et al. Clinicopathologic characteristics and prognosis of breast cancer patients associated with pregnancy and lactation: analysis of case-control study in Japan. *Jpn J Cancer Res* 1992;83:1143-1149.
17. Barnes DM, Newman LA. Pregnancy-associated breast cancer: a literature review. *Surg Clin North Am* 2007;87(2):417-430.
18. Schedin P. Pregnancy-associated breast cancer and metastasis. *Nat Rev Cancer* 2006;6(4):281-291.
19. Sukumvanich P. Review of current treatment options for pregnancy-associated breast cancer. *Clin Obstet Gynecol* 2011;54(1):164-172.
20. García-Manero M, Royo MP, Espinos J, et al. Pregnancy associated breast cancer. *Eur J Surg Oncol* 2009;35:215–8.