

BILIARY STENT ACTING AS NIDUS FOR STONE FORMATION: A CASE REPORTAmol Vajjanath Dahiphale¹, Samir Suresh Deolekar²¹Senior Resident, Department of General Surgery, Seth GSMC & KEM Hospital, Parel, Mumbai, Maharashtra.²Associate Professor, Department of General Surgery, Seth GSMC & KEM Hospital, Parel, Mumbai, Maharashtra.**HOW TO CITE THIS ARTICLE:** Dahiphale AV, Deolekar SS. Biliary stent acting as nidus for stone formation: a case report. J. Evid. Based Med. Healthc. 2019; 6(26), 1825-1827. DOI: 10.18410/jebmh/2019/372**PRESENTATION OF CASE**

Obstruction of common bile duct due to a 'Forgotten Stent' with stone formation is a rare entity. Choledocholithiasis is evident in approximately 10–15% patients with gallstones, more commonly in secondary.¹ However primary common bile duct (CBD) stones are more common in Asia. Choledocholithiasis can be treated by endoscopy or surgery. Recent trend is to do ERCP primarily and stone extraction with or without CBD stenting.

A forgotten stent in the CBD may remain in situ for years without any complication or may undergo migration. If not removed within time (4–6 weeks), it can act as a nidus for stone formation, which is known as "stentolith". As the stent may get impacted within the stone, an endoscopic procedure may not be successful in such cases, especially with a large stentolith, mandating surgical removal.

Relief of jaundice by the stent might be the cause why some patients forget or avoid getting such stents removed or replaced despite advice to the contrary. In benign cases, close follow-up with timely removal or regular replacement of such stents is important to prevent complications.

Here we discuss a case of Choledocholithiasis in a forgotten biliary stent (~ 10 years)

53 yrs. old, known diabetic male, presented with complaints of right sided upper abdominal pain, fever and jaundice for 15 days. He gave a history of similar episode of symptoms for which stenting was done 10 years back and a history of not getting the stent removed, as he apparently remained asymptomatic. The details of stenting were not available as patient had lost all documents.

On clinical examination, he was icteric, febrile, tachycardic and hypotensive at presentation. He had tenderness in the epigastrium and right hypochondrium. Rest of the abdominal and systemic examination was unremarkable.

CLINICAL DIAGNOSIS

Clinically we suspected it as cholangitis, and started treatment accordingly. We continued to look for cause of cholangitis.

Financial or Other, Competing Interest: None.

Submission 08-06-2019, Peer Review 15-06-2019,

Acceptance 26-06-2019, Published 01-07-2019.

Corresponding Author:

Dr. Amol Vajjanath Dahiphale,

At. Po. Khodwa Sawargao,

Parli Vai TQ, Beed District- 431515,

Mumbai, Maharashtra.

E-mail: avd1210@gmail.com

DOI: 10.18410/jebmh/2019/372

**DIFFERENTIAL DIAGNOSIS**

1. Empyema gall bladder
2. Liver abscess
3. Pancreatitis
4. Hollow viscous perforation

PATHOLOGICAL DISCUSSION

Liver function tests showed raised bilirubin, SGOT and SGPT. Blood sugar was 211 mg/dl. Total count were significantly raised, predominantly polymorphs.

CT Scan of abdomen demonstrated GB partially distended with CBD diameter of 20 mm and stent in situ, no pneumobilia, moderate central IHBRD most likely due to stent blockage. It also showed 6.5 x 6.3 cm size (volume 100 cc) ruptured subcapsular cholangitic liver abscess in segment II and III. (Figure 1)

It was followed up by MRCP which gave a report as moderate IHBRD with ruptured subcapsular cholangitic liver abscess with organised sludge / large calculus in CBD. Biliary stent in situ.

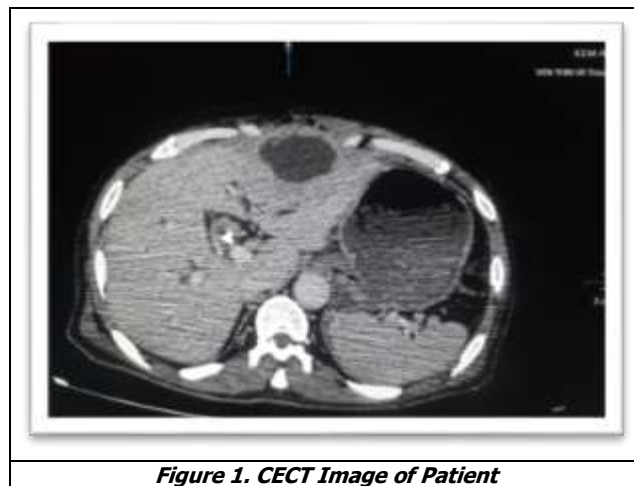


Figure 1. CECT Image of Patient

DISCUSSION OF MANAGEMENT

Patient was admitted in view of cholangitis, resuscitated with IV fluids, higher IV antibiotics (Meropenem 1 gm 8 hourly) and blood sugar controlled with insulin. Removal of previous stent by ERCP attempted but was not successful as stent in the common bile duct had formed a nidus with presence of sludge and multiple stones due to dense adhesions and fibrosis, so prophylactically another stent was placed to treat cholangitis.

Exploratory laparotomy was planned after optimization, pre-operative assessment and pre-anaesthetic evaluation.

Intra-operative findings were contracted, thick walled Gall bladder adherent to Common bile duct with multiple tiny

calculi in it. Dilated common hepatic duct with grossly dilated common bile duct and presence of multiple small stones in the common bile duct around stent. There was encrustation along the entire length of CBD stent extending from CHD to sphincter of Oddi and had formed a single large hard mass. A choledochotomy was then performed which revealed dirty yellowish brown sludge like material with multiple stones encasing two plastic stents inside the common bile duct. The encrusted stent was densely adhered to the wall of the common bile duct. The newly introduced stent was removed first.

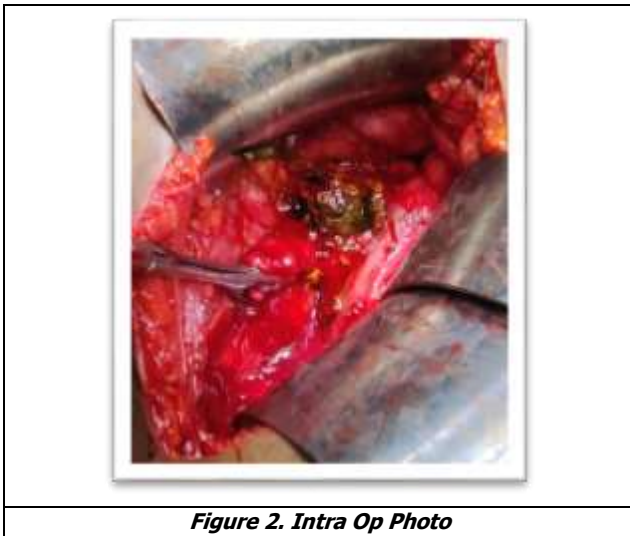


Figure 2. Intra Op Photo

After manipulation with adequate care and dissection, the stone along with the stent in toto was then removed completely. Choledochoscopy was done for confirmation. Thorough wash was given to the common bile duct to clear the sludge and the entire proximal and distal duct was irrigated and cleared with saline and Cholecystectomy done. The procedure was then completed by doing a choledochoduodenostomy with diamond shaped anastomosis. Haemostasis was achieved and the abdomen was closed in layers after placement of an abdominal drain.

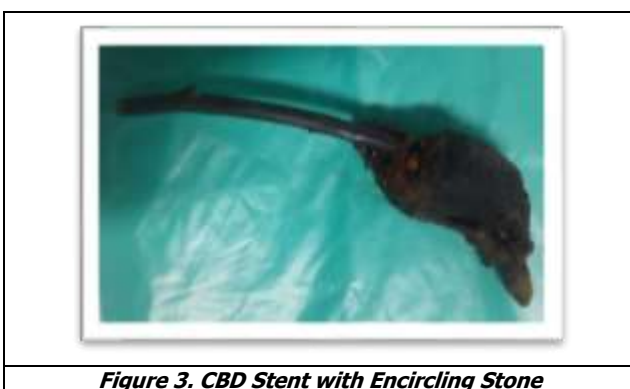

Figure 3. CBD Stent with Encircling Stone

Post-operative recovery was uneventful. Liver function tests came back to normal on 3rd post-operative day of surgery, diet was started on day-4, the abdominal drain was removed on 5th day and the patient was discharged after 8 days.

The word 'nidus' originated from Latin which means a place where something originates or is fostered or develops. A nidus is important for the formation of biliary stones. Stasis is an important contributing factor, that results either from stricture or foreign bodies. In one study, 30% of recurrent stones in the common bile duct after cholecystectomy were reported to contain non-absorbable suture materials in the centre of the stone, serving as a nidus.³ In a study, which investigated foreign body infection in the biliary tract it was found that implants in the biliary tract impaired the local host defence mechanism, resulting in an increased susceptibility to microbial infection and fibrosis.⁴ Foreign bodies like silk sutures, endo-clips, fish bone, retained T- tubes, plastic or metallic stents, etc. lead to biliary stasis leading to eventual stone formation. These plastic stents if kept for a prolonged period promote bacterial proliferation, and release of bacterial beta-glucuronidase, which results in the precipitation of calcium bilirubinate. Calcium bilirubinate is then aggregated into stones by an anionic glycoprotein. There remains a lumen in the common bile duct after placement of stents and this lumen may provide a pathway for bile flow even when the stents are completely obstructed. Koivusalo et al found that latex tubes were toxic and induced moderate to pronounced fibrosis and epithelial damage on the CBD wall, unlike silicone tubes.⁵

There are various indications for biliary stenting like CBD stone, CBD stricture, biliary leak, peri ampullary carcinoma, CBD malignancy, etc.⁶ The mean duration of the patency of the stent was about 12 months, but if not removed within (4-6 weeks), stent can act as nidus for stone formation.⁷ Most of the patients with stents in situ remain asymptomatic. However, inadequate follow up of the postoperative and post endoscopic period results in the formation of nidus around the stent and at times, cholangitis. Now a days, plastic stents are widely used. Plastic stent blockage presents at a median patent interval of 62-165 days; these stents may be exchanged prophylactically at a scheduled interval.⁸

The complex of stent and stone more often takes the shape of the inside of the bile duct, often acquiring a dumb-bell shape. The average duration of clinical manifestation post biliary stenting is around 5.64 years (range 2-11 years).⁹

Although rare, bile duct obstruction by a foreign body with secondary lithogenesis is possible. Endoscopic or surgical extraction of these foreign bodies is mandatory, in order to avoid the complications of obstructive jaundice.

Even with the recent advances in endoscopy, surgery may be required in certain cases. Intra-operatively, one must understand that hard impacted stone can be in proximity to portal vein posteriorly, so removal should be very careful. Also, there is high possibility of distal CBD stricture. If GB is not removed earlier, as in this case, cholecystectomy is mandatory, and one should be ready for densely adhered GB. Choledochoduodenostomy is preferred over hepatojejunostomy in view of significant dilated CBD and lower end CBD stricture due to chronic inflammation.

Bile duct obstruction by a foreign material though possible, is a rare entity. ERCP stenting although a simple and safe procedure, the possibility of ERCP stent acting as a nidus for stone formation should always be forethought and anticipated. Hence, a proper post-operative or a post-endoscopic follow up is mandatory and the patient must be given a detailed information regarding the possible complications and details of follow up. ERCP extraction of the stone and removal of the blocked stent remains a standard procedure but in cases of large stones covering the stents and prolonged fibrosis, surgery maybe the only option of removing the stones and stents and to relieve the obstruction.

FINAL DIAGNOSIS

Choledocholithiasis in A Forgotten Biliary Stent (~ 10 Years).

REFERENCES

- [1] Barai V, Hedawoo J, Changole S. Forgotten CBD stent (102 months) with stone stent complex: a case report. *Int J Surg Case Rep* 2017;30:162-164.
- [2] Bansal VK, Misra MC, Bhowate P, et al. Laparoscopic management of common bile duct "Stentolith". *Trop Gastroenterol* 2009;30(2):95-96.
- [3] Glenn F. Post cholecystectomy choledocholithiasis. *Surg Gynecol Obstet* 1972;134(2):249-252.
- [4] Yu JL, Andersson R, Wang LQ, et al. Experimental foreign-body infection in the biliary tract in rats. *Scand J Gastroenterol* 1995;30(5):478-483.
- [5] Koivusalo A, Makisalo H, Talja M, et al. Biocompatibility of latex and silicone T tubes in the porcine common bile duct: an experimental study. *Res Exp Med (Berl)* 1996;196(1):53-66.
- [6] Upwanshi MH, Shaikh ST, Ghetla SR, et al. De novo choledocholithiasis in retained common bile duct stent. *J Clin Diagn Res* 2015;9(9):17-18.
- [7] Schuller AM, Rezk GJ, Lyon DT. Calculus formation around common bile duct stents: a complication of long-term biliary drainage. *Gastrointest Endosc* 1991;37(5):581-582.
- [8] Moss AC, Morris E, Mac Mathuna P. Palliative biliary stents for obstructing pancreatic carcinoma. *Cochrane Database Syst Rev* 2006;(2):CD004200.
- [9] Tang SJ, Armstrong L, Lara LF, et al. De novo stent-stone complex after long-term biliary stent placement: pathogenesis, diagnosis, and endotherapy. *Gastrointest Endosc* 2007;66(1):193-200.