

Bernard-Soulier Syndrome with Unusual Presentation of Splenic Infarct

Anjali Shankar¹, Siddharth Gosavi², Tracey Austin Anne³, Anjitha Uthamarajan Nair⁴

^{1, 2, 3, 4} Department of General Medicine, JJM Medical College Davangere, Karnataka, India.

PRESENTATION OF CASE

A 26-year-old male presented to general medicine department on 16th March 2020 with complaints of 3 episodes of epistaxis for 2 days. The epistaxis was spontaneous, sudden in onset, recurring in nature, copious in amount, not relieved on its own. No history of nasal trauma, head injury, fever, joint pain, cough, breathlessness, difficulty in swallowing, pain abdomen, haematuria, rashes. No history of bleeding diathesis from any other site. Past history revealed similar complaints of nasal bleeding for past 2 - 3 months for which he used to get admitted and administered platelets transfusions after which the symptoms used to subside. No history of any bleeding disorders or other comorbidities. Family history revealed that the younger brother is a known case of Bernard-Soulier syndrome diagnosed at the age of 15 years. Drug history was insignificant. Based on patient's presentation and family history, a congenital bleeding disorder was considered as provisional diagnosis. On clinical examination pallor was observed in lower palpebral conjunctiva and dorsum of tongue and crusts were present in nose. Moderate splenomegaly was also observed.

His laboratory data revealed presence of microcytic hypo-chromic anaemia with hyponatremia, with prolonged bleeding time, normal clotting time and coagulation time. Complete blood count revealed severe microcytic hypochromic anaemia (haemoglobin - 5.8 gram / decilitre) (Figure 1) and giant platelets (Figure 2). Bleeding time was 12 minutes and clotting time was 8 minutes. Factor VIII levels were normal in the patient. Prothrombin time was prolonged with 13.9 seconds. Liver function test revealed only hypoalbuminemia with no derangement of liver enzymes. Renal function tests were normal. Serum electrolytes revealed hyponatremia with 130 millimole / litre. Ultrasound abdomen and pelvis revealed a heterogeneous focus which was noted in spleen with peripheral colour uptake and necrotic areas within it suggesting of splenic abscess / splenic haematoma / infarct. Contrast enhanced computed tomography of abdomen and pelvis revealed mild splenomegaly with heterogeneous foci with peripheral colour uptake and necrotic areas within it measuring 6.4 * 4.8 centimeters, areas were hypo dense and few enlarged retroperitoneal lymph nodes noted in para-aortic region. Computed tomography of brain plain was normal. Contrast enhanced computed tomography of thorax was normal. Platelet function tests revealed normal aggregation with adenosine diphosphate, collagen and arachidonic acid and markedly reduced with ristocetin. Flow cytometry could not be assessed.

His clinical examination revealed findings suggestive of anaemia and splenomegaly was also present with vital parameters within normal limits. He underwent thorough work-up with working diagnosis of bleeding disorder under evaluation.

Corresponding Author:

*Dr. Siddharth Gosavi,
Department of General Medicine,
JJM Medical College,
Dental College Road, MCC B-Block,
Davangere - 577004, Karnataka, India.
E-mail: ramshyamsid@gmail.com*

DOI: 10.18410/jebmh/2021/77

How to Cite This Article:

*Shankar A, Gosavi S, Anne TA, et al.
Bernard-Soulier syndrome with unusual
presentation of splenic infarct. J Evid
Based Med Healthc 2021;8(07):396-398.
DOI: 10.18410/jebmh/2021/77*

*Submission 10-09-2020,
Peer Review 17-10-2020,
Acceptance 26-12-2020,
Published 15-02-2021.*

*Copyright © 2021 Anjali Shankar et al.
This is an open access article distributed
under Creative Commons Attribution
License [Attribution 4.0 International (CC
BY 4.0)]*

	History	Bleeding Time	Clotting Time	Coagulation Profile	Factor VIII	Platelet Aggregation Test
Von Willebrand disease	Mucosal and skin bleed	Prolonged	Normal	Prothrombin time: normal Activated partial thromboplastin time: prolonged / normal	Reduced	Normal
Idiopathic thrombocytopenic purpura / immune thrombocytopenic purpura	Significant drug history	Normal / Increased	Normal	Prothrombin time: normal Activated partial thromboplastin time: normal	Normal	Normal
Glanzmann's thrombasthenia	Mucosal and skin bleed	Prolonged	Normal	Prothrombin time: normal Activated partial thromboplastin time: normal	Normal	Reduced with adenosine diphosphate
Bernard-Soulier syndrome	Mucosal and skin bleed	Prolonged	Normal	Prothrombin time: normal Activated partial thromboplastin time: normal	Normal	Normal with adenosine diphosphate, collagen and arachidonic acid. Reduced with ristocetin

Table 1. Differential Diagnosis for the Patient

Investigations revealed prolonged bleeding time with normal clotting time and platelet function test revealed normal aggregation with adenosine diphosphate (ADP), collagen and arachidonic acid and markedly reduced with ristocetin leading to diagnosis of Bernard-Soulier syndrome. The unusual thing in the current case is that patient's ultrasonography (USG) abdomen revealed splenic haematoma with absolutely no signs or symptoms of same which is rarely seen and reported in a case of Bernard-Soulier syndrome. Conservative management was the plan of treatment and was discharged with follow up of flow cytometric analysis. Routine USG abdomen and pelvis needs to be considered at the primary level to avoid life threatening complications.

A differential diagnosis was arrived at after clinical, laboratory and radiological assessment. (Table 1)

PATHOLOGICAL DISCUSSION

Bernard-Soulier syndrome is an extremely rare inherited disease which is transmitted as an autosomal recessive trait. The glycoprotein GP I b / V / IX complex corresponds to chromosomal loci of 17 p 12, 22 q 11.2, 3 q 29 and 3 q 21 binds to Von Willebrand factor. This binding is affected in Bernard-Soulier syndrome thereby affecting critical platelet functions. The prevalence of this disease is 1 per million.¹

The glycoprotein complex in Bernard-Soulier syndrome belonging to Leucine family is composed of four polypeptide subunits, GPIb α , GPIb β , GPIX, GPV. Maternal C89Y substitution causes disturbance in GPIX protein by substituting cysteine creating a disulphide bond. This mutation in heterologous cells was the basis of Bernard-Soulier syndrome. Therefore, hereditary diseases undergo massive genetic mutation across races which crucially change the epidemiology of the disease.² In India total numbers of reported cases till date are 27.³ The low frequency of this prevalence is due to the compactness of the affected genes with intron interruption. Jean Bernard and Pierre Soulier described a patient who had severe bleeding with prolonged bleeding time and thrombocytopenia.

However, in this case no thrombocytopenia was observed. Age at diagnosis varies widely from patient to patient due to the constellation like phenotype of the syndrome.⁴ In their study haemoptysis was the cardinal symptom which was diagnosed as Bernard-Soulier syndrome. In this study epistaxis is the cardinal symptom. In most cases bleeding symptoms should have manifested

in early childhood, but in this case, epistaxis was the clinical presentation which manifested much after adolescence. The patient presented not only with epistaxis but with splenic haematoma / infarct with absolutely no manifestation of pain abdomen.

The importance of avoiding trauma in patients who are diagnosed with bleeding disorders is an extremely crucial talking point so that the patient can lead a fairly healthy life. Radiological manifestations of the disease, history, clinical assessment and demographic factors play a major role in the diagnosis. It is imperative that along with patients, the parents must be educated on different types of bleeding, avoiding even minor accidents, careful handling of anti-platelet drugs and handling iron therapy.⁵

Hence, the absence of thrombocytopenia, the presence of splenic haematoma and infarct without pain abdomen was the unusual presentation of this case.

DISCUSSION OF MANAGEMENT

Patient was treated with IV antibiotics, IV haemostatic agents, nasal packing, desmopressin nasal spray, IV steroids, packed cell transfusions, platelet transfusions, IV proton pump inhibitor (PPI) and vitamin K. Patient improved symptomatically after 2 days and was discharged after 5 days of hospital stay. Patient was asked to follow up with coagulation profile after 7 days and was asked to watch out for any bleeding manifestations. These patients are ideal candidates for gene replacement therapy using megakaryocytes.

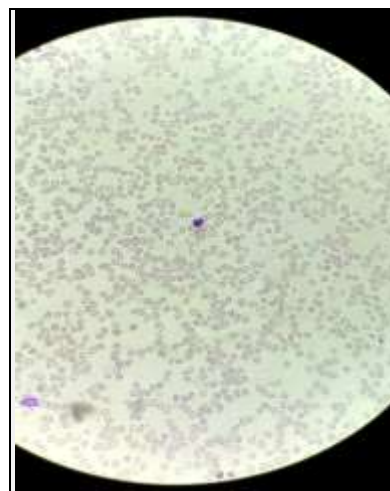


Figure 1. Peripheral Smear of the Patient Showing Microcytic and Hypochromic Anaemia

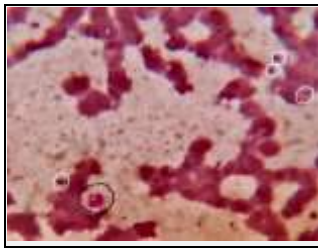


Figure 2.
Peripheral Blood Smear of the Patient with Leishman Staining Oil Immersion 100x Magnification. Marked with White Circles are Normal Sized Platelets and Marked with Black Circle is a Giant Platelet

Atypical presentation of Bernard-Soulier syndrome should be considered at the level of primary care itself and ultrasound of abdomen pelvis, bleeding time, clotting time and coagulation profile should be done for every 2 months as a routine workup for all bleeding disorders.

FINAL DIAGNOSIS

Bernard-Soulier syndrome.

Financial or other competing interests: None.

Disclosure forms provided by the authors are available with the full text of this article at jebmh.com.

REFERENCES

- [1] Lanza F. Bernard-Soulier syndrome (hemorrhagic thrombocytopenic dystrophy). *Orphanet J Rare Dis* 2006;1:46.
- [2] Kanda K, Kunishima S, Sato A, et al. A Brazilian case of Bernard-Soulier Syndrome with two distinct founder mutations. *Hum Genome Var* 2017;4(1):17030.
- [3] Sumitha E, Jayandharan GR, David S, et al. Molecular basis of Bernard-Soulier Syndrome in 27 patients from India. *J Thromb Haemost* 2011;9(8):1590-1598.
- [4] Macêdo MB, de Moraes MJB, da Silva MP, et al. Primigravida with Bernard-Soulier Syndrome: a case report. *BMC Res Notes* 2015;8:178.
- [5] Hasanzad M. Bernard-Soulier Syndrome (BSS) & tuberculosis: a case report. *Int J Mycobacteriol* 2014;3(4):283-285.