

ANTEROINFERIOR PLATING OF DISPLACED MIDDLE THIRD FRACTURE OF CLAVICLE

Shashi Kumar Yalagach¹, Mohammed Tauheed², Ayyappan V. Nair³, Yon Sik Yoo⁴, Mruthyunjaya⁵

¹Professor, Department of Orthopaedics, Ganapathi Orthopaedic and Spine Centre, Mysore, Karnataka.

²Assistant Professor, Department of Orthopaedics, DM Wayanad Institute of Medical Sciences, Meppadi, Wayanad, Kerala.

³Assistant Professor, Department of Orthopaedics, Amrita Institute of Medical Sciences and Research Centre, Kochi, Kerala.

⁴Shoulder and Elbow Surgeon, Hallym University Medical Centre, Dongtan, Seoul, S. Korea.

⁵Professor & HOD, Department of Orthopaedics, JSS Medical College & Hospital, Mysore.

ABSTRACT**PURPOSE**

Even though clavicle fractures have a good union rate conservatively, there are several indications for surgical management. Among the surgical techniques open reduction and plate fixation have been used extensively.

Although most surgeons prefer a superior plating technique, an anteroinferior plate location seems to be more advantageous considering the position and reduction of fragments.

MATERIAL AND METHODS

Fifteen consecutive patients with displaced middle-third fracture, delayed unions and non-unions of the clavicle underwent open reduction and internal fixation using an anteroinferior 3.5 mm reconstruction locking compression plate and screws. Patients were evaluated using patient symptoms, clinical signs and radiographic union, the Short Form-36 (SF-36), the American Shoulder and Elbow Surgeons Shoulder Assessment (ASES), and Constant Shoulder Score (CSS) outcomes questionnaire.

RESULTS

The mean age of the patients was 34.6 years (range 19 to 53 years) and all of them (n=15) were males. All patients were satisfied with their shoulder and upper extremity function as well as cosmesis from first week of surgery and were able to carry out their activities of daily living. Mean union time (absence of clinical tenderness and time for radiological union of fracture) was 14.6 weeks, range being 12 to 21 weeks. ASES score was 89. Constant shoulder score was 84 at the latest follow-up.

CONCLUSIONS

Anteroinferior plating of acute displaced middle-third fractures of the clavicle and non-union using 3.5 mm reconstruction locking compression plate typically results in early healing, few complications and an excellent return of function. Advantages of this technique include stable bony fixation with screws directed away from potentially dangerous infraclavicular structures, minimal or no incidence of implant prominence problems and good patient compliance. Further, we would like to emphasise the fact that reduction of small inferior fragments in comminuted fractures and protecting the graft when used in non-unions seems to be other added advantages of this technique.

KEYWORDS

Displaced clavicular fractures and non-unions; Anteroinferior plating; Fracture union; Complications; Patient and surgeon related outcomes.

HOW TO CITE THIS ARTICLE: Yalagach SK, Tauheed M, Nair AV, et al. Anteroinferior plating of displaced middle third fracture of clavicle. *J. Evid. Based Med. Healthc.* 2016; 3(37), 1811-1816. DOI: 10.18410/jebmh/2016/405

INTRODUCTION: Smekal et al described the morphology of the clavicle as "S"-shaped with a medial convexity and a lateral concavity; the acromial end of the clavicle is flat, its middle is round, and the sternal end shows a triangular cross-sectional profile.⁽¹⁾ This alteration in cross-sectional geometry from proximal to distal and the curvature along the length of the clavicle make it difficult to predict which plating position would yield the best biomechanical fixation.

The most relevant method for loading of the clavicle is still unknown.⁽²⁾

Fractures of middle third of clavicle account for approximately 80% of all clavicular fractures and they have traditionally been treated non-operatively, even when substantially displaced⁽³⁾ Treatment options for acute mid-shaft clavicle fractures include non-operative treatment (mostly sling or figure-of-eight bandage), open reduction and internal fixation with plates, and closed or open reduction and internal fixation with intramedullary pins, wires, or a nail.⁽⁴⁾

While the majority of middle-third fractures of the clavicle heal well with non-operative treatment, certain fractures require operative intervention. However, factors including severity of displacement, degree of comminution, and greater than 2 cm of shortening have been reported in

Financial or Other, Competing Interest: None.
Submission 12-04-2016, Peer Review 23-04-2016,
Acceptance 02-05-2016, Published 09-05-2016.
Corresponding Author:
Dr. Mohammed Tauheed,
Assistant Professor, Department of Orthopaedics,
DM Wayanad Institute of Medical Sciences.
E-mail: drmohammedtauheed@gmail.com
DOI: 10.18410/jebmh/2016/405

the literature to predispose patients to unsatisfactory outcomes with non-operative treatment.⁽⁵⁾ Middle third clavicular fractures are the subject of intense debate regarding both surgical indications and method of operative repair.⁽⁴⁾ Recent reports describe improved clinical outcomes after operative fixation of significantly displaced middle third fractures.⁽⁶⁻⁸⁾

Fixation with plate and screws (with or without bone graft) is still considered the gold standard for delayed and non-unions.⁽⁹⁾ Hardware prominence often necessitates hardware removal after healing when the plate is positioned on the superior aspect of the clavicle. To prevent prominence of the plate, positioning the plate on the anteroinferior aspect of the clavicle is gaining popularity.⁽¹⁰⁻¹²⁾

In a systematic review of the clavicle literature, Zlowodzki et al commented that the anteroinferior position appears to cause less postoperative symptoms compared with the superior position.⁽⁴⁾

Being convinced with the superiority of plate fixation over intramedullary fixation, but not satisfied with the frequent need for implant removal or the inadequacy of distal fixation, we used a technique for open reduction and internal fixation of displaced mid-shaft clavicular fractures and non-unions by plate osteosynthesis using reconstruction type of LCP (locking compression plate) along the anteroinferior aspect of the clavicle.

The purpose of this prospective clinical trial is to assess patient as well as surgeon related outcome measures, union rate, complication rate and cosmetic appearance of the shoulder and compare the same with other studies in the literature in 15 consecutive patients. We hypothesised that anteroinferior placement of reconstruction locking compression plate provides equivalent stiffness to that with plates placed in the classic superior position and that the locking plate provides increased stiffness compared with the non-locking plate, so that early mobilisation without external support can be started.

MATERIALS AND METHODS:

Institutional Review Board: Before initiating this prospective clinical trial, institutional approval was obtained from the ethical committee.

Patient Data: Between 2007 and 2010, eighteen fractures of middle third of clavicle in adults were treated surgically. After excluding one patient treated with intramedullary titanium wire fixation and 2 patients treated with open reduction and anteroinferior plating with reconstruction plate, 15 patients were included in this prospective clinical trial.

All of them were Allman type I, Craig group II and Robinson type II B1 or II B2. Eight patients had comminuted displaced fractures with major of the comminuted fragments in anteroinferior position, 5 had displaced oblique fractures and 2 had displaced transverse fracture. All had displacement or overlapping between main proximal and distal fragments of more than 2 cm.

None of them had systemic comorbidities and 4 were smokers for more than 5 years.

Surgical Technique: All patients were operated under general anaesthesia with the patient in beach chair position. Intravenous Cefuroxime 1.5 g was administered within 2 hours of surgery.

An incision of 10 to 12 cm centred over the fracture and paralleling an imaginary line connecting the sternal notch to the anterior edge of the acromion was made and no attempt made to isolate and protect infraclavicular cutaneous branches unless one was encountered. Incision deepened and lateral platysma was released, to the level of Clavipectoral fascia (fascia over the pectoralis major muscle) which was incised along its attachment to the anterior clavicle and carefully elevated in an inferior direction.

In noncomminuted displaced fractures both the fragments held reduced with reduction clamps. In comminuted fractures the major fragments held apart to the original length and the smaller fragments were teased into the defect using dental pick or 2 mm K-wire without further detaching their soft tissue attachment and without aiming for perfect anatomic reduction. Oblique fractures were initially stabilised using a 3.5 mm interfragmentary screw. Depending upon the fracture geometry and extent of comminution either a 6, 7 or 8 holed stainless steel reconstruction locking compression plate (Recon LCP) was contoured to serpentine or S shaped curvature of clavicle using AO type rod bender and was placed on the anteroinferior surface and fixed to the medial fragment using 3.5 mm cortical screw aiming posteriorly and superiorly. In transverse fractures compression across the fracture site was achieved using another 3.5 mm cortical screw in the lateral fragment in dynamic compression mode in the combo hole of the LCP. This eccentric screw placement in the combo hole was avoided in comminuted fractures. Only one locking screw used in each fragment.

If local callus available in delayed cases, it was packed at the fracture site on anterior and superior surface avoiding the inferior surface. Tricortical autologous iliac crest bone graft was interposed between the debrided ends in patient with clavicular non-union. Wound closed in 3 layers (The clavipectoral fascia was then closed over the bone and implants, and the skin and subcutaneous tissues were closed in separate layers) and arm was supported in arm sling.

Postoperative Protocol: Intravenous Cefuroxime was continued for 3 days followed by oral cefuroxime for 7 days. Check radiographs of clavicle (Zanca views) showed satisfactory position of the fracture. Patient was allowed pendulum and Codman exercises as well as unrestricted movements of shoulder and advised discharge on fifth day of surgery.

Follow-up and Assessment: After suture removal on tenth postoperative day, patients were followed at the interval of 4 weeks with assessment of shoulder function using Constant shoulder score and American Shoulder and

Elbow Surgeons' (ASES) as well as assessment of union was done clinically and radiologically. Radiographs were evaluated for evidence of union such as continuation of trabeculae across the fracture fragments, absence of screw loosening and plate failure. Careful vigilance was maintained during follow-ups to detect complications at the earliest and to assess radiologic fracture union time. High impact activities were allowed after consolidation of the fracture.

RESULTS:

Patient Data Distribution: The mean age of the patients was 34.6 years (range 19 to 53 years) and all of them (n=15) were males. Nine patients had fracture of right clavicle and 6 had fractures of left clavicle. One patient had non-union and 2 patients were delayed unions, rest of 12 patients had acute displaced fracture of middle third of the clavicle. Isolated displaced fracture of clavicle was present in 12 patients and one each had associated injury to dorsolumbar spine, ipsilateral knee and ipsilateral wrist.

Mechanism of injury was motor vehicle collision in 6 patients and fall from two wheelers in 9 patients. Six patients were seen by us within 7 days of injury and remaining 9 patients were managed initially conservatively at other orthopaedic centres for 3 to 4 weeks.

Mean inpatient (hospital) stay was 6.8 days (Range 4 to 10 days) and mean follow-up at the time of latest follow-up was 25.4 months (Range 16.5 to 32 months).

Outcome Measures: All patients were satisfied with their shoulder and upper extremity function as well as cosmesis from first week of surgery and were able to carry out their activities of daily living. At the last follow-up nobody demanded implant removal.

One patient (6.7%) who had deep abrasions over the anterior aspect of the fractured right clavicle and presented to us on fourth day had deep infection. It was detected during the first postoperative week and managed with Irrigation and Debridement with retention of plate and screws. Postoperatively intravenous Vancomycin was continued for one week and the fracture united eventually by 21 weeks.

Mean union time (Absence of clinical tenderness and time for radiological union of fracture) was 14.6 weeks, range being 12 to 21 weeks.

No other patients had complications and secondary procedures. There were no complications related to failure of identification and preservation of sensory branches of infra-clavicular nerves.

All the range of movements of the operated shoulder assessed by clinical observation and goniometer were within 10 degrees of normal compared to the unaffected shoulder. Muscle strength assessed by MRC (Medical Research Council) grading was grade 5. All 15 patients except one with paraplegia were able to carry out their pre-injury level of activity including manual labour and participation in sports. The ASES score was 89 and Constant shoulder score was 84 at the latest follow-up. No patients requested implant removal on their own.

DISCUSSION:

Anatomical Reduction and Malunion Clavicle:

Anatomical reduction of the displaced clavicle fracture has been of interest with several studies showing that the well reduced clavicle fracture or a corrected malunion by osteotomy and fixation had better results.⁽¹³⁻¹⁵⁾ Previously, malunion of the clavicle was thought to be of radiographic interest only and required no treatment. However, it is becoming increasingly apparent that clavicular malunion is a distinct clinical entity with radiographic, orthopaedic, neurologic, and cosmetic features.

Complications with Operative Treatment:

The operative treatment of acute mid-shaft clavicle fractures and clavicular non-unions have had varying results and more than a few complications. Complications after clavicle fixation include non-unions in 0-13% of patients, loss of fixation in 0-10%, and painful implant prominence or overlying skin problems in 6-93% of patients.⁽¹⁶⁻¹⁸⁾ Furthermore, the vital peri-clavicular anatomy may be at risk while using some of these surgical techniques, and catastrophic complications have been reported.⁽¹⁹⁾

Superior Placement of the Plate:

Most orthopaedic surgeons place the plate on the superior surface of the clavicle because of the presumed tension band principle and the greater biomechanical stability shown in cadaver studies.^(5,11,20) But Prominent and painful hardware is one of the main reasons for repeated intervention after consolidation.^(21,22) Hardware removal is reported to be as high as 81.3%.^(23,24) Based on recent level I evidence, the indication for plate fixation of the fractured clavicle is increasing.

The Anteroinferior Plate Placement:

We think that by positioning the plate on the anteroinferior side it functions like a buttress (analogous to a shelf) without the risk of screw pull-out of the lateral (distal) fragment. It seems that by plating the superior aspect, the downward force of the arm challenges the holding power of the screws in the often osteopenic lateral fragment, occasionally resulting in screw pull-out. The anteroinferior plate would rather function as an inferior buttress/shelf, especially under the lateral osteopenic bone, allowing the better (more cortical) medial fixation to support the construct. Another advantage of the anteroinferior position is that a longer bicortical screw can be used because the anteroposterior dimension of the clavicle is much greater than its superoinferior dimension. This will result in increased holding strength. Angular stable screw fixation increases holding power in the lateral fragment; and maybe there is a lower susceptibility for axial pull-out of the locking screws. And finally, the risk of iatrogenic injury to the neurovascular structures is obviously lower when placing screws from anteroinferior to posterosuperior rather than from superior to inferior.

Several studies show the superiority of this technique. In the series of anteroinferior plating by Kloen P et al, they did not had any failure, especially screw pull-out and

iatrogenic instrumentation complications.⁽¹⁰⁾ Collinge Cory et al reported the results of anteroinferior plating of displaced fractures of clavicle and painful non-unions with precontoured 3.5 mm plate and lag screws and structural iliac crest bone grafting only for non-unions with shortening in 80 consecutive patients. Complications included 1 failure of fixation, 1 non-union, and 3 infections. They concluded that anterior-inferior plating typically results in early healing, few complications and an excellent return of function.⁽¹²⁾

Ianotti et al used a simple transverse osteotomy model to test plate location on the stability of mid-shaft clavicle fractures. They found that compared to anteriorly applied plates, 3.5 mm Recon plates placed on the superior surface of the clavicle provided stiffer and more rigid constructs.⁽²⁰⁾

Sjoerd A. Stufkens and P. Kloen concluded that anteroinferior plating with a 3.5 mm LCP is a reliable and reproducible treatment of mid-shaft clavicular delayed and non-union regarding consolidation, function, cosmesis and reduction of second surgery.^(10,25) This plating technique has yielded excellent results with union after an average of 3.6

months and with all patients gaining full function and mobility.^(10,12)

Kloen et al,⁽¹⁰⁾ Der Tavitian et al⁽²²⁾ also reported excellent results with anteroinferior plating.

Thus, it appears that anterior-inferior plating techniques using 3.5 mm Recon LCP either compares well with or fares better than the historical controls.

Partal George et al in a mechanical study comparing superior plating with anteroinferior plating of twenty-four pre-osteotomised synthetic left clavicles (Sawbhes Worldwide, Vashon, WA) three non-destructive cyclic mechanical tests were performed in random order: axial, torsion, and four-point bending. They concluded that placing the plate anteroinferiorly on the clavicle provides a more stable construct in terms of bending rigidity with no detrimental effects on axial and torsional stiffness. They were also satisfied with other advantages, including avoidance of neurovascular compromise, the use of longer screws, and decreased hardware prominence.⁽²⁾

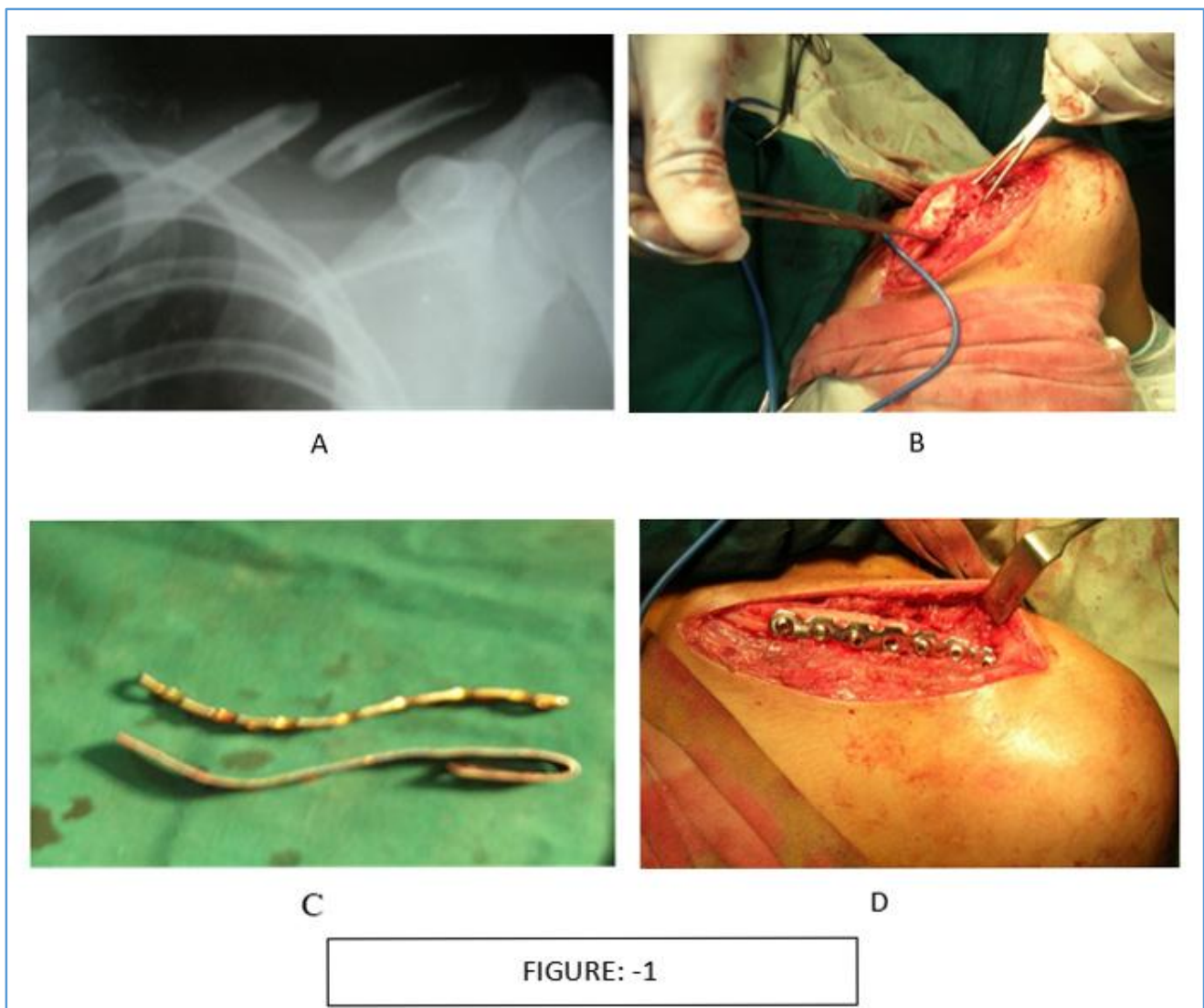


FIGURE: -1

Figure 1: 1A: One-year old Non-union of Middle Third of Clavicle in a 24-year young man. 1B: Freshening of Non-union Ends and Reaming of Medullary Canal. 1C: Contouring of 3.5 mm Plate to the S Shaped Curvature of Clavicle using AO Template. 1D: Fixation on Non-union with Contoured Anteroinferior Plate

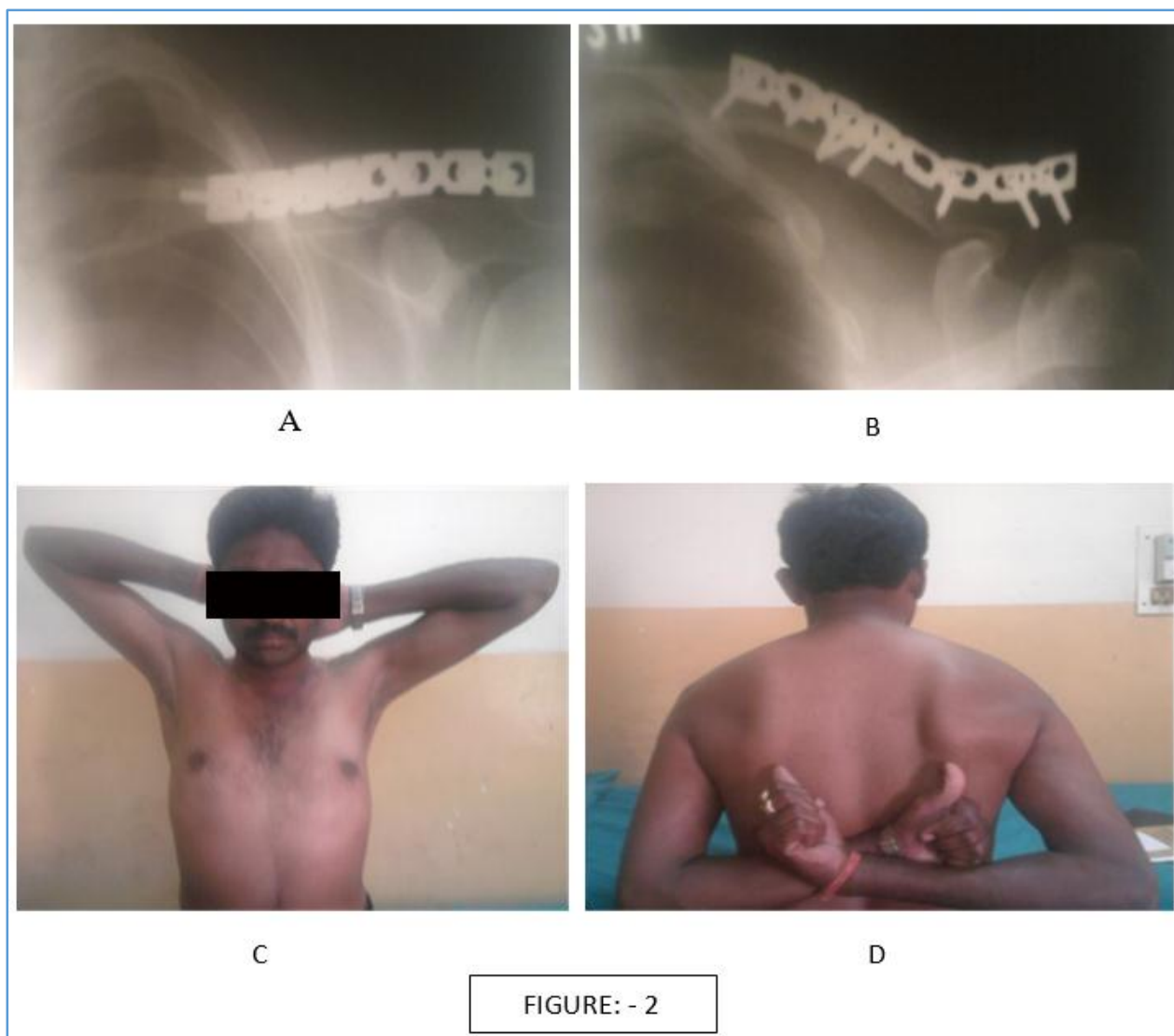


Figure 2: 2A and 2B: Post-Operative X-ray of Anteroinferior Plating using Reconstruction LCP. 2C and 2D: Shoulder Function at the end of 3 Months Showing Full Range of Motion

Anteroinferior Plate and the Reduction of the Butterfly Fragment: In our study, we have observed that a common pattern of comminution as seen in 8 out of our middle third clavicle fractures was an anterior-inferior butterfly fragment. This fragment by virtue of its size and location may be difficult to rigidly stabilise and was managed by additional fixation technique of "cerclage" fixation using sutures or stainless steel wire.

According to some authors, the plate position on the superior aspect of the clavicle is biomechanically superior because this represents the tension side, the presumed tension band principle and the greater biomechanical stability shown in cadaver studies.^(5,9,20) But this superior tension band plate fails if anteroinferior cortical comminution is present, which is the common pattern of comminution encountered and if inferior cortical continuity is not restored. Inferior cortical comminution should not be bone grafted along with superior plating even though it biomechanically sounds logical due to the risk of thoracic outlet compression syndrome later. However, anteroinferior locking LCP functions like a buttress without the risk of screw pull-out of the lateral fragment and counteracts the downward force of

the arm and gravity that challenges the holding power of the screws in the often osteopenic lateral fragment.

A case series of all locking screw pull-out from the lateral fragment as a result of superior plating with LCP has been reported. The anteroinferior plate would rather function as an inferior buttress/shelf, especially under the lateral osteopenic bone, allowing the better (more cortical) medial fixation to support the construct.

Another advantage of the anteroinferior position is that a longer bicortical screw can be used because the anteroposterior dimension of the clavicle is much greater than its superoinferior dimension. This will result in increased holding strength.

The drawbacks of our study seem to be the number of patients (n=15) was small and there were no controls to compare the results of anteroinferior plating.

CONCLUSION: This study shows that anteroinferior plating of fractures of middle third of clavicle results in excellent union rates and clinical outcomes without the need for any additional immobilisation. This technique specifically avoids complications that are frequently a direct result of the

superior placement of the plate, namely, infraclavicular neurovascular injury, instrumentation prominence and discomfort, the potential risk of screw pull-out and buttressing the lateral fragment against the force of gravity and weight of arm. We conclude that anteroinferior plating is a reliable, safe and effective technique that leads to high rates of bony union in mid-shaft clavicular fractures and allows for return of good-excellent function as well as excellent patient satisfaction.

REFERENCES:

1. Smekal V, Oberladstaetter J, Struve P, et al. Shaft fractures of the clavicle: current concepts. *Archives of Orthopaedic and Trauma Surgery*. 2009;129(6):807-815.
2. Partal G, Meyers KN, Sama N, et al. Superior versus anteroinferior plating of the clavicle revisited: A mechanical study. *Journal of Orthopaedic Trauma* 2010;24(7):420-425.
3. AH C. Fractures of the shoulder girdle, arm and forearm. AH C, editor. St. Louis: Mosby Year Book 1992;8th edn:989-1053.
4. Zlowodzki M, Zelle BA, Cole PA, et al. Treatment of acute midshaft clavicle fractures: systematic review of 2144 fractures: on behalf of the evidence-based orthopaedic trauma working group. *Journal of Orthopaedic Trauma* 2005;19(7):504-507.
5. Celestre P, Roberston C, Mahar A, et al. Biomechanical evaluation of clavicle fracture plating techniques: does a locking plate provide improved stability? *Journal of Orthopaedic Trauma* 2008;22(4):241-247.
6. Nowak J, Holgersson M, Larsson S. Can we predict long-term sequelae after fractures of the clavicle based on initial findings? A prospective study with nine to ten years of follow-up. *Journal of Shoulder and Elbow Surgery* 2004;13(5):479-486.
7. Ledger M, Leeks N, Ackland T, Wang A. Short malunions of the clavicle: An anatomic and functional study. *Journal of Shoulder and Elbow Surgery* 2005;14(4):349-354.
8. Lazarides S, Zafiropoulos G. Conservative treatment of fractures at the middle third of the clavicle: the relevance of shortening and clinical outcome. *Journal of Shoulder and Elbow Surgery* 2006;15(2):191-194.
9. Jupiter JB, Leffert RD. Non-union of the clavicle. Associated complications and surgical management. *The Journal of Bone and Joint Surgery American* 1987;69(5):753-760.
10. Kloen P, Sorkin AT, Rubel IF, et al. Anteroinferior plating of midshaft clavicular nonunions. *J Orthop Trauma* 2002;16(6):425-430.
11. Coupe BD, Wimhurst JA, Indar R, et al. A new approach for plate fixation of midshaft clavicular fractures. *Injury* 2005;36(10):1166-1171.
12. Collinge C, Devinney S, Herscovici D, et al. Anterior-inferior plate fixation of middle-third fractures and nonunions of the clavicle. *J Orthop Trauma* 2006;20(10):680-686.
13. McKee MD, Wild LM, Schemitsch EH. Midshaft malunions of the clavicle. Surgical technique. *The Journal of Bone and Joint Surgery American* 2004;86-A(Suppl 1):37-43.
14. McKee MD, Wild LM, Schemitsch EH. Midshaft malunions of the clavicle. *The Journal of Bone and Joint Surgery American* 2003;85-A(5):790-797.
15. Chan KY, Jupiter JB, Leffert RD, et al. Clavicle malunion. *Journal of Shoulder and Elbow Surgery* 1999;8(4):287-290.
16. Shen WJ, Liu TJ, Shen YS. Plate fixation of fresh displaced midshaft clavicle fractures. *Injury* 1999;30(7):497-500.
17. Schwarz N, Hocker K. Osteosynthesis of irreducible fractures of the clavicle with 2.7-MM ASIF plates. *The Journal of Trauma* 1992;33(2):179-183.
18. Bostman O, Manninen M, Pihlajamaki H. Complications of plate fixation in fresh displaced midclavicular fractures. *The Journal of Trauma* 1997;43(5):778-783.
19. Neer CS. Nonunion of the clavicle. *Journal of the American Medical Association* 1960;172(10):1006-1011.
20. Iannotti MR, Crosby LA, Stafford P, et al. Effects of plate location and selection on the stability of midshaft clavicle osteotomies: a biomechanical study. *Journal of Shoulder and Elbow Surgery* 2002;11(5):457-462.
21. Rosenberg N, Neumann L, Wallace AW. Functional outcome of surgical treatment of symptomatic nonunion and malunion of midshaft clavicle fractures. *Journal of Shoulder and Elbow Surgery* 2007;16(5):510-513.
22. Der Tavitian J, Davison JN, Dias JJ. Clavicular fracture non-union surgical outcome and complications. *Injury* 2002;33(2):135-143.
23. Mullaji AB, Jupiter JB. Low-contact dynamic compression plating of the clavicle. *Injury* 1994;25(1):41-45.
24. Boehme D, Curtis RJ, DeHaan JT, et al. Non-union of fractures of the mid-shaft of the clavicle. Treatment with a modified Hagie intramedullary pin and autogenous bone-grafting. *The Journal of Bone and Joint Surgery American* 1991;73(8):1219-1226.
25. Stufkens SA, Kloen P. Treatment of midshaft clavicular delayed and non-unions with anteroinferior locking compression plating. *Archives of Orthopaedic and Trauma Surgery* 2010;130(2):159-164.