

## ANATOMICAL VARIATIONS OF THE GASTROCNEMIUS MUSCLE- A DISSECTION-BASED STUDY

Rajat Dutta Roy<sup>1</sup>, Rubi Saikia<sup>2</sup>, Debabani Bora<sup>3</sup>

<sup>1</sup>Assistant Professor, Department of Anatomy, Jorhat Medical College, Jorhat, Assam.

<sup>2</sup>Associate Professor, Department of Anatomy, Jorhat Medical College, Jorhat, Assam.

<sup>3</sup>Associate Professor, Department of Anatomy, Jorhat Medical College, Jorhat, Assam.

### ABSTRACT

#### BACKGROUND

In human, the bulk of the posterior compartment of the leg is formed by the gastrocnemius and the soleus muscle. The superficially-placed gastrocnemius is a bipennate muscle, but according to available literature, it exhibits numerous anatomical variations.

The aim of the present study is to find out the anatomical variations of the gastrocnemius muscle in this part of Assam.

#### MATERIALS AND METHODS

The present study undertaken in the Department of Anatomy, Jorhat Medical College, from August 2014 to August 2017 included 30 lower limbs from 15 embalmed cadavers of known sexes. These cadavers were provided to the first year MBBS students for routine dissection procedure. After carrying out the dissection as per Cunningham's Manual of Practical Anatomy, the gastrocnemius muscle was examined for its two heads of origin. Any accessory heads found were noted and recorded.

#### RESULTS

Out of the 30 lower limb specimens, 28 (93.33%) limbs presented with the normal two-headed gastrocnemius muscle, while 2 (6.66%) limbs (1 right and 1 left), presented with four-headed gastrocnemius muscle. Both these limbs belonged to male cadavers.

#### CONCLUSION

The precise knowledge of occurrence of multi-headed gastrocnemius muscle should be kept in mind, while performing myocutaneous flaps around the knee joint and also during limb salvage procedures or limb sparing surgery.

#### KEYWORDS

Gastrocnemius, Variations, Bipennate, Two-headed, Multi-headed, Embalmed, Cadavers.

**HOW TO CITE THIS ARTICLE:** Roy RD, Saikia R, Bora D. Anatomical variations of the gastrocnemius muscle- A dissection-based study. J. Evid. Based Med. Healthc. 2017; 4(92), 5577-5580. DOI: 10.18410/jebmh/2017/1117

#### BACKGROUND

The posterior compartment of the leg is the largest of the three leg compartments. The muscles of this compartment are divided into superficial and deep groups by the transverse intermuscular septum. The superficial group of calf muscles include the gastrocnemius, the soleus and the plantaris. Collectively, the gastrocnemius and the soleus make up the three-headed triceps surae. The muscles of the posterior compartment produce plantar flexion at the ankle, inversion at the subtalar and transverse tarsal joints and flexion of the toes. The large size of the gastrocnemius and soleus muscle is a human characteristic that is directly related to our upright stance. These muscles are strong and heavy, because they lift, propel and accelerate the weight of

the body when walking, running, jumping or standing on the toes.<sup>1</sup>

The gastrocnemius muscle is the largest and most superficial muscle of the posterior compartment of the leg. It arises by two heads - medial and lateral. The large medial head arises by a flat tendon from the posterior superior aspect of the medial condyle of the femur behind the adductor tubercle and adjoining part of the popliteal surface of the femur. The small lateral head arise by a tendon from the lateral surface of the lateral condyle of the femur and adjoining part of the lateral supracondylar line.<sup>2</sup> The fleshy belly of the two heads descend and unite at the inferior margin of the popliteal fossa where they form the inferolateral and inferomedial boundaries of the popliteal fossa. It then unites with the tendon of the soleus muscle to form a long thick tendon, the tendo achilles, which is inserted to the lower part of the posterior surface of the calcaneum.<sup>3</sup> The gastrocnemius is the chief planter flexor of the foot and flexor of the knee. The muscular bellies of the gastrocnemius and the soleus are responsible for the rounded muscular prominence on the back of the leg. They are stronger and bulkier than the extensor muscles, because

*Financial or Other, Competing Interest: None.*  
*Submission 15-11-2017, Peer Review 22-11-2017,*  
*Acceptance 29-11-2017, Published 30-11-2017.*  
*Corresponding Author:*  
*Dr. Rubi Saikia,*  
*Associate Professor, Department of Anatomy,*  
*Jorhat Medical College, Jorhat – 785001, Assam.*  
*E-mail: drrubisaikia@gmail.com*  
*DOI: 10.18410/jebmh/2017/1117*



during walking or running, they are to raise the body weight from the ground.<sup>4</sup>

The Achilles tendon is the most powerful (thickest and strongest) tendon in the human body. It is approximately 15 cm in length. The tendon becomes thicker, but narrower as it descends until it becomes essentially round in cross section superior to calcaneus. It expands as it inserts centrally on the posterior surface of the calcaneal tuberosity. The tendon typically spirals a quarter turn (90 degrees) during descent, so that the gastrocnemius fibres attach laterally and the soleal fibres attach medially. This arrangement is thought to be significant to the tendons elastic ability to absorb energy (shock) and recoil releasing the energy as part of the propulsive force it exerts. Although, they share a common tendon, the two muscles of the triceps surae are capable of acting alone and often do so- You stroll with soleus, but win the long jump with gastrocnemius (Moore et al, 2010).

Variations in muscles are quite common and frequently encountered during routine dissection of the embalmed cadavers. According to literature, the third head is the most common variations of the gastrocnemius muscle.<sup>5,6</sup>

**Embryology-** Muscles of the limbs develop from myotomes present in the upper and lower limb bud regions. The mesoderm derived from these myotomes migrate into the limb bud during the 5<sup>th</sup> week and form anterior and posterior condensations. The anterior condensation gives rise to flexor and pronator muscles of the upper limb and extensor and adductor muscles of the lower limb. The posterior condensation gives rise to extensor and supinator muscles of the upper limb and flexor and abductor muscles of the lower limb.

**MATERIALS AND METHODS**

The present study was carried out in the Department of Anatomy, Jorhat Medical College and Hospital from August 2014 to August 2017. After obtaining ethical clearance from the Ethical Committee of JMCH, 15 adults’ embalmed cadavers of either sex were dissected and the gastrocnemius muscle studied. Of these, 9 were males and 6 were females.

All the 30 lower limbs were studied by blunt dissection method. To expose the posterior compartment of the leg, we followed the dissection steps as per Cunningham’s Manual of Practical Anatomy.<sup>7</sup> We first identified the medial and lateral heads of the gastrocnemius muscle and then we specially looked for any other accessory heads present. Variations found were noted and photographed for further analysis and comparison with the findings of other authors.

**RESULTS AND OBSERVATIONS**

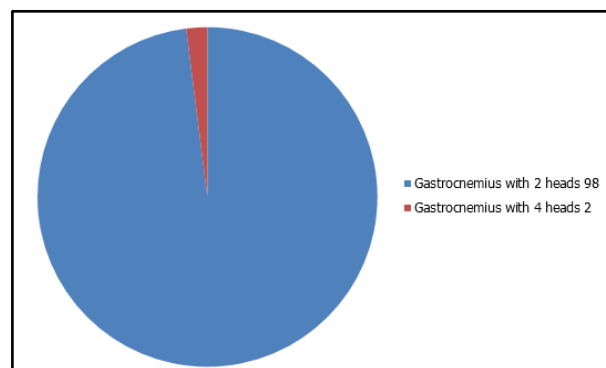
We found that all the 15 cadavers possessed the gastrocnemius muscle, but the number of heads differed in some. While 28 (93.33%) limbs presented with the normal two-headed (medial and lateral) gastrocnemius, 2 (6.66%) limbs belonging to two different male cadavers presented with accessory heads.

Male	Female	Total
9	6	15

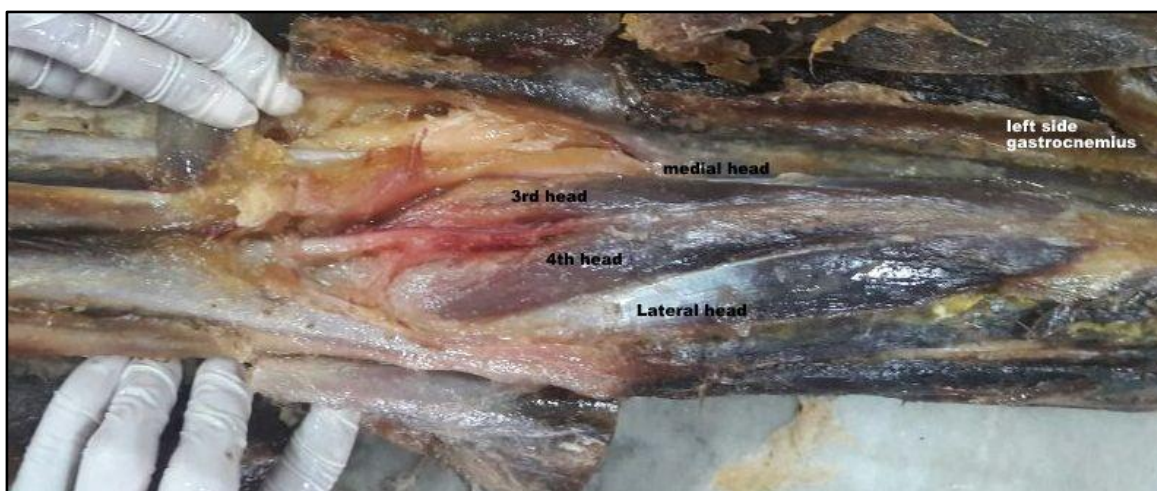
**Table 1. Showing the Sex Distribution of the Cadavers**

Number of Limbs with Two Heads (Medial and Lateral)	Number of Limbs with Three Heads	Number of Limbs with Four Heads	Total Number of Limbs
28 (93.33%)	0	2 (6.66%)	30

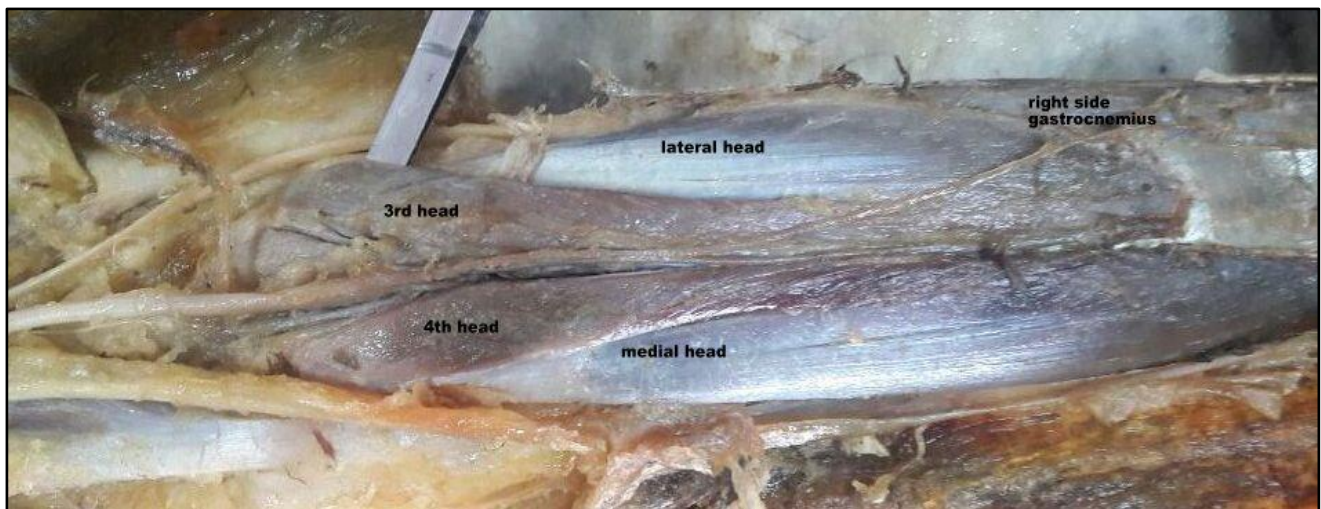
**Table 2. Showing the Number of Heads of Gastrocnemius at Origin**



**Distribution of Heads of the Gastrocnemius Muscle**



**Photograph 1. Left-Sided Four-Headed Gastrocnemius Muscle**



**Photograph 2. Right-Sided Four-Headed Gastrocnemius Muscle**

## DISCUSSION

Gastrocnemius is the largest and most superficial muscle of the posterior compartment of the leg. It consists of two heads- medial and lateral. The fleshy belly of the two heads descend and unite at the middle of the leg to form broad thin aponeurotic tendon, which unite with the tendon of soleus, a short distance below the middle of the leg to form a long thick tendon- the tendo calcaneus or tendo achilles, which is inserted to the middle of the posterior surface of calcaneum supplied by the tibial nerve. It is the chief plantar flexor of the foot at the ankle joint and flexor of the knee joint. The gastrocnemius provides rapid movements of the foot during walking, running and jumping (Moore et al, 2010, and Sahana 1982).

According to the text books and available literature, the two-headed gastrocnemius is the most common dominant form. These two heads are the medial head (larger) and lateral head (smaller). In the present study, we found two-headed gastrocnemius muscle in 93.33%, which is similar to the findings of Arce<sup>8</sup> and Koplak et al.<sup>9</sup> Arce in his study on Argentine population found the prevalence rate of two-headed gastrocnemius to be 92.5%. Koplak et al carried out their study on American population and reported the prevalence of two-headed gastrocnemius in 98.1%. In a similar study conducted on Indian population, the prevalence rate was found to be 80%.<sup>10</sup>

According to literature, the three-headed gastrocnemius is the most common variation of gastrocnemius muscle. Various authors have described its prevalence rate to be as 2.9%-5.5% (Bergman 1995), 7.5% (Arce 2008), 1.9% (Koplak et al, 2009), 20% (Shalini et al, 2013) and 13.3% (Ashaolu et al, 2014).<sup>11</sup> But, in our study, none of the 30 lower limb specimens presented with three-headed gastrocnemius muscle. Review of literature suggests that the third head may arise from the linea aspera, long head of biceps femoris muscle, lateral epicondyle of the femur and the knee joint capsule. When present, it commonly joins the medial head than the lateral head of the gastrocnemius muscle. It may split and arise from more than one location. It may divide to join both the heads of gastrocnemius.<sup>12,13,14</sup> The third head maybe responsible for causing popliteal

artery entrapment syndrome characterised by leg swelling with pain, tenderness of the popliteal fossa, diminution of pulse of the distal arteries, etc. Surgical resection of the third head relieves the symptoms. Accessory heads of the gastrocnemius muscle might be torn during sudden propulsive force generation. The gastrocnemius muscle is prone to spasms, which are painful and may last several minutes. A severe ankle dorsiflexion may result an injury to the muscle, commonly referred to as 'torn' or 'strained' calf muscle, which is acutely painful and disabling. Accessory heads of gastrocnemius covering the popliteal fossa region may help to delimit hyperextension during sporting activities. It might also help to prevent anterior cruciate ligament tears.

In our study, four-headed gastrocnemius muscle was found in 2 (6.66%) of the lower limbs studied. Both these limbs belonged to male cadavers. In a similar study conducted by Ashaolu et al (2014) in African population, they found four-headed gastrocnemius to be the most dominant form with 51.7% prevalence rate. No other literature referring the prevalence rate of four-headed gastrocnemius could be found for comparison. Accessory heads could be due to the geographical location or postural habits related to occupation.

The absence of lateral head of gastrocnemius muscle or its reduction to a fibrous cord has been reported.<sup>15</sup> But, in our study, none of the specimens presented with absence of any head of gastrocnemius.

## CONCLUSION

Variations in the origin of the gastrocnemius muscle does occur. Knowledge regarding accessory heads should be kept in mind, while performing surgery around the knee joint and while treating the symptoms of popliteal artery entrapment syndrome. Accessory heads could be due to racial variation, geographical location or postural habits.

## REFERENCES

- [1] Moore KL, Dalley AF, Agur AR. Clinically oriented anatomy. 6<sup>th</sup> edn. Lippincott Williams and Wilkins 2010:596-597.

- [2] William PL, Bannister LH, Barry MM, et al. Skeletal system and muscle. *Gray's Anatomy*. 38th edn. New York: Churchill Livingstone 1995:868-900.
- [3] Rosse C, GaddumRosse P. *Hollinshead's textbook of anatomy*. 5th edn. Lippincott-Raven Publishers 1997:372-373.
- [4] Sahana SN. *Human anatomy (Descriptive & Applied)*. Vol I. 3rd edn. Calcutta: 54B, Patuatola Lane, New Central Book Agency 1982:745-746.
- [5] Gupta RK, Bhagwat SS. An anomalous muscle in the region of the popliteal fossa: a case report. *J Anat Soc India* 2006;55(2):65-68.
- [6] Bergman RA, Walker CW, El-Khour GY. The third head of gastrocnemius in CT images. *Ann Anat* 1995;177(3):291-294.
- [7] Romanes GJ. *Cunningham's manual of practical anatomy. Upper & lower limbs*. Vol I. 15th edn. New York, USA: Oxford University Press, Oxford 2011:190-195.
- [8] Arce YV, Almiron YP, Diaz MAR, et al. Anatomical variations of the gastrocnemius muscle. *Br J Morphol Sci* 2008;25(1-4):157-214.
- [9] Koplak MC, Grooff P, Piraino D, et al. Third head of gastrocnemius: an MR imaging study based on 1,039 consecutive knee examinations. *Skeletal Radiol* 2009;38(4):349-354.
- [10] Shalini R, Suriyakumari KVP. Third head of gastrocnemius: a case report. *NJCA* 2013;2:166-168.
- [11] Ashaolu JO, Oni-Orisan OP, Ukwenya VO, et al. Variability of morphology of gastrocnemius muscle in an African population. *Anatomy Journal of Africa* 2014;3(3):400-404.
- [12] Bouhoutsos I, Daskalakis E: Muscular abnormalities affecting the popliteal vessels. *Br J Surg* 1981;68(7):501-506.
- [13] Yildirim FB, Sarikcioglu L, Nakajima K. The co-existence of the gastrocnemius tertius and accessory soleus muscles. *J Korean Med Sci* 2011;26(10):1378-1381.
- [14] Dave MR, Yagain VK, Anadkat S. Unilateral Third/accessory head of gastrocnemius muscle: a case report. *Int J Morphol* 2012;30(3):1061-1064.
- [15] Bergman RA, Thompson SA, Afifi AK, et al. *Compendium of human anatomical variation*. Baltimore: Urban & Schwarzenberg 1988; p. 7.