

## ADENOCARCINOMA OF CERVIX WITH SPECIAL REFERENCE TO VILLOGLANDULAR VARIANT

M. Rajani<sup>1</sup>, M. Vijaya Sree<sup>2</sup>, C. Padmavathi Devi<sup>3</sup>, G. Sailabala<sup>4</sup>

### HOW TO CITE THIS ARTICLE:

M. Rajani, M. Vijaya Sree, C. Padmavathi Devi, G. Sailabala. "Adenocarcinoma of Cervix with Special Reference to Villoglandular Variant". Journal of Evidence based Medicine and Healthcare; Volume 2, Issue 16, April 20, 2015; Page: 2408-2411.

**ABSTRACT: BACKGROUND:** Adeno Carcinoma of Cervix accounts for 15-20% of cervical cancers and villo glandular variant incidence in 3.7-4.8%. **AIM:** To diagnose the villo glandular adenocarcinoma as it has good prognosis compared to other variants of Adenocarcinoma. **MATERIAL AND METHODS:** Retrospective studies done from 2012 to 2014 for a period of three years. **RESULTS:** 18 cases of Adenocarcinoma were identified. Age group ranging from 25 to 75 years. 7 cases were villoglandular adeno carcinoma and others are endocervical adeno carcinoma – mucinous type. **CONCLUSION:** Adeno carcinoma accounts for 15-20% of cervical malignancies.<sup>(1)</sup> Villo glandular adeno carcinoma a distinct sub type of adenocarcinoma occurs predominantly in young women and has an excellent prognosis.<sup>(1,2)</sup>

**KEYWORDS:** Adenocarcinoma, Papillary, Villoglandular.

**INTRODUCTION:** Adeno Carcinoma constitutes 15 to 20% of Cervical cancers in women<sup>(1)</sup> well differentiated villoglandular Adeno Carcinoma is a distinct histological sub type<sup>(1,2)</sup> occurs predominantly in young women and has an excellent prognosis.

**MATERIAL AND METHODS:** During the period of three years 2012 to 2014 18 cases of Adeno carcinoma were reported Out of 18 cases 7 were reported as villo glandular variant of adeno carcinoma (Fig. 1 & 2) and rest were endocervical (mucinous) type (Fig. 3). All cases were formalin fixed and routinely processed.

All the histological slides were reviewed and the diagnosis was confirmed. Microscopically tumor composed of finger like papillary projections with central fibro vascular core comprising of cells with moderate atypia and moderate mitotic activity. There is no lympho vascular invasion.

**RESULTS:** During the 3 year period 18 cases of adenocarcinoma were diagnosed. Seven were diagnosed as villo glandular variant age of the patients ranged from 28 years to 65 years. One case is at the age of 28 years. Four cases at 40-50 years age group and two cases reported in 6<sup>th</sup> decade. All the cases presented with exophytic cervical growth.

**DISCUSSION:** Villoglandular carcinoma constitutes a rare histological sub type of Invasive adeno carcinoma of the uterine cervix. This form of Adeno Carcinoma usually affects young women and is believed to carry on excellent prognosis.<sup>(1)</sup>

In our study we reported two cases in post menopausal age group and four cases around 4<sup>th</sup> and 5<sup>th</sup> decade. Young and scully first described 13 patients with villo glandular pattern Adeno

# ORIGINAL ARTICLE

---

carcinoma in 1989.<sup>(1,2)</sup> Its incidence has been quoted as 3.7 to 4.8% of the adenocarcinomas of cervix<sup>(3,4)</sup> In our institute the incidence is 38.8%.

An association between the use of oral contraceptives and villoglandular adenocarcinoma was suggested by Jones et al.<sup>(5,6)</sup> A specific association is not found in our cases.

Grossly all tumors present as friable papillary or polypoid masses. Our patients also had similar presentation.

Microscopically tumors are composed of finger like papillary projections with central fibrovascular core and comprising of cells with moderate atypia and moderate mitotic activity.

Treatment modalities range from cone biopsies to simple and radical hysterectomy<sup>(7,8,9)</sup> villoglandular adenocarcinoma exhibits three distinguishing features – exophytic proliferation, Papillary architecture and mild to moderate atypia.

Additional histological sub types such as squamous cell carcinoma and endocervical adenocarcinoma can be associated.<sup>(10,11)</sup>

In our study all cases were pure villoglandular adenocarcinoma only with exophytic growth, complex papillary architecture, moderate mitotic activity.

The absence of lymphovascular invasion and nodal metastasis is usual. Because of the inherent good prognosis of their tumor fertility conserving procedures have been suggested.<sup>(1)</sup>

Young and Scully recommended that the initial treatment should be a cone biopsy if three criteria were fulfilled:

- 1) The margins of the cone are clear of the disease.
- 2) The depth of invasion is no more than 3mm and,
- 3) There shall be no evidence of lymphovascular invasion on histology.

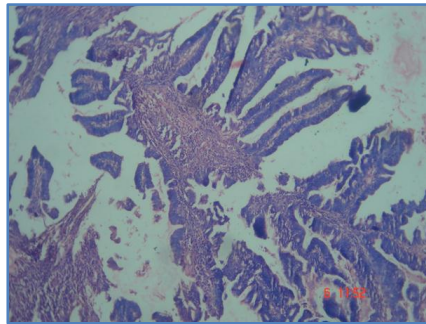
**CONCLUSION:** Villoglandular papillary adenocarcinoma accounts for 3.7%-4.8% incidence of adenocarcinoma. It is considered to have a favourable prognosis. However one must be very careful in making its diagnosis and should always be searched for other aggressive subtypes.

## REFERENCES:

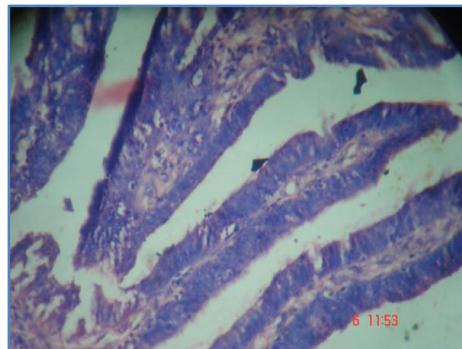
1. Young RH, Scully RE. Villoglandular papillary adenocarcinoma of the uterine cervix: A clinicopathologic analysis of 13 cases. *Cancer* 1989; 63: 1773-9. [PUBMED]
2. Hopson I, Jones MA, Boyce CR, Tarzza HM. Papillary villoglandular carcinoma of the cervix. *Gynecol Oncol* 1990; 39: 221-4.
3. Yamazawa K, Matsui H, Seki K, Mitsuhashi A, Kawamata Y, Shirasawa H, et al. Human papilloma virus-positive well-differentiated villoglandular adenocarcinoma. A case report and review of literature. *Gynecol Oncol* 2000; 77: 473-7. [PUBMED]
4. Jones MW, Silverberg SG, Kurman RJ. Well differentiated villoglandular adenocarcinoma of the uterine cervix: A clinicopathologic study of 24 cases. *Int J Gynecol Pathol* 1993; 12: 1-7. [PUBMED]
5. Liao SY, Manetta A. Benign and malignant pathology of the cervix, including screening. *Curr Opin Obstet Gynecol* 1993; 5: 497-503. [PUBMED]
6. Jones MW, Kaounelis S, Papadaki H, Bakker A, Swalsky PA, Woods J, et al. Well differentiated villoglandular adenocarcinoma of the uterine cervix: Oncogene/tumor

## ORIGINAL ARTICLE

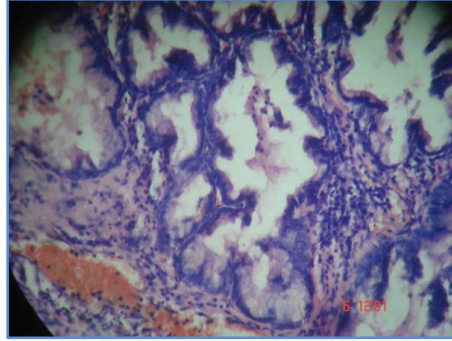
- suppressor gene alterations and human papillomavirus genotyping. *Int J Gynecol Pathol* 2000; 19: 110-7.
7. Reed W, Abeler VM, Trope CG. Villous glandular adenocarcinoma of the uterine cervix. A subtype with favourable prognosis? *Tidsskr Nor Laegeforen* 1993; 113: 2569-71.
  8. Datta CK. Well differentiated papillary villoglandular adenocarcinoma of the uterine cervix. *W. V. Med J* 1997; 93: 186-8.
  9. Bouman A, Oosterhuis GJ, Naudin TC, van Doorn GA. Villoglandular papillary adenocarcinoma of the cervix. Beware of a wolf in sheep's clothing. *Eur J Obstet Gynecol Reprod Boil* 1999; 87: 183-9.
  10. Kaku T, Kamura T, Shigematsu T, Sakai K, Nakanami N, Uehira K, et al. Adenocarcinoma of the uterine cervix with predominantly villoglandular papillary growth pattern. *Gynecol Oncol* 1997; 64: 147-52. [PUBMED]
  11. Stanley-Christian H, Heim BK, Hines JF, Hall KL, Willett GD, Barnes WA. Villoglandular adenocarcinoma of the cervix. A report of three cases and review of the literature. *Gynecol Oncol* 1993; 66: 327-30.
  12. Garcea A, Nunns D, Ireland D, Brown L. A case of villoglandular papillary adenocarcinoma of the cervix with lymph node metastasis. *BJOG* 2003; 110: 627-9.



**Fig. 1: H & E Complex papillary architecture in villoglandular variant adenocarcinoma**



**Fig. 2: H & E Papillary structure with Fibrovascular core. Cells show moderate atypia**



**Fig. 3: H & E Endocervical adenocarcinoma-mucinous type**

#### **AUTHORS:**

1. M. Rajani
2. M. Vijaya Sree
3. C. Padmavathi Devi
4. G. Sailabala

#### **PARTICULARS OF CONTRIBUTORS:**

1. Associate Professor, Department of Pathology, Guntur Medical College, Guntur, A. P, India.
2. Associate Professor, Department of Pathology, Guntur Medical College, Guntur, A. P, India.
3. Professor & HOD, Department of Pathology, Guntur Medical College, Guntur, A. P, India.

4. Professor, Department of Pathology, Guntur Medical College, Guntur, A. P, India.

#### **NAME ADDRESS EMAIL ID OF THE CORRESPONDING AUTHOR:**

Dr. M. Rajani  
C/o Meher Hospitals,  
#26-20-5, Swamy Street,  
Gandhi Nagar, Vijayawada,  
Andhra Pradesh, India.  
E-mail: drrajanim70@gmail.com

Date of Submission: 07/04/2015.  
Date of Peer Review: 08/04/2015.  
Date of Acceptance: 11/04/2015.  
Date of Publishing: 15/04/2015.