

Abnormal Case of a Mediastinal Lymphangiectatic Cyst with Post Op Chylous Fistula

Usha Rani Dalal*, Ashwani Kumar Dalal, Aggarwal Sarthak, Twinkle Dalal, Tirushi Jain

Department of General Surgery, Government Medical College and Hospital, Chandigarh, India

ABSTRACT

AIM

Non traumatic lymphangiectatic cysts of the lymphatic system are rare developmental anomalies that can appear at any age or site. Mostly asymptomatic and benign, those located in neck and mediastinum can present with pressure symptoms and may become life threatening if gets infected or ruptured. Moreover, the complication of high output chylous fistula that may develop post operatively are also well known to occur and are important to manage promptly and aggressively as nutritional depletion and decrease in immunity are fast to occur thereafter. Conservative management includes nutritional and diet changes. There are no exact guidelines on the timing of surgical intervention.

CASE SUMMARY

We report a case 24 years old boy having lymphangiectatic cyst in superior mediastinum extending into the neck presenting with progressive dyspnoea. The cyst was excised under GA. Subsequently, thoracic duct ligation *via* video assisted thoracoscopic surgery on 11th post day was done in view of high output chylous fistula and he was discharged in satisfactory condition.

CONCLUSION

Important to keep lymphangiectatic cyst as a differential diagnosis of neck and mediastinum masses. The importance and timing of thoracic duct ligation is important to understand. Apart from the thoracic duct the possibility of additional draining lymphatic ducts into the cyst should be kept in mind.

KEYWORDS

Lymphangiectatic cyst, Thoracic duct, Chyle, VATS.

INTRODUCTION

Congenital lymphangiectatic cysts of the lymphatic system are rare developmental anomalies that can appear at any age or site like mediastinum. Primary form in neonates is fatal [1]. Secondary forms are rare and presenting at any age leading to lymphatic channel dilatation in mediastinum. Collagen and muscle may be found in wall of dilated lymphatic channels [2]. Chyle fistula after surgery of lymphangiectatic cysts are rare and diagnosed with dye studies. They are managed conservatively or surgically by ligation of thoracic duct depending on amount of chyle. We report one such case of lymphangiectatic cyst removal leading to chyle fistula managed by thoracic duct ligation.

CASE DETAIL

A 24 years old boy, resident of district Hoshiarpur, Punjab, India was admitted to Government Medical College and Hospital, Chandigarh on 5 March, 2018.

*Corresponding Author:

Usha Rani Dalal. Department of General Surgery, Government Medical College and Hospital, Chandigarh, India E-mail: dalalacd@yahoo.com

How to Cite This Article:

Dalal UR, Dalal AK, Sarthak A, Dalal et al. Abnormal Case of a Mediastinal Lymphangiectatic Cyst with Post Op Chylous Fistula. J Evid Based MedHealthc 2024;11(04):1-5.

Received: 22-Oct-2024; Manuscript No: JEBMH-24-150731; Editor assigned: 25-Oct-2024; PreQC No. JEBMH-24-150731(PQ); Reviewed: 08-Nov-2024; QC No. JEBMH-23-150731; Revised: 15-Nov-2024; Manuscript No. JEBMH-24-150731(R); Published: 22-Nov-2024; DOI: 10.18410/jebmh/2024/11/04:1-5.

Copyright © 2024 Dalal UR, et al. This is an open access article distributed under Creative Commons Attribution License [Attribution 4.0 International (CC BY 4.0)]

He was working as an electrician in Dubai. During his stay in Dubai, he developed shortness of breath which was on exertion initially, later worsened over duration of 3 years to pose difficulty in sleeping in supine position forcing him to sleep in lateral decubitus position only. He occasional had dry cough with no history of any chest pain or any history of any upper limb weakness, paresthesia's or coldness. On examination there was no obvious swelling in the neck. His breath holding time was 39 seconds. Biochemical routine lab parameters and thyroid function test were normal. X-Ray neck lateral view in extension position showed slightly compressed trachea. Contrast Enhanced Computerized Tomography (CECT) thorax showed a 7 cm × 6.35 cm × 5.6 cm sized well defined thin walled, rounded, non-enhancing cystic lesion in left para and retro tracheal region in superior and middle zediastinum (Figures 1,2 and 3).

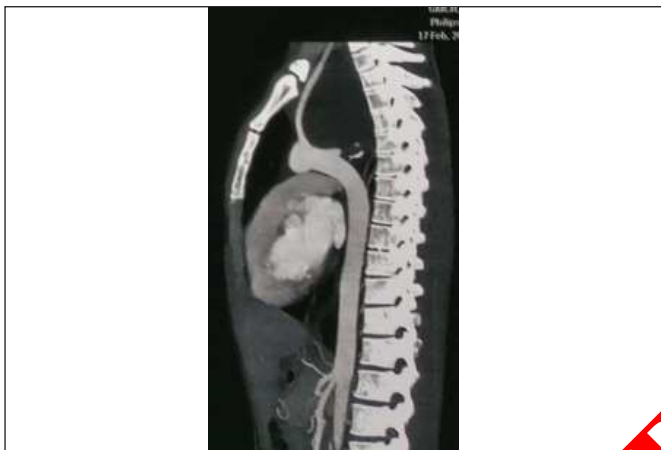

Figure 1. Cystic lesion in left para and retro tracheal.

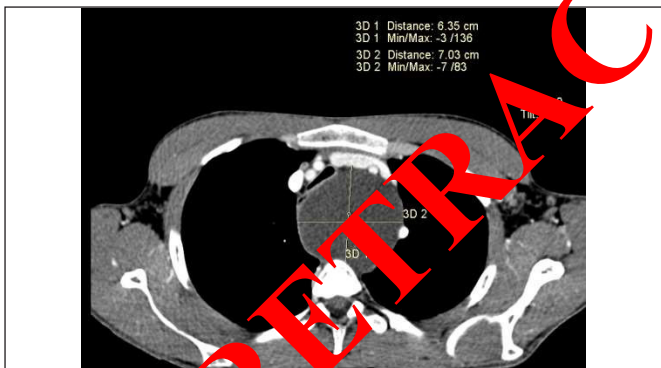

Figure 2. Contrast Enhanced Computerized Tomogra phy (CECT) of thorax.

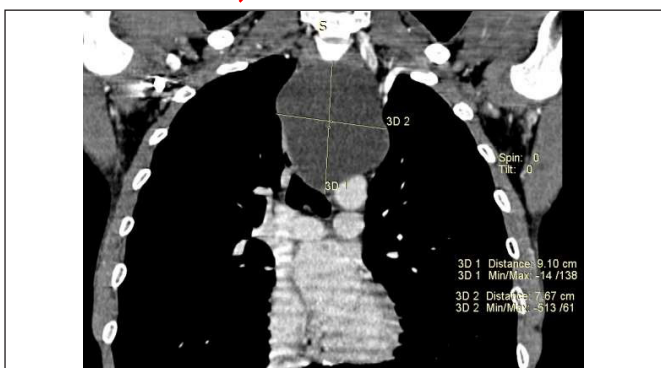

Figure 3. X-Ray neck lateral view in extension position showed slightly compressed trachea.

The lesion extended from infra thyroid region to just above the carina with the trachea displaced towards the right side. A probable diagnosis of foregut duplication cyst or bronchogenic cyst was mentioned in the report. Patient was planned for exploration. On 9 March, 2018, he underwent excision of the mediastinal mass through a 5 cm incision along the anterior border of his left sternocleidomastoid. Intraoperatively, there was a smooth contoured pearly white colored mediastinal cyst compressing the trachea from the left side extending from the thyroid to the suprasternal area. About 200 ml of whitish fluid was aspirated from the cyst. The cyst wall was separated from the surrounding structures and wall was excised piecemeal. A negative suction drain was put in the cavity and wound was closed. During extubating both the vocal cords were seen moving equally. Post-operatively, there was mild hoarseness of voice in the patient which improved over 7 days. The neck drain output initially was about 100 ml serous in nature on post-operative day 1 which increased slowly to 500 ml on postoperative day 5 and became milky white. The patient was given methylene blue orally mixed with milk. No color change in the drain fluid was seen. Patient was put on low oral fat diet. Drain fluid was positive for triglyceride levels. Till post-operative day 8, the drain output increased to 1500 ml. On POD 11, patient underwent video assisted thoracoscopic thoracic duct ligation under general anesthesia using single lung ventilation (Figures 4 and 5).

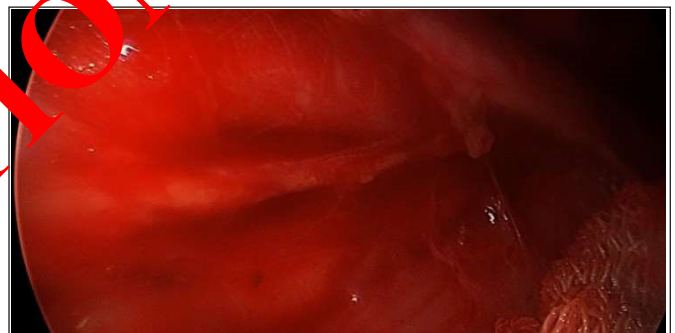


Figure 4. Thoracoscopic thoracic duct ligation under general anesthesia using single lung ventilation.

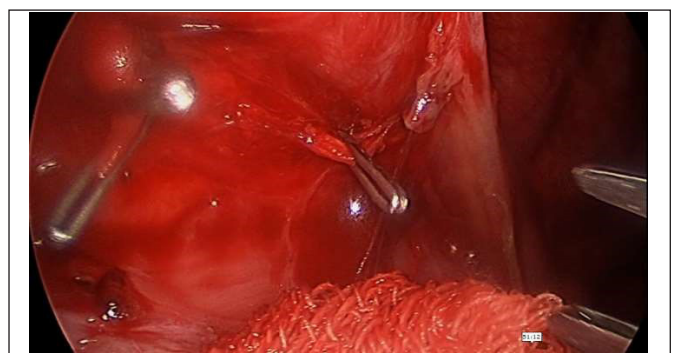

Figure 5. Thoracic duct ligation via Video-Assisted Thoracoscopic Surgery (VATS).

Patient was given 80 ml butter milk through Ryles tube after intubation 20 mins before starting the surgery and the thoracic duct was identified as a yellowish white structure which was clipped and cut. Right sided ICD was inserted. Patient was kept NPO. Medium chain fatty feed through Ryles tube was started with total parenteral nutrition and injection octreotide 100 mg s/c every 8 hours. ICD removed on POD 5 (Figure 6).

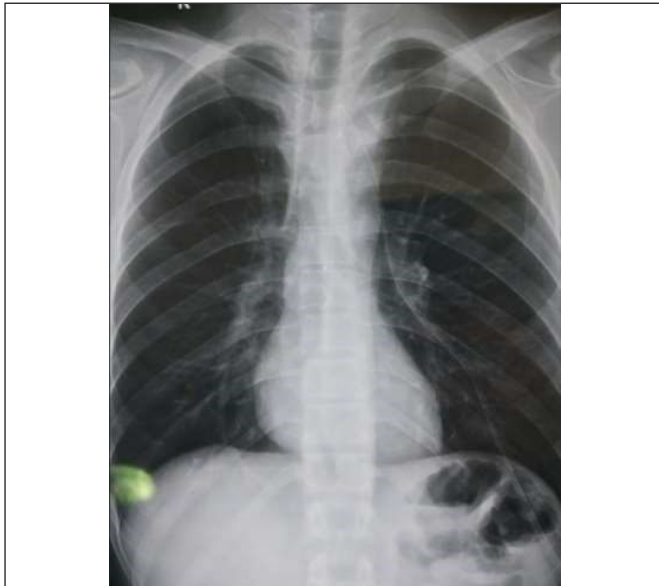

Figure 6. Chest X-Ray after removing International Classification of Diseases (ICD).

The drain output slowly decreased to 100 ml over 15 days. The drain accidentally came out on POD 16. Pressure bandage of that area was done in Figure 7.

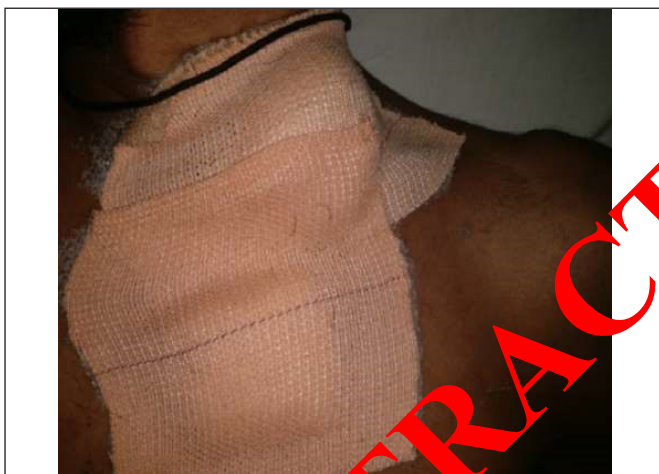

Figure 7. Pressure bandage after accidental drain removal.

Ultrasound of neck which don't show any remnant collection. Patient was discharged on day 21 post thoracic duct ligation. Histopathology report mentioned wall of the cyst having thin walled lymphatic channels lined by plump endothelial cells and few bundles of smooth muscle cells. Final report came out to be lymphangiectatic cyst. He was followed till 6 months post-surgery and with no new complaints.

DISCUSSION

The lymphatic system plays an important role in human circulation and organ perfusion homeostasis [1]. Lymphangiectasis are pathologic dilation of lymphatics. Primary Removing ICD (congenital) and secondary forms have been described. The primary form presents in neonates and is usually fatal. Secondary forms of lymphangiectasis result from a variety of processes that impair lymph drainage and

increase lymph production and presents at any age. In some cases, simple cystic spaces can be macroscopically identified along the anatomic lymphatic routes. The lymphatic spaces are dilated and, in some instances, cystic as in this case. A small amount of collagen and smooth muscle may be found in the walls of the dilated lymphatic vessels [2].

The thoracic duct is the main collecting channel of the lymphatic vessels draining most of the lymph of the body below the diaphragm and from the left half of the body above the diaphragm. It extends upwards from the upper end of the cisterna chyli opposite the upper lumbar vertebrae through the aortic orifice of the diaphragm and anterior to the thoracic vertebrae in the posterior mediastinum, crossing from right to left at the level of fourth and fifth vertebra until it reaches at the root of the neck on the left side of the esophagus to terminate in the junction of left internal jugular and subclavian vein. There is considerable anatomical variation in the cervical portion of the thoracic duct, although it usually courses along the medial border of the sternocleidomastoid muscle. The terminal arch of the duct can be between 0.5 cm and 4 cm above the clavicle before one or multiple thoracic lymphatic vessels join the venous system, most commonly the internal jugular vein and hence bifid and trifid configurations have been described [3-5]. In this particular case, the lymphangiectatic cyst could be possibly of either a major accessory lymphatic branch draining into the thoracic duct or of the thoracic duct itself as the output was high and it did not decrease with diet modification initially. Chyle fistula is defined as a leakage of lymphatic fluid from the lymphatic vessels that accumulates in the thoracic abdominal cavities or occasionally manifests as an external fistula. However, chyle fistulas most commonly occur secondary to lymphatic disease or malignancy or following abdominal, neck, or thoracic operations [3].

Diagnosis can be made based upon biochemical analysis of fluid for triglycerides 0.5 in healthy humans, the level of chyle transportation ranges from 1.5-4 liters/day; therefore, an output greater than 1 liter is considered to be a high output [6]. Chyle fistula can cause extreme morbidity because of the loss of fluids, electrolytes and other nutrients, loss of lymphocytes and immune dysfunction [3]. There are a number of case reports, chart and retrospective reviews regarding nutritional management in such chylous fistulas. However, prospective randomized trials are less because of the low incidence, making adequate samples for such trials almost impossible to obtain. Virtually, all recommendations are based on isolated cases and associates of patients and there is no consensus for the best type of regimen.

In conservative management, apart from negative suction and pressure strapping, diet should be transitioned to a non-fat diet, low fat diet, or Medium-Chain Fatty Acid (MCFA) diet. In general, a MCFA diet with protein, metabolic mineral mixture and multivitamin supplementation is preferable to a non-fat diet. Because short- and medium-chain fatty acids are largely water soluble and absorbed *via* the portal venous circulation rather than the gastrointestinal lymphatics, this special diet bypasses the gastrointestinal lymphatic system, resulting in decreased chyle flow at the fistula site [7]. Somatostatin and its long-acting analogue octreotide both acting as a neuro

hormone and paracrine agent have been shown to have role in chylous fistula by their ability to reduce gastrointestinal and pancreatic secretions, decrease hepatic venous pressure and reduce splanchnic blood flow. Somatostatin's major drawback is its short half-life, which requires continuous intravenous infusion. This problem was solved with the development of octreotide, permitting administration with long-lasting subcutaneous injections [7].

Doses begin at 50 mcg subcutaneously three times daily and can be increased up to 200 mcg three times daily [3]. The major documented complication of long-term octreotide treatment is the increased incidence of gallstones secondary to decreased bile production and gallbladder contractility. The less dramatic side effects include abdominal discomfort and decreased fat absorption.

To date, there are no consensus guidelines on the optimal octreotide treatment dose and duration in the management. Mostly case reports and few large trials are available [7]. The indication of surgical intervention is controversial, but persistent output of more than 600 ml/day for several days, despite medical therapy or extremely high output (>2L), is an appropriate indication [5]. Key step in the ligation of the duct is its identification as it emerges from the aortic hiatus. Definitive treatment is in the form of ligation of the thoracic duct by open thoracotomy was first described by Lampson in 1948 but Video-Assisted-Thoracoscopic Surgery (VATS) offers excellent magnified view of the thoracic structures, minimal access trauma and a quick postoperative recovery [8]. It also decreases the risk of pulmonary dysfunction [9]. Preoperative heavy cream or oil administration through the mouth or nasogastric tube has been reported to improve visualization of the thoracic duct during the surgery [10].

If still the thoracic duct is unable to be identified as frequently encountered in re-operative cases mass ligation is necessary to ligate the duct. The tissue between theazygos vein and the aorta is ligated just above the diaphragm using a non-absorbable suture [11]. In this particular case, the accidental removal of the neck drain post-operatively and pressure strapping of that area shows the possibility of collapse of the remaining cavity and hence aiding in the recovery of the chylous fistula.

Percutaneous treatment of the chyle leak was developed as another minimally invasive alternative leading to theoretically less morbidity and mortality. The treatment consists of diagnostic pedal lymphangiography followed by transabdominal catheterization of the cisterna chyli or lumbar lymphatics with Thoracic Duct Embolization (TDE) proximal to the chyle leak. The ability to identify the location of the chyle leak and variation in thoracic duct anatomy potentially improves the outcome. However, pedal lymphangiography is both time-consuming and technically challenging and remains a significant barrier to perform a TDE [6]. Additionally, Lymphatic-Venous Anastomosis (LVA) microsurgery, when technically applicable, have been described in which the healthy-appearing lymphatics found at the site of surgical incision are selected and directly introduced into the cut-end of a recipient vein (usually internal or external jugular vein) by a U-shaped stitch and then fixed by additional stitches between the vein border and the per lymphatic adipose tissue. Free flow of blue dye into the vein confirms testifies

the patency of LVA. This procedure requires the preoperative presence and exact knowledge of the lymphatic branches at the site of the search for successful anastomosis which precluded its use in this case.

Moreover, there is paucity of established retrospective and prospective studies in this area making review of this technique challenging [6]. Despite the technological advances and new approaches described in the recent literature, there is still no clear treatment algorithm for lymphatic chylous leaks but, at the same time, the time-tested role of VATS in today's minimally invasive era and side by side conceptual management of chylous fistula by diet and nutritional modification should be made a gold standard.

CONCLUSION

Keeping a low threshold for thoracic duct ligation, which avoids the clinical effects of prolonged chyle spilling and its implications and if done by thoracoscopy reducing hospital stay and costs and the patient's pain and morbidity is important. There is always a need for missing an accessory duct. Not forgetting the anatomical variations thoracic duct can have, the diet and nutritional modification should continue post-operatively for a few days. Also, lymphangiectatic cyst should also find a valuable place as a differential diagnosis in mediastinal masses.

REFERENCES

- Gabbieri D, Bavutti L, Zaca F, Turinetti B, et al. Conservative treatment of postoperative chylothorax with octreotide. *Ital Heart J* 2004;5(6):479-482.
- Faul JL, Berry GJ, Colby TV, Ruoss SJ, et al. Thoracic lymphangiomas, lymphangiectasis, lymphangiomatosis and lymphatic dysplasia syndrome. *Am J Respir Crit Care Med* 2000;161(3):1037-10444.
- Jain A, Singh SN, Singhal P, Sharma MP, et al. A prospective study on the role of octreotide in management of chyle fistula neck. *Laryngoscope* 2015;125(7):1624-1627.
- Kwon SS, Falk A, Mitty H. A Thoracic duct injury associated with left internal jugular vein catheterization: Anatomic considerations. *J Vasc Interv Radiol* 2002;13(3):337-339.
- Roh JL, Yoon YH, Park CI. Chyle leakage in patients undergoing thyroidectomy plus central neck dissection for differentiated papillary thyroid carcinoma. *Ann Surg Oncol* 2008;15(9):2576-2580.
- Campisi CC, Boccardo F, Piazza C, Campisi C. Evolution of chylous fistula management after neck dissection. *Curr Opin Otolaryngol Head Neck Surg* 2013;21(2):150-156.
- Sean W, Delaney, Shi H, Shokrani A, et al. Management of chyle leak after head and neck surgery: Review of current treatment strategies. *Int J Otolaryngol* 2017;(6):1-12.
- Kumar S, Kumar A, Pawar DK. Thoracoscopic management of thoracic duct injury: Is there a place for conservatism?. *J Postgrad Med* 2004;50(1):57-59.
- Fernandes P, Jatene F, Tokunaga C, Paulo M, et al.

Ligation of the thoracic duct for the treatment of chylothorax in heart diseases. *Arq Bras Cardiol* 2003;81(3):314-317.

10. Yang F, Zhou J, Li H, Yang F, et al. Near-infrared fluorescence-guided thoracoscopic surgical intervention for

postoperative chylothorax. *Interact CardioVasc Thorac Surg* 2018;26:171-5.

11. Shair UA, Sancheti M, Pickens A. Thoracoscopic thoracic duct ligation. *Oper Tech Thorac Cardiovasc Surg* 2012;17(4):292-301.

RETRACTION NOTE