

CASE REPORT

ABDOMINAL COCOON-A RARE CLINICAL ENTITY: A REPORT OF FOUR CASES

Tapan Mukherjee¹

HOW TO CITE THIS ARTICLE:

Tapan Mukherjee. "Abdominal Cocoon-A Rare Clinical Entity: A Report Of Four Cases". Journal of Evidence based Medicine and Healthcare; Volume 2, Issue 7, February 16, 2015; Page: 914-920.

ABSTRACT: INTRODUCTION: Abdominal Cocoon also known as Sclerosing encapsulating peritonitis is a rare condition that refers to total or partial encapsulation of the small bowel by a fibrocollagenous membrane or cocoon with local inflammatory infiltrate leading to acute or chronic bowel obstruction. **BACKGROUND:** The abdominal cocoon is a rare cause of intestinal obstruction and is usually diagnosed at the time of laparotomy, although bowel obstruction with abdominal lump should raise a suspicion. The aetiology is usually of unknown, although at times, it may be seen secondary to a variety of conditions. Approximately 60 cases have been reported in the literature. Tuberculosis is an infrequently implicated cause of abdominal cocoon, and has only occasionally been reported previously in the Literature, but its significance is more in India and places where the disease is more prevalent. **MATERIALS & METHODS:** The author encountered four cases of abdominal cocoon all diagnosed on laparotomy. They have been studied for the patient particulars, clinical presentation, operative findings and outcome. **RESULT:** All four patients presented with history suggestive of varying degrees of intestinal obstruction of variable duration. There was no history or findings to suggest a specific cause. The diagnosis of abdominal cocoon was never entertained pre-operatively in any, and they were all operated upon as cases of intestinal obstruction. The operative findings were similar in all cases, a large part of jejunum-ileum being encased amidst dense adhesion in a tough and smooth walled thick capsule. As a rule, there were dense inter-loop bowel adhesions in all the cases. All required surgical release of encapsulated loops of bowel (adhesiolysis). All recovered well after minor hiccups and attended follow up. Histopathological examination of the cocoon wall revealed in all cases more or less same picture: proliferation of fibrocollagenous tissue with non-specific chronic inflammatory reaction and with non-caseating epithelioid cell granulomas without Langhans' type of giant cells. AFB could never be found. **CONCLUSION:** Abdominal Cocoon is a rare clinical entity presenting as intestinal obstruction and is probably due to recurrent low grade or subclinical peritonitis, during which the patients had no significant abdominal signs, leading to sclerosis and membrane formation with subsequent development of a cocoon. Tuberculosis is highly prevalent in this part of the world and is likely to have a role.

KEYWORDS: Abdominal Cocoon (AC), Intestinal Obstruction (IO) Sub Acute Intestinal obstruction (SAIO), Low-grade peritonitis, CECT abdomen, Sclerosing encapsulating peritonitis.

INTRODUCTION: Abdominal Cocoon (AC) is a rare clinical entity presenting as acute or chronic bowel obstruction. Albeit rare, many surgeons are likely to encounter it at least once in their career. The author came across four in a span of six years and those cases have been reviewed for the patient particulars, clinical presentation, operative findings and outcome.

CASE REPORT

BACKGROUND: Intestinal obstruction is a common surgical emergency, and usually occurs secondary to intestinal adhesions, bands and obstructed hernias. The abdominal cocoon remains an uncommon cause of intestinal obstruction, and a search of Medline revealed only about 60 articles dealing with this topic till date. Of these, the majority of cases reported were of the primary type, but the secondary form was also frequently reported.¹

This clinical entity was described as early as in 1907 by Owtschinnikow as 'Peritonitis Chronica Fibrosa Incapsulata', and as 'Sclerosing Encapsulating Peritonitis' by Deeb et al in 1998.²

The condition has been classified as primary and secondary based on whether it is idiopathic or has a definite cause.^{2,3} Idiopathic cases might actually be caused by a subclinical peritonitis leading to the formation of a cocoon.^{4,5,2} Foo et al detected the condition in ten young girls with symptoms of bowel obstruction two years after menarche and postulated that a chemical peritonitis was caused by retrograde menstruation, leading to the formation of a cocoon.⁴ Identified and recorded secondary abdominal cocoon has been attributed to the following:^{1,6,5,2}

- Placement of Le Vein shunt for refractory ascites.
- Use of povidone iodine for abdominal wash-out.
- Beta Blocker like Practolol.
- CAPD.
- SLE.
- Sarcoidosis.
- Orthotopic liver transplantation.
- Tuberculosis.

Clinically, most patients with abdominal cocoon syndrome present with features of recurrent acute, subacute or chronic small bowel obstruction secondary to kinking and/or compression of the intestines within the constricting cocoon. An abdominal mass may also be present due to an encapsulated cluster of dilated small bowel loops.^{4,5,2}

The CT findings are peritoneal thickening, signs of obstruction, tethering/ agglutination, fixation of loops, mural thickening, ascites and loculated fluid collections. Peritoneal or mural calcifications may occur rarely. Containment of loops within a sac, the walls of which may show some enhancement is also seen. The entering and exiting bowel loops may be seen in such cases. Elliptical containment of bowel loops without malrotation and obstruction is seen in both barium and CT examinations.^{7,8}

METHODS: We encountered four cases of abdominal cocoon all diagnosed on laparotomy, in spite of prior CECT in two cases, in a span of six years (2004 to 2010) at two different hospitals. Three cases were reviewed retrospectively, and one prospectively for the patient particulars, clinical presentation, operative findings and outcome.

RESULTS: All four patients presented with history suggestive of varying degrees of intestinal obstruction of duration of one week to six months. Three of them complained of definite lump in abdomen in later part of the period of illness before seeking medical attention. There was no

CASE REPORT

history or C/F to suggest pulmonary or abdominal Koch's. The diagnosis of abdominal cocoon was never entertained pre-operatively in any of these cases, and they were all operated upon as cases of intestinal obstruction. The operative findings were very much the same in all cases, a large part of jejunum-ileum being encased amidst dense adhesion in a tough and smooth walled thick capsule. As a rule, there were dense inter-loop bowel adhesions in all the cases. We did not encounter overt manifestations of abdominal tuberculosis such as enlarged and caseating mesenteric lymph nodes, tubercles over the bowel serosa and mesenteric abscesses that may suggest a tubercular etiology. The surgical approach too was basically same in all, comprising a release of encapsulated loops of bowel (adhesiolysis); In two cases a short segment resection of devitalised small bowel loops were required.

All patients recovered more or less well after surgery, except for minor hiccups like prolonged ileus, requiring TPN in one case and abdominal wound failure requiring secondary suture in another. On histopathology proliferation of fibrocollagenous tissue with non-specific chronic inflammatory reaction and with non-caseating epithelioid cell granulomas without Langhans' type of giant cells with a mixed inflammatory infiltrate could be visualised. In all four cases; no acid-fast bacilli could be seen. But, in retrospect, all four cases tested positive for Mantoux Test and had a significantly high ESR, above 40 mm.

All four patients were counseled and advised four drugs anti-tubercular treatment for six months. All consented, and received the treatment. Except one all other three completed the course and attended follow up, at least till AT drugs continued.

Sl. No	Age	Sex	Clinical presentation	Operative findings	Operative procedure	CECT impression	HP Report	Follow up	Outcome
1	18	M	Intestinal obstruction (IO)	Cocoon, Interloop Adhesions, devitalised Loop of small bowel	Adhesiolysis Resection of devitalised bowe loop	Not done	Fibrcollagenous tissue, epithelioid cell granuloma, No casetion/No Langhan's Giant cell	Presumptive 4-Drugs AT treatment for Six Months	Good Clinical response. Lost in follow up after 6 months
2	32	F	Abdominal Lump with H/O SAIO in retrospect. Initially thought to be Ovarian SOL and admitted at G&O IPD	Cocoon, Interloop Adhesions	Adhesiolysis	Mesenteric cyst	Similar	Presumptive 4-Drugs AT treatment for Six Months	Good Clinical response. Lost in follow up after about 14 months

CASE REPORT

3	24	M	IO with abdominal lump	Cocoon, Interloop Adhesions	Adhesiolysis	Not done	Similar	Presumptive 4-Drugs AT treatment for Six Months	Good early clinical response. Lost in follow up after two months
4	33	M	SAIO with abdominal lump	Cocoon, Interloop Adhesions, devitalised Loop of small bowel	Adhesiolysis Resection of devitalised bowel loop	Large part of small bowel encapsulated in a huge sheath like structure occupying entire right quadrants- ? Internal Hernia	Similar	Presumptive 4-Drugs AT treatment for Six Months	Good Clinical response. Doing well till date.

Table 1: Patient Data

DISCUSSION: The plausible hypothesis for pathogenesis of AC is recurrent low grade or subclinical peritonitis, during which the patients had no significant abdominal signs, leading to sclerosis and membrane formation with subsequent development of a cocoon.^{5,9} Tuberculosis is highly prevalent in this part of the world and is likely to have a role in the formation of Abdominal Cocoon due to retrograde infection via fallopian tubes from subclinical pelvic inflammatory disease/ genitourinary tuberculosis.^{1,10,11,4,12}

Wani et al from SMHS Hospital, Srinagar, Kashmir in their published series of Tuberculous abdominal cocoon, reported 11 cases where they could confirm the cause in each case histopathologically.¹¹ But, in the cases encountered by us till date, we could not establish a HP diagnosis, but offered presumptive treatment with AT drugs with good clinical response.¹³

The possibility of abdominal cocoon should be considered in patients with SAIO and abdominal lump.¹⁰ An abdominal mass may or may not be present.^{14,15} Abdominal cocoon being a rare condition, CECT is useful in clinching the diagnosis and planning elective surgery in experienced hands.¹⁰ Although some authors have described a few radiological signs on plain x-ray, barium series and computerized tomogram scan, it is, as a rule, difficult to be able to make a definite pre-operative diagnosis of this entity.^{1,6,16,17,18} The diagnosis is usually made at laparotomy, when the encasement of the small bowel within the sac-like cocoon is visualized. Although the disease primarily involves small bowel, it can extend to involve other organs like the large intestine, liver and stomach. Differential diagnosis included peritoneal encapsulation, which was described as a developmental anomaly where the whole of the small bowel is encased in a thin accessory membrane. The clinical symptoms of this condition differ from those of the abdominal cocoon syndrome, in that the patients are mostly asymptomatic and the findings are incidental and late in life.^{5,2} The treatment is by lysis of this covering membrane, and rarely, further procedures such as resection, are required.^{1,16,19,14,18} Meticulous dissection of the cocoon

CASE REPORT

membrane from the gut to release the entrapped intestine and separation of the inter loop adhesions is the treatment of choice.² The final diagnosis of abdominal cocoon is usually based on intra-operative and histopathology findings, with a significant number presenting for emergency treatment without any imaging being performed.²⁰

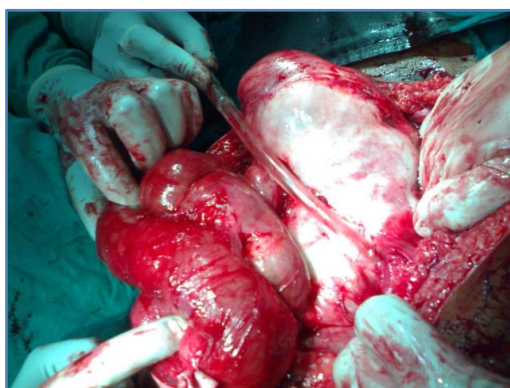
ACKNOWLEDGEMENT: RKMS Hospital & VIMS-Kolkata & HOD-Surgery: Prof. Pallab Ghosh, MS, FRCS, MnAMS, UMRI Hospital-Kolkata, for material support & technical help.

REFERENCES:

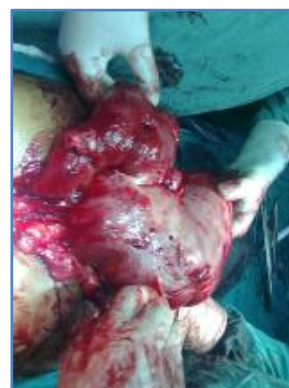1. Kaushik R; Punia RP; Mohan H; Attri AK, Tuberculous abdominal cocoon – a report of 6 cases and review of the Literature. *World J Emerg Surg.* 2006; 1:18 (ISSN: 1749-7922)[Medline].
2. S Ranganathan, 1 BJJ Abdullah,1 V Sivanesaratnam. Abdominal Cocoon Syndrome: *J HK Coll Radiol* 2003; 6: 201-203[Medline].
3. Deeb LS, Mourad F, El-Zein Y, Uthman S. Abdominal cocoon in a man: preoperative diagnosis and literature review. *Clin Gastroenterol* 1998; 26; 148-150[Medline].
4. Foo KT, Ng KC, Rauff A, Foong WC, Sinniah R. Unusual small intestinal obstruction in adolescent girls: the abdominal cocoon. *Br J Surg* 1978; 65: 427-430.
5. Sieck JO, Cowgill R, Larkworthy W. Peritoneal encapsulation and abdominal cocoon: case reports and a review of the literature. *Gastroenterology*1983; 84: 1597-1601.
6. Krestin GP, Kacal G, Hauser M, Keusch G, Burger HR, Hoffmann R. Imaging diagnosis of sclerosing peritonitis and relation of radiologic signs to the extent of the disease. *Abdom Imaging*1995; 20: 414-420[Medline].
7. Gupta S, R.G. Shirahatti, Anand J, CT findings of an abdominal cocoon. *Am. J. Roentgenol* 2004; 183: 1658-1660. [Medline].
8. Pillai JR, Kumar SN, Aneena PR, Idiopathic abdominal cocoon, *Ind J Radiol Imag* 2006; 16: 4: 483-485.
9. Maguire D, Srinivasan P, O'Grady J, Rela M, Heaton ND. Sclerosing encapsulating peritonitis after orthotopic liver transplantation. *Am J Surg*2001; 182: 151-154 [Medline].
10. Mohanty D; Jain BK; Agrawal J; Gupta A; Agrawal V. Abdominal cocoon: clinical presentation, diagnosis, and management. *J Gastrointest Surg.* 2009; 13 (6): 1160-2 (ISSN: 1873-4626) [Medline].
11. Wani I; Ommid M; Waheed A; Asif M, Tuberculous abdominal cocoon: original article. *Ulus Travma Acil Cerrahi Derg.* 2010; 16 (6): 508-10 (ISSN: 1306-696X) [Medline].
12. Laloo S, Krishna D, Maharajh J. Abdominal cocoon associated with tuberculous pelvic inflammatory disease. *Br J Radiol* 2002; 75: 174-176[Medline].
13. Brewer TF, Heymann SJ, Ettling M. An effectiveness and cost analysis of presumptive treatment for Mycobacterium tuberculosis. *Am J Infect Control.* 1998 Jun; 26 (3): 232-8. [Medline].
14. Noor NHM, Zaki NM, Kaur G, Naik VR, Zakaria AZ: Abdominal cocoon in association with adenomyosis and leiomyomata of the uterus and endometriotic cyst: Unusual presentation. *Malaysian J Med Sci* 2004, 11: 81-5. [Medline]

CASE REPORT

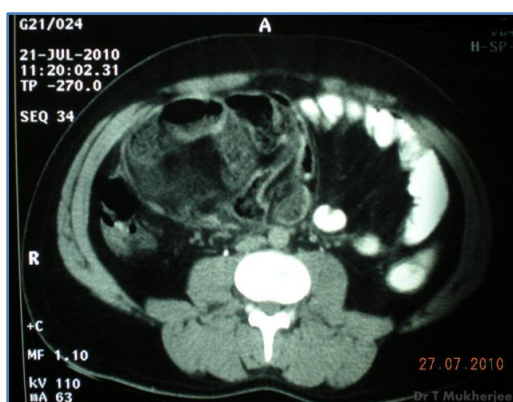
15. Wig JD, Goenka MK, Nagi B, Vaphei K: Abdominal cocoon in a male: A rare cause of intestinal obstruction. *Tropical Gastroenterol* 1995, 16: 31-3. [Medline].
16. Hamaloglu E, Altun H, Ozdemir A, Ozenc A: The abdominal cocoon: A case report. *Dig Surg* 2002, 19: 422-4. [Medline]
17. Yoon YW, Chung JP, Park HJ, Cho HG, Chon CY, Park IS, Kim KW, lee HD: A case of abdominal cocoon. *J Korean Med Sci* 1995,10: 220-5 [Medline].
18. Kumar M, Deb M, Parshad R: Abdominal cocoon: Report of a case. *Surg Today* 2000, 30: 950.
19. Deeb LS, Mourad FH, El-Zein YR, Uthman SM: Abdominal cocoon in a man. Preoperative diagnosis and Literature review. *J Clin Gastroenterol* 1998, 26: 148-50.
20. Sharma D, Nair R P, Dani T, Shetty P: Abdominal cocoon-A rare cause of intestinal obstruction. *International Journal of Surgery Case Reports*.2013 Aug; 4: 955– 957.



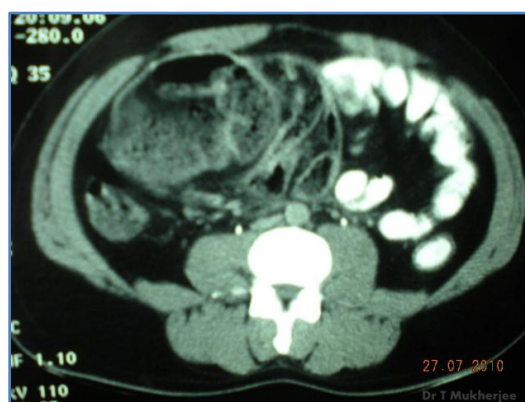Dr. TM_peropn-snaps-abd-cocoon 1



Dr. TM_peropn-snaps-abd-cocoon 2

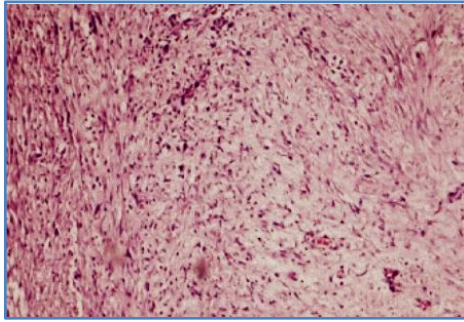


Dr. TM_CECT-abd-cocoon 1

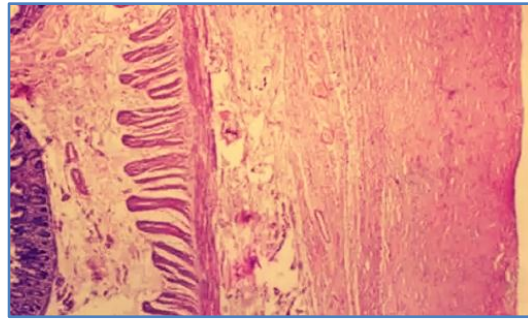


Dr. TM_CECT-abd-cocoon 2

CASE REPORT



Abd_Cocoon-HP slide 1



Abd_Cocoon-HP slide 2

AUTHORS:

1. Tapan Mukherjee

PARTICULARS OF CONTRIBUTORS:

1. Professor, Department of General Surgery, K. P. C. Medical College & Hospital, Jadavpur, Kolkata.

NAME ADDRESS EMAIL ID OF THE CORRESPONDING AUTHOR:

Dr. Tapan Mukherjee,
Swasti Apartments, Pubali,
I/H 15A, Aswininaagar, Baguiati,
Kolkata-700059.
E-mail: drtapan.m@gmail.com

Date of Submission: 26/01/2015.
Date of Peer Review: 27/01/2015.
Date of Acceptance: 29/01/2015.
Date of Publishing: 13/02/2015.