

A VARIED PRESENTATION OF HYPERCOAGULABLE STATE IN PATIENTS WITH PROTEIN 'S' DEFICIENCY

Utkarsh Rajendra Bhattad¹, Rahul Prahlad Ladda², Dhivay Mukesh Bathija³, Anannya Anand Mukherji⁴

¹3rd Year Resident, Department of General Medicine, Dr. D. Y. Patil Hospital, Nerul (East), Navi Mumbai.

²Senior Resident, Department of General Medicine, Dr. D. Y. Patil Hospital, Nerul (East), Navi Mumbai.

³Senior Resident, Department of General Medicine, Dr. D. Y. Patil Hospital, Nerul (East), Navi Mumbai.

⁴Professor, Department of General Medicine, Dr. D. Y. Patil Hospital, Nerul (East), Navi Mumbai.

HOW TO CITE THIS ARTICLE: Bhattad UR, Ladda RP, Bathija DM, et al. A varied presentation of hypercoagulable state in patients with protein 's' deficiency. J. Evid. Based Med. Healthc. 2018; 5(24), 1864-1867. DOI: 10.18410/jebmh/2018/389

PRESENTATION OF THE CASE

Congenital protein S deficiency is an autosomal dominant disease, and the heterozygous state occurs in approximately 2% of unselected patients with venous thromboembolism (VTE). Protein S deficiency is rare in the healthy population without abnormalities. Frequency is approximately one out of 700 based on extrapolations from a study of over 9000 blood donors who were tested for protein C deficiency. When looking at a selected group of patients with recurrent thrombosis or family history of thrombosis, the frequency of protein S deficiency increases to 3-6%. Very rarely, protein S deficiency occurs as a homozygous state, and these individuals have a characteristic thrombotic disorder, purpura fulminans. Purpura fulminans is characterized by small-vessel thrombosis with cutaneous and subcutaneous necrosis, and it appears early in life, usually during the neonatal period or within the first year of life.

Studies have indicated that the prevalence of protein S deficiency is particularly high in the Japanese population. The deficiency is rare in population surveys of Caucasians, at approximately 0.03%.

Protein S is a vitamin K-dependent anticoagulant protein that was first discovered in Seattle, Washington in 1979 and arbitrarily named after that city. The major function of protein S is as a cofactor to facilitate the action of activated protein C (APC) on its substrates, activated factor V (FVa) and activated factor VIII (FVIIIa). Protein S deficiencies are associated with thrombosis.

Protein S deficiency may be hereditary or acquired; the latter is usually due to hepatic disease or a vitamin K deficiency. Protein S deficiency usually manifests clinically as venous thromboembolism (VTE).

Protein S deficiency is a rare inherited thrombophilia often associated with fetal losses in pregnancy. It is seen in approximately 1 in 500 to 1 in 3,000 people. Homozygous Protein S deficiency in neonates manifests as a catastrophic

and fatal thrombotic complication termed Purpura Fulminans (PF).

Pathophysiology

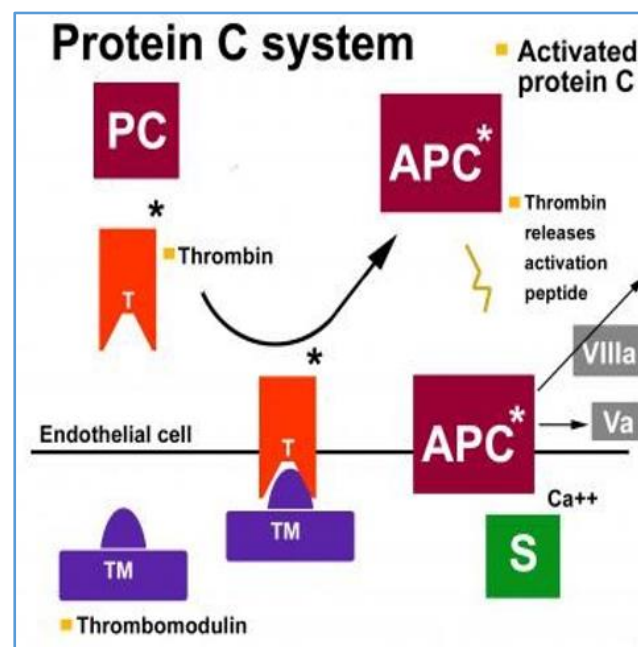


Figure 1

Case No. 1

41 yrs. old presented with complaint of pain in abdomen and constipation since 5 days and 1 episode of high grade fever spike associated with chills, oliguria, high coloured urine. Patient was not associated with chest pain, breathlessness, cold, anuria, cough, palpitations, altered sensorium, loss of consciousness, giddiness, generalised weakness.

CLINICAL DIAGNOSIS

Patient is known case of bronchial asthma on Rota inhaler SOS since 10 years. No history DM, HTN, TB, Thyroid disorders. Past history of inguinal hernia 8 years back.

History of RTA in 2017 bone grafting was done on left radial bone.

Patient is a chronic alcoholic since 13 years 250 ml per week (whiskey).

Smoker 2 cig/day and tobacco chewer 1 pack/day since 10 years stopped since 4 years.

On Examination patient was conscious oriented in time place and person, pulse was 148 bpm with BP of 10/90

Financial or Other, Competing Interest: None.

Submission 26-05-2018, Peer Review 02-06-2018,

Acceptance 09-06-2018, Published 11-06-2018.

Corresponding Author:

Dr. Utkarsh Rajendra Bhattad,

3rd Year Resident, Department of General Medicine,

D. Y. Patil Boy's Hostel,

Nerul (East), Navi Mumbai.

E-mail: ubhattad@gmail.com

DOI: 10.18410/jebmh/2018/389



mmHg, SpO₂ of 96% on RA, RR of 20 /min, I/O 1500/350ml, no SPD. Foleys in situ.

Silent chest, heart sounds heard, no murmur, abdomen was distended, non-tender.

Differential Diagnosis: On Further Investigations

USG Abdomen: Long segment bowel wall thickening in left lumbar region with mild interbowel fluid (non-tappable). Umbilical hernia.

CT-ABDOMEN & PELVIS (PLAIN+CONTRAST) = Mild dilatation of multiple small bowel loops in left half of abdomen (predominantly jejunal), with long segment circumferential wall thickening of jejunal loops in the left lumbar region with marked fat stranding along the mesenteric border and minimal enhancement on post contrast study as described above-Findings are s/o small bowel obstruction with possibility of mesenteric ischaemia (probably venous).

Thrombosis involving right branch of portal vein, main portal vein, portal confluence, right 1/3rd of splenic vein and almost entire superior mesenteric vein.

Left branch of portal vein is not visualized and replaced by multiple collaterals with resultant atrophy of left lobe of liver and caudate lobe hypertrophy.

Mild ascites. Mild to moderate right sided pleural effusion. Non-obstructive left renal calculus.

USG Abdomen: Long segment bowel wall thickening in left lumbar region with mild interbowel fluid. Advice CECT abdomen for further evaluation. Umbilical hernia.

- Target scan for Doppler study.
- Colour flow is noted within main portal vein.
- Colour flow is also noted in splenic vein.
- Respiratory physics appear normal.
- This findings could conclude partial thrombosis /recanalization.
- Right side pleural effusion is noted.

Homocysteine	Above 50	5.46 to 16.2
Anti-thrombin 3 antigen, plasma	94	80 to 120
APA-IgG, APA-IgM, Cardiolipin Antibody ACC IgG	Negative	
Anti-thrombin 3 activity	93	80 to 120
Protein S antigen (free)	101	89 to 120.5
Protein S activity	41	77 to 143
Protein C activity	90	70 to 130
APCR	208.4	<or = 120
APTT	54.6	35.08 to 43.8
DRUV screen	48.5	32.5 to 45.86
DRUV confirm	46.9	31.04 to 40.55
Lupus anticoagulant	Absent	

Table 1

Mesenteric Ischaemia and Portal Vein Thrombosis:

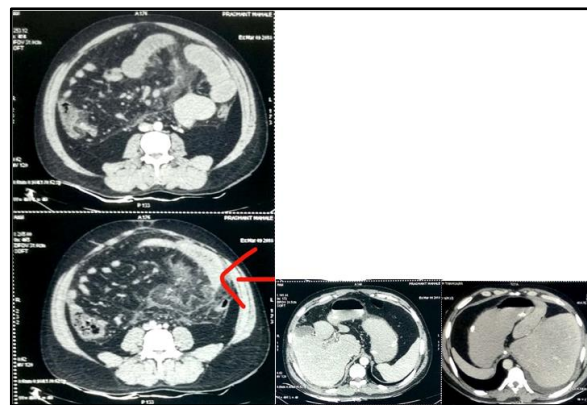


Figure 2

DISCUSSION OF MANAGEMENT

AMI poses a diagnostic difficulty in patients without known risk factors. Portomesenteric vein thrombosis presents with nonspecific signs and symptoms. CECT is the imaging of choice, but no promising diagnostic modality is available in resource-poor setting though abdominal X-ray and Doppler sonography could be helpful despite their own limitations. Often its diagnosis is missed and it gets managed in line with other abdominal conditions like APD, as in our case.

Nepal is a multiethnic country so variation in prevalence of protein S deficiency can be expected, as evidenced by a variable prevalence in Chinese, Japanese and Caucasian population, more so in Mongolian race. The 2012 NICE guideline does not recommend routine testing of hereditary thrombophilia for asymptomatic relatives as a family history of VTE itself poses a risk of thromboembolism, even in the absence of identifiable hereditary thrombophilia. Either a confirmatory second test on the index patient or testing on an asymptomatic relative would not affect the management and prophylaxis, but would be important for academic purposes.

Venous thrombosis causing AMI has a good prognosis than that due to an arterial cause. Kumar et al. in their retrospective study divide mesenteric venous thrombosis (MVT) into large vessel and small vessel thrombosis: large vessel thrombus extends into the portal or splenic vein and has lower risk of progression to bowel infarction; and small vessel thrombus involve isolated mesenteric veins and is more likely to be associated with prothrombotic disease. But our patient with prothrombotic disease had thrombosis of the superior mesenteric vein extending up to the portal vein and its branches.

Management of portomesenteric vein thrombosis is concerned to prevent thrombus extension at an early stage and recurrence at the later stage. Acute phase management addresses resuscitation, antibiotic prophylaxis, and anticoagulation with heparin (unfractionated (UFH) or low-molecular-weight heparin (LMWH)) followed by warfarin targeting an INR of 2–3. Though LMWH is preferable over UFH due to its better safety profile, ease of administration, and not requiring regular lab monitoring; we used UFH infusion as we were concerned about the need of possible laparotomy during the initial days and continued later due to

cost issues to the patient. Surgical management is guided by clinical findings of progression to bowel wall infarction perforation and peritonitis. Advancements in imaging, better understanding of the disease, and early detection of acute MVT has reduced the need for surgical intervention and fatal consequences. Protein S deficiency increases the risk of recurrence in the index patient and the risk of VTE in first-degree relatives. Long-term prophylaxis for recurrent thrombosis is recommended for 6 months, but lifelong prophylaxis in cases where thrombophilia has been identified after the first event of thromboembolism, although this recommendation is not based on evidence. Thromboprophylaxis in high-risk situations for both the index patient and first-degree relatives should be considered.

Case No. 2

26 yrs. old male came to medicine OPD with complaints of Right sided upper and lower limb weakness since today morning Patient was a/a yesterday when had difficulty in lifting his Right hand while having tea in the morning and was not able to lift his Right leg was associated with 1 episode of giddiness. Not associated with LOC, deviation of mouth, trauma, seizure, increased sweating, palpitation, bowel and bladder incontinence, blurring of vision, decreased hearing and loss or decreased sensation.

- No h/o DM/HTN/CVA/Dyslipidemia
- No h/o addiction.
- No h/o allergy.
- No relevant past medical / surgical history.
- On Examination
- P 98 bpm regular in rhythm equal in volume
- Bp 134/80 mmhg taken in right supine position in right arm
- Spo2 of 100% on RA
- HGT 110 mg/dl
- CVS = S1S2 heard, no murmur
- RS=AEBE clear.
- CNS= Concious and oriented
- Power Rt UL 1/5 & Rt LL 2/5
- Reflexes Rt UL and Rt LL Diminished
- Plantars Rt sided Babinski's Positive
- Pupils bilaterally reacting to light.

Phospholipid Ab IgM	3.88	(<10)
IgG	3.97	
Cardiolipin Ab	9.08	(<12.5)
IgM	9.78	
IgG		(<15)
Antithrombin Activity	115	(80-120)
Lupus Anticoagulant	47.9	(36-50)
Protein C	98	(70-140)
Protein S	16.30	(60-130)
ANA	14.57	<20
pANCA(MPO)	1.68	<9
cANCA(PR-3)	2.09	<3.5
Anti-dsDNA	11.72	(<30)

Table 2

MRI Brain

Left middle cerebral artery territory acute non hemorrhagic infarct involving the left high fronto-temporo-parietal lobes, left centrum semiovale, corona radiata, left insular cortex.

Treatment =

- T. Aspirin 150 OD
- T. Atorvastatin 40 HS
- T. Warfarin 5mg at 6pm two hours fasting before and after taking it.
- Chest and Limb physiotherapy.

DISCUSSION

Stroke in young population has a high incidence of approximately 24–35%, according to some studies in India. Abraham et al.¹ from Vellore reported an incidence of 25% in population less than 40 years of age. Muntz et al.² reported that idiopathic coagulation disorders were found in about a quarter of young stroke patients, although the clear-cut data has been lacking from India. Carod-A et al.³ studied about ischemic stroke subtypes and prevalence of thrombophilia in Brazilian stroke patients. They examined 130 consecutive young and 200 elderly patients. Prevalence of thrombophilia was, respectively: protein S deficiency (11.5% versus 5.5%), protein C deficiency (0.76% versus 1%). They concluded that prothrombotic conditions were more frequent in stroke of undetermined causes.

The importance of thrombophilic disorders in arterial stroke has been debatable. Ischemic stroke has been reported as a rare manifestation of protein S deficiency. Girolami et al.⁴ and Sie et al.⁵ were among the first who reported the association of familial deficiency of protein S as a cause of ischemic stroke in young. Wiesel et al.⁶ studied 105 patients with protein S deficiency, out of which 14 had arterial thrombotic accidents involving the central nervous system or the myocardium, while most studies revealed a weaker association between the two.⁷⁻⁹ Douay et al.⁸ reported that hereditary deficiencies of coagulation inhibitors are rare in ischemic stroke patients under 45 years and their systematic detection seems to be of poor interest. Mayer et al.⁹ also supported the fact that acquired deficiency of free protein S is not a major risk factor for ischemic stroke.¹⁰⁻¹³

Case No. 3

24 year old female G2A1 39 weeks by date came for safe confinement with complaints of diplopia and unilateral headache since 3 days.

- Not associated with any limb weakness/seizures/facial deviation/trauma/LOC.
- NO h/o DM/HTN/Seizure disorder/Dyslipidemia.
- H/O one abortion in the past 1 year back at 12 weeks
- No other relevant medical /surgical history.
- On Examination
- P 84 bpm regular in rhythm and equal in volume
- BP 110/60 mmHg taken in right supine position in right arm
- CVS=S1S2 heard, no murmur
- RS=AEBE clear

- P/A=Gravid
- CNS=Conscious and oriented
- USG Obts SLIG of 38th week, cephalic position, AFI 14-15cm, EFW=3675, Normal Doppler study.
- Fibrinogen: 230 mg/dl
- #FDP: 800 ng/ml (0-200)
- D.Dimer: 1660 (0-500)
- BT/Ct: 1 min 30 s/ 3 min 40 s (4-9min)
- PT/INR = 10.6/0.88

Protein S activity	Below 8	Non-Pregnant: 57-123 Trimester: 57-95 Second Trimester: 42-68 Third Trimester: 16-42
Protein c activity	127	Non-Pregnant: 70-130 Trimester 78-121 Second Trimester: 83-133 Third Trimester: 67-135
Table 3		

MRI Brain plain = No significant abnormality detected.

Treatment

After caesarian section baby was delivered and patient was started on T. Dabigatran 250 bd.

FINAL DIAGNOSIS

Protein S deficiency is a rare inherited thrombophilia with autosomal dominant inheritance.¹ Protein S is a vitamin-K-dependent natural anticoagulant protein. It functions as a cofactor to facilitate the action of activated protein C on factors Va and VIIIa. Neonatal PF is a manifestation of homozygous Protein S or Protein C deficiency. It is a lethal syndrome of disseminated intravascular coagulation with rapidly progressive hemorrhagic necrosis of the skin due to dermal vascular thrombosis.² Pregnant women with Protein S deficiency are typically heterozygous. Partners of women with these defects should be offered screening to identify neonates who may be homozygous or carry combined defects, in whom prenatal diagnosis can be considered. Women with genetic or acquired thrombophilia are at very high risk of antenatal and postpartum venous thromboembolism and should receive thromboprophylaxis during pregnancy and puerperium.^{3,4} Subcutaneous unfractionated or low molecular weight heparins (LMWH) are the anticoagulants of choice. Heparin does not cross the placenta, and thus there is no risk of teratogenesis or fetal haemorrhage. LMWH is the drug of choice because of a better side-effect profile, (reduced risk of osteopenia and thrombocytopenia) good safety record for mother and fetus, and convenient once-daily dosing for prophylaxis. Warfarin is associated with teratogenic effects and should be avoided in pregnancy. Regional analgesia is avoided for at least

12 hrs after the last dose of LMWH.³ Postpartum after 24 h, women should resume warfarin with LMWH overlap until the INR is in the pre-pregnancy therapeutic range.^{3,4} Heparin and warfarin can be safely administered to nursing mothers.^{1,4} In conclusion, thrombophilia screening might be justified in women with recurrent pregnancy loss.⁵ Adequate and appropriate thromboprophylaxis is an important part of the management of pregnant women with inherited thrombophilias.⁴

REFERENCES

- [1] Llovera I, Roit Z, Kiriaki S, et al. Mesenteric ischemia and protein S deficiency: a rare case report. J Emerg Med 2010;39(5):579-582.
- [2] Ludwig DJ, Hauptmann E, Rosoff L, et al. Mesenteric and portal vein thrombosis in a young patient with protein S deficiency treated with urokinase via the superior mesenteric artery. J Vasc Surg 1999;30(3):551-554.
- [3] Castoldi E, Hackeng TM. Regulation of coagulation by protein S. Curr Opin Hematol 2008;15(5):529-536.
- [4] Marlar RA, Gausman JN. Protein S abnormalities: a diagnostic nightmare. Am J Hematol 2011;86(5):418-421.
- [5] Aneja R, Heard C, Petruzzese MJ, et al. Protein S deficiency manifesting as spontaneous aortic thrombosis in a neonate. Pediatr Crit Care Med 2002;3(1):81-83.
- [6] Broekmans AW, van Rooyen W, Westerveld BD, et al. Mesenteric vein thrombosis as presenting manifestation of hereditary protein S deficiency. Gastroenterology 1987;92(1):240-242.
- [7] Rose PG, Essig GF, Vaccaro PS, et al. Protein S deficiency in pregnancy. Am J Obstet Gynecol 1986;155(1):140-141.
- [8] Cherian A, Thomas SV. Review: management updates (reviews on advances in treatment). Ann Indian Acad Neurol 2009;12(3):140-153.
- [9] Carod-Artal FJ, Nunes SV, Portugal D, et al. Ischemic stroke subtypes and thrombophilia in young and elderly stroke patients admitted to a rehabilitation hospital. Stroke 2005;36(9):2012-2014.
- [10] Bergqvist D, Svensson PJ. Treatment of mesenteric vein thrombosis. Semin Vasc Surg 2010;23(1):65-68.
- [11] Lalan DM, Jassawalla MJ, Bhalerao SA. Successful pregnancy outcome in a case of protein s deficiency. J Obstet Gynaecol India 2012;62(Suppl 1):21-22.
- [12] Buchanan GS, Rodgers GM, Branch DW. Best Pract Res Clin Obstet Gynaecol 2003;17(1):75-92.
- [13] Bowles L, Cohen H. Inherited thrombophilias and anticoagulation in pregnancy. Best Pract Res Clin Obstet Gynaecol 2003;17(3):471-489.