

A STUDY ON ORBITAL WALL FRACTURES AND ITS OUTCOME

Latha K. S. T¹, Vasumathi K², Waheedanazir³, Pavithra Paneerselvam⁴, Kalpana Vanganoor Mani⁵, Anuradha Alagusundaram⁶, Sujatha Rajendran⁷

¹Senior Assistant Professor, Department of Ophthalmology, Regional Institute of Ophthalmology and Government Ophthalmic Hospital, Chennai.

²Assistant Professor, Department of Ophthalmology, Regional Institute of Ophthalmology and Government Ophthalmic Hospital, Chennai.

³Professor, Department of Ophthalmology, Regional Institute of Ophthalmology and Government Ophthalmic Hospital, Chennai.

⁴Junior Resident, Department of Ophthalmology, Regional Institute of Ophthalmology and Government Ophthalmic Hospital, Chennai.

⁵Junior Resident, Department of Ophthalmology, Regional Institute of Ophthalmology and Government Ophthalmic Hospital, Chennai.

⁶Assistant Professor, Department of Ophthalmology, Regional Institute of Ophthalmology and Government Ophthalmic Hospital, Chennai.

⁷Assistant Professor, Department of Ophthalmology, Regional Institute of Ophthalmology and Government Ophthalmic Hospital, Chennai.

ABSTRACT

BACKGROUND

The main aim of this study is to evaluate Orbital Wall Fractures and its outcome (improvement of diplopia and enophthalmos) following treatment.

METHODS OF EVALUATION

It was a prospective study conducted at Orbit and Oculoplasty services at tertiary eye care centre in which 30 patients presented with blowout fractures for a period of 12 months were analysed.

RESULTS

Out of 30 patients, 24 patients (80%) were treated conservatively and 6 patients (20%) were treated surgically. Out of 24 conservatively treated patients, 23 patients (96%) had satisfactory results and out of 6 surgically treated patients, 4 patients (66%) had satisfactory results with respect to diplopia and enophthalmos.

CONCLUSION

The management of blowout fractures depend upon the fracture size, herniation of orbital contents, muscle entrapment and diplopia. Most of the fractures were managed conservatively. The outcome of the blowout fracture is good, if treated within 7-10 days.

KEYWORDS

Blowout fracture, Diplopia, Ocular Movement Restriction and Visual Outcome.

HOW TO CITE THIS ARTICLE: Latha KST, Vasumathi K, Waheedanazir, et al. A study on orbital wall fractures and its outcome. J. Evid. Based Med. Healthc. 2016; 3(74), 4006-4012. DOI: 10.18410/jebmh/2016/856

INTRODUCTION: "The term "blowout fracture" of the orbit refers to a specific syndrome in which the orbital floor fracture occurs on its own without a fracture of the orbital rim usually as a result of a blow from the front impinging on the soft tissues of the orbit".

(Sir. Stewart Duke Elder in System of Ophthalmology Vol. XIV Part 1, Mechanical Injuries, 1972).¹ Blowout fracture is caused by an object greater than the orbital diameter, which leads to sudden increase in the orbital pressure. The force is transmitted to the thin orbital floor and medial wall since the lateral wall and roof can withstand such trauma. Orbital floor fractures alone or in conjunction with other facial skeletal fractures are the most commonly encountered midfacial fractures, second only to nasal fractures. In India, violent assaults (with fist and elbow) and RTA are the most common mode of injuries. It tends to occur more often in males than females. Blowout fractures can be divided into Pure and Impure fractures.²

Pure Type: Fracture of the orbital wall (floor and/or medial wall, rarely roof) without involvement of the orbital rim.

Financial or Other, Competing Interest: None.

Submission 19-08-2016, Peer Review 27-08-2016,

Acceptance 09-09-2016, Published 14-09-2016.

Corresponding Author:

Dr. Latha K. S. T,

Senior Assistant Professor,

Department of Ophthalmology,

Regional Institute of Ophthalmology and Government Ophthalmic Hospital, Egmore-600008, Chennai.

E-mail: drkstlatha@gmail.com

DOI: 10.18410/jebmh/2016/856



Impure Type: Fracture of the orbital wall with the involvement of the orbital rim (Zygoma, Maxillary bone, Frontal bone).

Blow-In Fractures: It is an unusual type of orbital fracture where the fractured fragments project into the orbit.

Types of Blowout Fractures:

1. **Linear Fractures:** Fracture lies just parallel and medial to the inferior orbital groove.
2. **Trap Door Fractures:** Fractured segment of the orbital floor separates transiently and springs down at the time of impact. When returning almost to its original position after the impact it entraps the muscles and soft tissue in the process. It is very common in children.
3. **Hinged Fractures:** Fracture occurs along the inferior border of the ethmoid entering the maxillary sinus.
4. **Comminuted Fractures:** Combination of all the above fractures.
5. **Saucer-Shaped Fractures:** Following fracture of the bone, the overlying periosteum maybe intact, producing smooth-saucer shaped depression. So, the orbital tissue cannot get trapped in this type.

Orbital Medial Wall Fracture: These fractures most commonly occur in conjunction with floor fractures. Isolated fractures are less common. The complications of these fractures include orbital emphysema, medial rectus entrapment, and epistaxis. If the medial wall fracture is large, it needs surgical intervention.

Orbital Roof Fracture: It involves the frontal sinus and intracranial structures. Commonly occurs following the RTA and fall from height. Complications include CSF rhinorrhoea, intracranial haemorrhage, pulsatile ptosis, encephalocele, meningitis and brain abscess. These complicated fractures need neurosurgical and/or otorhinolaryngological consultation.

Orbital Apex Fracture: It occurs alone or in association with facial injuries, traumatic optic neuropathy, CSF rhinorrhoea and Caroticocavernous Fistula (CCF).

Nasal-Orbital-Ethmoid Fracture (NOE): Here nasal bones and the thin ethmoidal bones are fractured with resultant traumatic telecanthus and flattened nasal bridge. Early open repair with precise reduction and stabilisation of bone fragments will be done by orofaciomaxillary surgeon.

Mid Facial fractures: It is divided into 3 types:

- Le Fort I (Guerin): Here, the tooth bearing portion separated from the upper maxilla. No orbital involvement.
- Le Fort II: Fracture across the orbital floor and nasal bridge (pyramidal fracture).

- Le Fort III: Fracture across the frontozygomatic suture line, entire orbit and the nasal bridge (Craniofacial Separation).

Around 80% of the fractures commonly occur in the posterior part of orbital floor medial to the infraorbital groove and canal. The reasons are:

- i. Extremely thin bone at this site.
- ii. Upwardly inclined bone of the posterior orbital floor, which lies close proximity to the globe.
- iii. The fracture site lies directly beneath the geometrical axis of orbit. Two theories explain the mechanism of orbital blowout fracture.³

1. The Hydraulic Theory by Smith and Regan: When a blunt object (which is spherical and larger than the orbital base) hits the orbit, the globe and the soft tissues will be repulsed suddenly increasing the orbital pressure. To relieve this pressure, the thinnest orbital wall blows out usually medial to the infraorbital canal into the maxillary sinus. The medial wall sometimes gives way due to its fragility. This is considered as a safety mechanism of globe.

2. The Buckling Theory by Fujino: When a blow strikes the inferior orbital rim, the rim is displaced posteriorly and the force will be transmitted to the thin orbital floor, which buckles and fracture into the maxillary sinus. Then, the inferior rim returns back to its normal position intact.

Management of Orbital Wall Fractures: Conservative Management: Majority of the orbital wall fractures do not need surgical intervention and or treated conservatively by observation for 7-10 days with oral antibiotics, nasal decongestants and local ice compression. Oral steroids (Tab. Prednisolone 1 mg/kg) can be given to reduce oedema and to decrease the fibrosis. Patient should be instructed not to blow the nose.

1. Small cracks without any herniation don't require treatment since the risk of complications is less.
2. Fractures less than one-third of orbital floor without herniation or enophthalmos with improving diplopia can be left untreated.

Surgical Management:

Aims:

1. Prevention of vertical diplopia.
2. Prevention of unacceptable Enophthalmos.

Indications for Surgical Repair:

1. Restricted ocular motility showing no improvement with conservative treatment for one week.
2. Diplopia within central 30'.
3. Enophthalmos >2 mm.
4. Evidence of entrapment of orbital contents with confirmation by forced duction test.

5. Fractures with risk of developing future enophthalmos.
 - i. Large fractures of floor and/or medial wall.
 - ii. Combined medial wall and floor fractures.
6. Blow-in fracture.
7. Complex and comminuted fractures.

Urgent Surgical Interventions:

1. **'White-Eyed' Fracture or Trap Door Fracture:**
Usually occurs in less than 18 years old without any external soft tissue injury in orbital floor fracture. These patients may present with nausea, vomiting, bradycardia and heart block due to 'oculocardiac reflex'. Surgery is indicated within 24-72 hours to prevent the ischaemic necrosis of inferior rectus and oculocardiac reflex.
2. Early marked enophthalmos.

Criteria for Surgical Intervention: Every patient who has sustained a blunt orbital injury should be followed with sequential exophthalmometry readings. Initial exophthalmos secondary to orbital oedema and haemorrhages will subside and may unmask enophthalmos. Enophthalmos may develop late, months after the traumatic episode; it will often result in marked superior sulcus defects and significant cosmetic deformities. It is extremely difficult to correct enophthalmos and deep superior sulcus. Diplopia in the primary and reading position is debilitating. Diplopia in extreme gaze is often little significance. Diplopia should be quantitated with Hess charting. Forced duction test clearly differentiates an entrapped or fibrotic muscle from paretic muscle. After 3-4 weeks, the orbital floor will probably have healed with fibrous sheets bridging the defect and incorporating the entrapped muscle.⁴

Timing for the Surgery: The ideal time is not beyond 2 weeks. Late surgeries can be complicated by orbital fat atrophy and shortening of extraocular muscles.⁵

Types of Approaches to Orbital Floor:

1. Transconjunctival approach.
2. Transcutaneous.
3. Transantral.

Graft Materials: Autologous:

- Nasal septal cartilage.
- Auricular cartilage.

Bones:

- Anterolateral maxillary sinus.
- Iliac crest.
- Ribs.
- Cranial bone.
- Symphyseal bone.
- Alloplastic.

Porous:

1. Hydroxylapatite.
2. Porous polyethylene (Medpor).

Nonporous:

1. Supramid.
2. Teflon.
3. Silastic (Silicone) Sheet.
4. Metallic Sheet.
 - Methyl Methacrylate.
 - Titanium Mesh.
 - Tantalum Orbital Plate.
5. Vitallium.

Absorbable Material:

1. Lyophilized tensor fascia lata.
2. Polymerized polylactide.
3. Polyglycolic acid membrane.

Experimental work was done on Bone Morphogenetic Protein (BMP) implant with and without Platelet-Rich Plasma (PRP) is supposed to promote the fracture consolidation in orbital fractures treatment with minimal inflammation. It may be a good alternative in orbit fracture reconstruction.⁵

Complications after Orbital Floor Repair:

Early:

1. Infection.
2. Bleeding.
3. Loss of vision.
4. Diplopia.
5. Optic nerve compression at the orbital apex.

Late: Usually related to orbital implant:

1. Infection.
2. Migration.
3. Extrusion.
4. Inclusion cyst.
5. Proptosis.
6. Maxillary sinus fistula.

Management of Late Sequelae of Blowout Fractures:

1. Late Persistent Diplopia: Diplopia on primary gaze and reading gaze is the interference for the patient. Muscle surgery is advocated once the diplopia and the motility are stabilised. The goal of the corrective extraocular muscle surgery is orthophoria in the primary position and as much expansion of the binocular field as possible. Hypotropia in the primary position with limitation of elevation can be alleviated by 'L' tenotomy or recession of the involved inferior rectus. If upgaze is limited or up and down gaze is limited, but the eyes are in primary position, recessions of inferior and superior rectus can be done. If down gaze is limited with eyes in primary position, then a posterior fixation of contralateral inferior rectus (Faden procedure) can be advocated leaving the primary position undisturbed.

2. Hypophthalmos: The vertical misalignment of the eyes with inferior displacement secondary to floor fractures and disruption of the orbital suspensory

ligaments can be partially corrected by augmenting the orbital floor with supramid sheets, bone grafts. The implant should be thicker and anterior. The more anterior, the implant is placed, the more it reduced hypophthalmos, the more posterior the implant is placed, the more it reduced enophthalmos.

3. Enophthalmos: It is the most difficult to correct adequately if useful vision is to be preserved. Deep superior sulcus volume augmentation can be done. Soft tissue fillers like autologous fat, cross-linked collagen (Zyplast), self-inflating hydrogel pellets have been tried. Contralateral upper lid blepharoplasty maybe an effective adjunct technique.

AIM OF THE STUDY: To evaluate the orbital wall fractures and its outcome (improvement of diplopia and enophthalmos) following the treatment.

OBJECTIVES:

1. To analyse the incidence, mode of injury, various clinical presentations, mode of treatment and the visual outcome in patients who presented with orbital wall fractures.
2. To assess the extraocular movements and diplopia status following treatment.

MATERIALS AND METHODS:

Inclusion Criteria:

1. Patients presenting with orbital wall (blowout) fractures.
2. Age 12-65 years.

Exclusion Criteria:

1. Patient with no light perception in the injured eye.
2. Patient with pre-existing defective vision prior to trauma due to other causes.
3. Associated comminuted facial bone fractures.
4. Age <12 years.

A detailed history of the present illness, mode of injury and the time interval between the injury and admission was obtained. Detailed history regarding diplopia, epistaxis and infraorbital anaesthesia were also obtained. Slit lamp examination and dilated fundus examination were done. Radiological imaging was analysed. Patients was managed according to their presentation by either conservative treatment or surgical intervention. Best Corrected Visual Acuity (BCVA), extraocular movements and diplopia status were measured during presentation and followup period.

Management: The aim of the treatment is to prevent the permanent vertical diplopia and/or cosmetically unacceptable enophthalmos.

The factors that determine the risk of the late complications are fracture size, herniation of orbital contents into the maxillary sinus and muscle entrapment.

Categorisation of Orbital Floor Fractures:

1.	Small fractures without any herniation do not require treatment as the risk of permanent complications are less.	Treated conservatively
2.	Fractures involving less than one-third of the orbital floor, with little or no herniation, with no significant enophthalmos and diplopia, also do not require treatment.	
3.	Fractures involving more than one-third of the orbital floor will usually develop significant enophthalmos if left untreated.	Treated surgically
4.	Fractures with entrapment of orbital contents, enophthalmos of >2 mm, and significant diplopia in the primary position should be repaired within 2 weeks. If surgery is delayed, the results are less satisfactory due to secondary fibrotic changes.	

Conservative Treatment:

1. Oral antibiotics, nasal decongestants and local ice compression.
2. Oral steroids (Tab. Prednisolone 1 mg/kg) to reduce oedema and to decrease the fibrosis.
3. Patient was instructed not to blow the nose.
4. Traumatic optic neuropathy was treated with Inj. Methylprednisolone 500 mg IV b.d. for 3 days followed by oral Tab. Prednisolone 1 mg/kg for 11 days. Daily assessment of fields, colour vision was done.

Surgical Management: Indications for Surgery:

- Diplopia in functional gaze (within 30 degree of primary or in down gaze).
- Enophthalmos >2 mm.
- Large fractures (>10 mm).
- Positive FDT.

Patients were managed according to their presentation and imaging by either conservative treatment or surgical intervention.

Followup: The patients were followed up at 1 week, 2nd week, 3rd week and 4th week. During the followup period, Best Corrected Visual Acuity (BCVA), extraocular movements and diplopia status were measured.

RESULTS: Out of 30 patients, 24 patients (80%) were treated conservatively and 6 patients (20%) were treated surgically.

Out of 24 conservatively treated patients, 23 patients (96%) had satisfactory results and out of 6 surgically treated

patients, 4 patients (66%) had satisfactory results with respect to diplopia and enophthalmos.

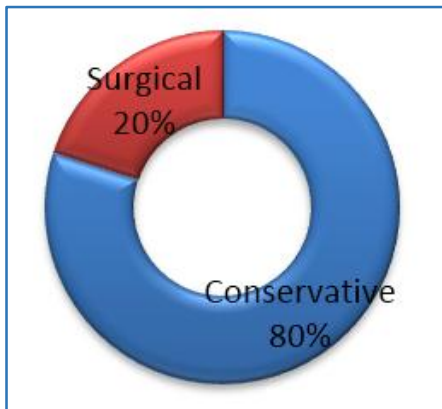


Chart 1: Showing Type of Management

In our study, the P value for the overall satisfactory level of the management was <0.05 (0.0379), which is statistically significant.

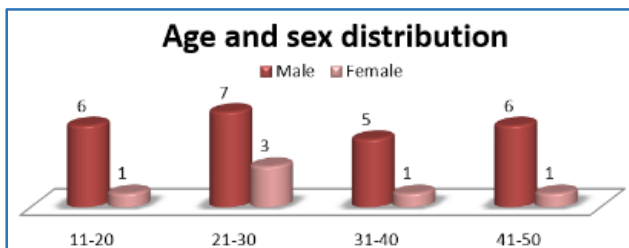


Chart 2: Showing Age Analysis and Sex with Male Preponderance in the Age Group of 11-40 yrs.⁶

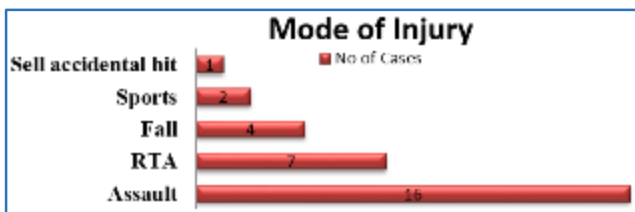


Chart 3: Bar Diagram Representing Mode of Injury

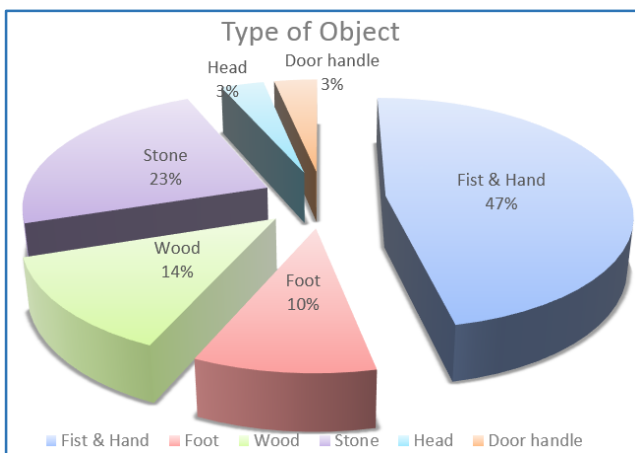


Chart 4: Showing Mode of Object Causing Injury

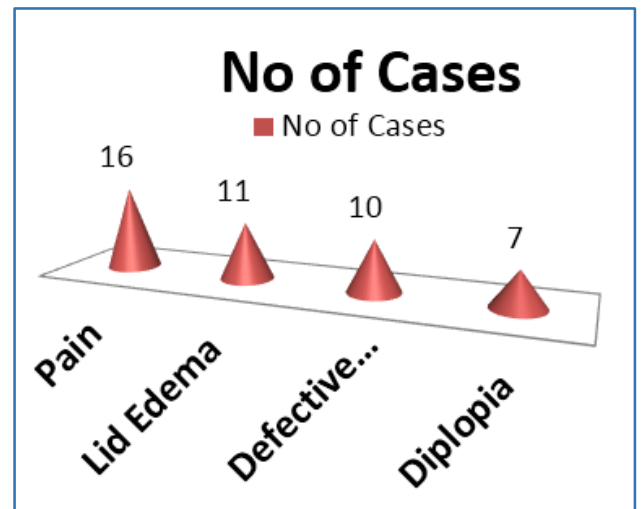


Chart 5: Presenting the Distribution of Symptoms.⁷

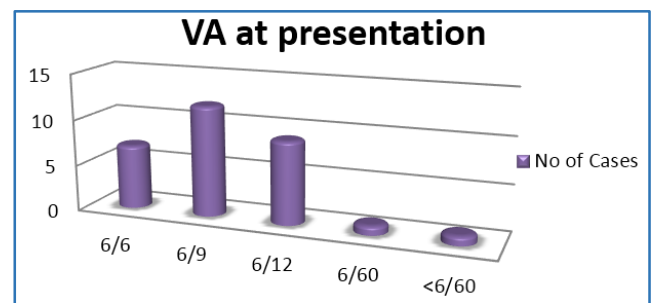


Chart 6: Showing Visual Acuity at the Time of Presentation

Time of Presentation:

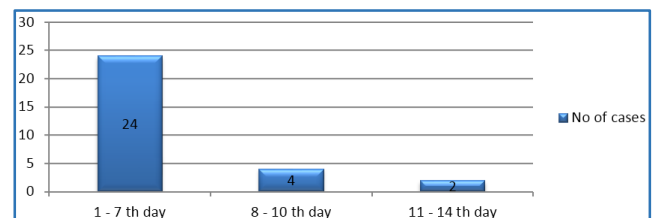


Chart 7: Bar Chart Showing the Time of Presentation

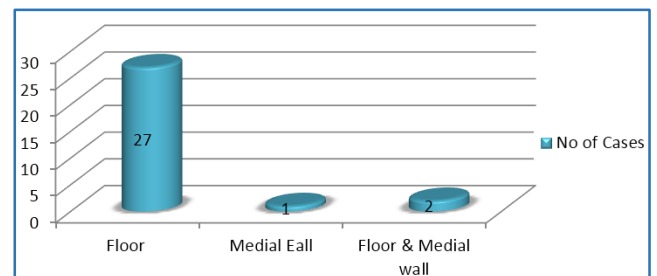


Chart 8: Bar Chart Shows the Type of Wall Distribution.⁸

In our study, out of 30 cases of pure blowout fractures.

No. of Cases	Type of Fracture	Treatment	Results
14	Small Fracture without any Herniation.	Conservative	All Patients had Satisfactory Results.
10	Small Fractures (Less than One-Third of the Orbital Floor), with Little or no Herniation, without any Enophthalmos and Rapidly Improving Diplopia.	Treated Medically and Kept Observation for 7-10 days.	9 Patients had Satisfactory Results. Surgical Exploration was warranted in the Remaining one patient.
6	Large Fracture With Significant Diplopia in the Primary Position and Enophthalmos.	Surgically Treated.	4 patients (67%) had Satisfactory Results. The remaining 2 patients (33%) had Unsatisfactory results.

In total, conservative approach was adopted to 80% of the patients (24) with resolution of diplopia due to reduction in orbital oedema and haemorrhage. In total, surgical intervention was done for 7 patients.

Type of Approach: Out of 7 patients, transconjunctival approach was done in 5 patients and subciliary approach was done in 2 patients. All 7 patients were managed with titanium mesh.⁹

Best Corrected Visual Acuity Following Treatment:

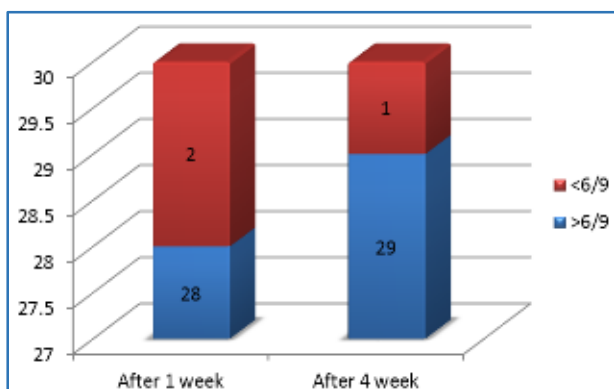


Chart 9: Bar Chart Shows the Analysis of Visual Acuity Results after Treatment

Diplopia: In this study, 23.3% (7) patients presented with diplopia. After treatment, out of 30, 3 patients (10%) had persistent diplopia.

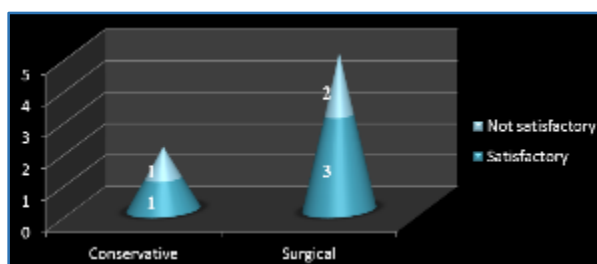


Chart 10: Shows Analysis of Treatment of Diplopia and its Results

Ocular Motility Restriction: 16 patients (53.3%) presented with restricted ocular movement. After management, 81% (13) patients showed improvement in

ocular movement. The remaining 3 (9%) patients had unsatisfactory results.

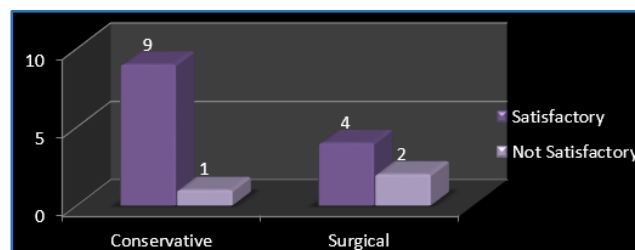


Chart 11: Bar Chart Shows Ocular Motility Restriction Results

In this study, following treatment, out of 30 patients, 27 patients (90%) showed satisfactory results. 3 patients (10%) had unsatisfactory results.

Satisfactory Results	Enophthalmos <2 mm
	No diplopia
Not Satisfactory Results	Enophthalmos >2 mm
	Significant diplopia in primary position and/or within 30 degrees on vertical movements and downward gaze

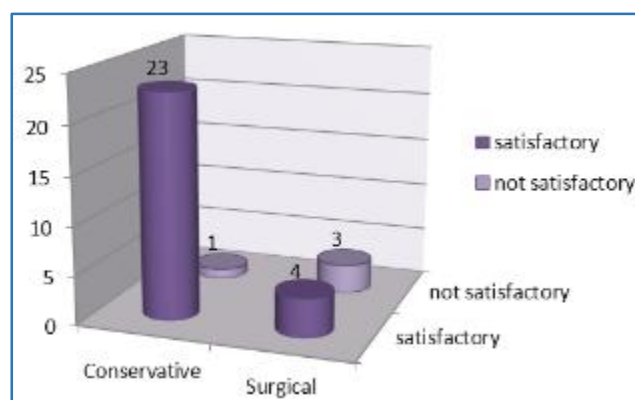


Chart 12: Bar Chart Shows Results of Conservative and Surgical Management

Out of these 3 unsatisfactory patients, one was treated conservatively, surgical exploration was warranted in these one patient. The remaining 2 unsatisfactory patients who underwent surgery presented after 12 days injury with enophthalmos and significant diplopia.¹⁰

DISCUSSION:

1. Orbital floor fractures were treated according to size, type, muscle entrapment and involvement of diplopia and enophthalmos.
2. Persistent diplopia and ocular motility restriction was found in the patients who presented late with the need of surgical exploration.
3. Surgical intervention within 7-10 days gives good result.

CONCLUSION: The goal of the treatment of orbital blowout fracture is restoration of orbital volume and its integrity. Its management depend upon the fracture size, herniation of orbital contents into the maxillary sinus, muscle entrapment and diplopia. Most of the fractures are managed conservatively. The outcome of the blowout fracture regarding diplopia and enophthalmos is good if the time of intervention is within 7-10 days.¹⁰ All patients sustaining blowout fractures with associated reduction in visual acuity, enophthalmos and diplopia should be reported to ophthalmologist as early as possible for complete ophthalmic assessment and early treatment initiation for the better outcome.

REFERENCES

1. Elder DS. Mechanical injuries. In: System of ophthalmology. Part 1. Vol 14. CV Mosby St. Louis 1972.
2. Peyman GA. Principles and practice of ophthalmology vol 3. 1st edn. Saunders 1980.
3. Rootman J. Part-C-Structural Lesions. In: Diseases of orbit: a multidisplinary approach. 2nd edn. Lippincott Williams and Wilkins 2002.
4. Holck DEE. Evaluation and treatment of orbital fracture: a multidisplinary approach. Elsevier Saunders 2006.
5. Albert DM, Jakobiec FA. Principles and Practice of ophthalmology. 3rd edn. WB Saunders Co 2000.
6. Hwang K, You SH, Sohn IA. Analysis of orbital bone fractures: a 12 - year study of 391 patients. Journal of Craniofacial Surgery 2009;20(4):1218-1223.
7. Shin JW, Soo J. An analysis of pure blow: out fracture & associated ocular symptoms. Journal of Cranio Facial Surgery 2013;24(3):703-707.
8. Kamath SJ, Kamath MG, Kamath MM, et al. A study of orbital fractures in a tertiary health care centre. Online Journal of Health and Allied Sciences 2007;6(1).
9. Ellis E, Tan Y. Assessment of internal orbital reconstructions for pure blowout fractures: cranial bone grafts versus titanium mesh. American Association of Oral and Maxillofacial surgery Journal 2003;61(4):442-453.
10. Courtney DJ, Thomas S, Whitfield PH. Isolated orbital blow out fractures: survey and review. Br J Oral and Maxillofacial Surg 2000;38(4):496-502.