

A Study on Cytoclinical Correlation in Immunobullous, Spongiotic, and Viral Vesicular Skin Lesions

Simi John¹, Celine Machiyanickal Issac², Sadeep Melathil Sadanandan³, Sobhanakumari Kunjumani⁴

¹Assistant Surgeon, Department of Dermatology, Gandhigram Government Hospital, Koratty, Kerala.

²Associate Professor, Department of Dermatology, Government TD Medical College, Alappuzha, Kerala. ³Professor, Department of Dermatology, Mount Zion Medical College, Adoor, Kerala.

⁴Professor, Department of Dermatology, Government TD Medical College, Alappuzha, Kerala.

ABSTRACT

BACKGROUND

Tzanck smear serves as a primary diagnostic method in diseases like immunobullous disorders, viral blisters, candidiasis, Hailey-Hailey disease, Darier disease, toxic epidermal necrolysis and cutaneous neoplasms. The aim of the study was to investigate the correlation between cytoclinical, histopathology and immunofluorescence findings in chronic immunobullous diseases and to study the sensitivity of Tzanck smear findings in chronic immunobullous diseases, viral vesicular lesions, and spongiotic dermatitis.

METHODS

181 patients with chronic immunobullous diseases, spongiotic and viral vesicular skin lesions who attended the department of Dermatology and Venereology between April 2013 to October 2014 in our tertiary care centre were studied.

RESULTS

Out of 181 patients studied, 66 cases were chronic immunobullous diseases, 65 cases were viral vesicular lesions and 50 cases were eczema. Tzanck smear showing acantholytic cells in pemphigus vulgaris has a sensitivity of 93.75%. For pemphigus foliaceus and pemphigus vegetans sensitivity was 100%. Direct immunofluorescence (DIF) was 100% sensitive for pemphigus vulgaris and histopathology and DIF correlated in 100%. Tzanck smear with eosinophils correlated with clinical diagnosis of bullous pemphigoid in 70% cases, while histopathology correlated in 100% and DIF positivity was in 95% cases. Tzanck smear has a sensitivity of 70.77% in herpetic infections, 75% in allergic contact dermatitis and 72.72 in irritant contact dermatitis.

CONCLUSIONS

In chronic immunobullous diseases, Tzanck smear helps the dermatologist to make a primary diagnosis with ease and rapidity without much discomfort to the patient. Though the sensitivity of Tzanck smear in viral infections is low, it can be performed which can narrow down the list of differential diagnosis.

KEYWORDS

Tzanck Smear, Immunobullous Diseases, Spongiotic Blisters, Viral Vesicles

Corresponding Author:

*Dr. Celine M. I.,
Associate Professor,
Department of Dermatology,
TD Medical College,
Alappuzha, Kerala.
E-mail: dr.miceline@gmail.com
DOI: 10.18410/jebmh/2020/26*

*Financial or Other Competing Interests:
None.*

How to Cite This Article:

John S, Issac CM, Sadanandan SM, et al. A study on cytoclinical correlation in immunobullous, spongiotic, and viral vesicular skin lesions. J. Evid. Based Med. Healthc. 2020; 7(3), 122-127. DOI: 10.18410/jebmh/2020/26

*Submission 23-12-2019,
Peer Review 27-12-2019,
Acceptance 10-01-2020,
Published 15-01-2020.*



BACKGROUND

Diagnostic cytology for cutaneous diseases became popular by the middle of twentieth century when Arnault Tzanck used the cytology for the diagnosis of vesiculobullous disorders particularly herpes simplex. Since then cytology has been widely used by dermatologists for diagnosing various cutaneous dermatoses.¹ Tzanck smear serve as a primary diagnostic aid in diseases like pemphigus, bullous pemphigoid, herpes simplex, varicella, herpes zoster, molluscum contagiosum, pustular or bullous superficial fungal infections like candidiasis, leishmaniasis, Hailey Hailey disease, Darier disease, staphylococcal scalded skin syndrome, toxic epidermal necrolysis, cutaneous neoplasms like basal cell carcinoma, squamous cell carcinoma, Paget disease, erythroplasia of Queyrat, mastocytoma, histiocytosis X.¹ Although not a substitute for standard histology, in the hands of an experienced dermatologists Tzanck smears can aid in establishing the clinical diagnosis with ease and rapidity and can serve as an adjunct to routine histologic study. The technique is cheap and easy to perform and does not cause any discomfort to the patient.^{1,2} In this prospective study, we aimed to describe the Tzanck smear findings in patient with chronic immunobullous diseases, viral vesicular lesions and spongiotic dermatitis like eczemas with vesicles or erosions. In addition, we have evaluated the clinical, histological and immunofluorescence features of chronic immunobullous diseases in our study sample.

METHODS

This study is a descriptive study. All patients with chronic immunobullous diseases, spongiotic (eczema only) and viral vesicular skin lesions attending the Department of Dermatology & Venereology of govt. Medical College, Kottayam were taken during the period from April 2013 to October 2014. Those not willing to participate in the study and those patients who have taken prior treatment for their disease either orally or topically were excluded. An approval from institutional review board for ethics committee was obtained. After getting informed consent from the patient, history was taken in detail and clinical examination carried out and at the end of which a provisional diagnosis was made. After that Tzanck smear was taken. The slide was fixed immediately with absolute alcohol and stained with rapid Haematoxylin & Eosin stain. After staining, the slide was examined under oil immersion microscope. To substantiate the diagnosis, the patient was followed up with relevant investigations like biopsy and DIF. Sensitivity of Tzanck smear findings in each disease studied was assessed. The degree of correlation between Tzanck smear, histopathology and DIF findings were also done.

Data was entered in Excel and statistical analysis performed using Microsoft Excel and statistical package for social science (SPSS) for Windows.

RESULTS

66 patients with chronic immunobullous diseases, 65 cases of viral infections and 50 cases of eczemas were taken for the study. In chronic immunobullous diseases, Pemphigus vulgaris contributed to the maximum number of patients with 48.48% cases followed by bullous pemphigoid in 30.3% cases. Dermatitis herpetiformis, linear IgA disease. Chronic bullous disease of childhood, pemphigoid gestations contributed one case each (Table 1). Mean age for pemphigus vulgaris was 52.41 and for bullous pemphigoid 58.15. Female outnumbered males in pemphigus vulgaris while a male dominance was noted in bullous pemphigoid. Male female ratio was 3:5 in pemphigus and 3:2 in bullous pemphigoid. In Tzanck smear of pemphigus vulgaris patients acantholytic cells were present in 30 out of 32 patients. Neutrophils were the predominant infiltrate found in 96.87% cases. Eosinophils were found in 34.37% cases and lymphocytes were the least. Sertoli rosette cells, streptocytes not observed. (Table 2). Histopathology of pemphigus vulgaris patients showed suprabasal blister in 100%, acantholytic cells in 96.87% and tomb stone appearance in 31.25%. Pattern of DIF was intercellular fishnet pattern in all the cases. IgG was present in 100% and C3 in 87.5% cases. IgA and IgM were also present in one case. Tzanck smear correlated with the definitive diagnosis of pemphigus vulgaris in 93.75%, while histopathology and DIF correlated in 100%. All cases of pemphigus vegetans gave acantholytic cells in Tzanck smear. Suprabasal blister and acantholytic cells were noted in both the cases of pemphigus vegetans. Intraepidermal eosinophilic microabscess was present in only one case. Direct immunofluorescence of pemphigus vegetans showed intercellular deposits of IgG and C3 in both cases. Pemphigus vegetans had 100% correlation with Tzanck smear, histopathology and DIF. All the 6 cases of pemphigus foliaceus gave acantholytic cells & neutrophils in Tzanck smear. Subcorneal blister and acantholytic cells were present in all the cases of pemphigus foliaceus in biopsy. Dyskeratosis was noted only in one case. Intercellular fishnet pattern of immunofluorescence was observed in all the cases. Pemphigus foliaceus also had 100% correlation between Tzanck, histopathology and DIF. In bullous pemphigoid eosinophils were found in 70% cases, neutrophils in 95% in Tzanck smear. Lymphocytes were the least common cell type. 20% of bullous pemphigoid patients had both sub epidermal and supra basal blister with features of re epithelization in biopsy. Eosinophils were present in the blister cavity in 90% cases. 19 out of 20 patients had linear basement membrane zone deposits in immunofluorescence (Table 3). Tzanck smear with eosinophils correlated with the clinical diagnosis of bullous pemphigoid in 70% cases while histopathology correlated in 100%, but DIF correlated in only 95% cases. Tzanck smear in LPP showed neutrophils in all cases. Out of the two cases of lichen planus pemphigoides one case showed typical histology for lichen planus along with a subepidermal blister and spongiosis which is diagnostic of lichen planus pemphigoides. In other case the typical features of lichen planus were lacking with only a wedge shaped hyper

granulosis and peri appendageal lymphocytic infiltrate. In this case, the plane of the blister was intraepidermal. Direct immunofluorescence staining of colloid bodies with IgM and C3 confirmed the diagnosis in both the cases of lichen planus pemphigoides. 100% sensitivity for Tzanck smear was found in pemphigus vegetans, pemphigus foliaceus, pemphigoid gestationis, dermatitis herpetiformis, linear IgA disease, chronic bullous disease of childhood. Sensitivity was 93.75% in pemphigus vulgaris and 70% in bullous pemphigoid. 65 cases of viral vesicular skin lesions were studied. The characteristic findings of multinucleated giant cells and acantholytic cells were found in the various herpetic infections. Among the Tzanck smears taken from vesicles, 92% gave a positive result. 2 out of 4 cases of hand foot mouth disease showed cells with syncytial nuclei in Tzanck smear.

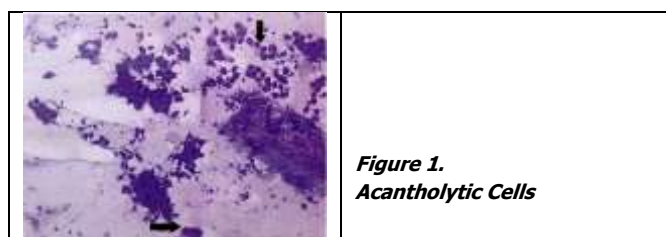


Figure 1.
Acantholytic Cells

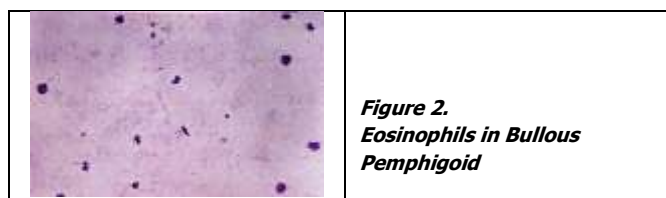


Figure 2.
Eosinophils in Bullous Pemphigoid

Disease	No. of Patients	%
Pemphigus vulgaris	32	48.48
Pemphigus vegetans	2	3.03
Pemphigus foliaceus	6	9.1
Bullous pemphigoid	20	30.3
Dermatitis herpetiformis	1	1.5
Lichen planus pemphigoides	2	3.03
Pemphigoid gestationis	1	1.5
Linear IgA dermatosis	1	1.5
Chronic bullous disease of childhood	1	1.5

Table 1. Percentage Distribution of Chronic Immunobullous Disease

Cell type	No. of Patients	%
Acantholytic cells & neutrophils	14	43.75
Acantholytic cells, neutrophils & eosinophils	11	34.37
Acantholytic cells, neutrophils & lymphocytes	5	15.62
Neutrophils alone	1	3.12
No cells	1	3.12

Table 2. Tzanck Smear Findings in Pemphigus Vulgaris

DIF	No. of Patients	%
IgG + C3	9	45
IgG + C3 + Fibrinogen	4	20
C3 Alone	3	15
IgG + IgA + C3	2	10
IgA + C3	1	5
No deposits	1	5

Table 3. Direct Immunofluorescence in Bullous Pemphigoid

Tzanck smear has a sensitivity of 70.77% in diagnosing herpetic infections and 50% sensitivity for hand foot mouth disease. 50 cases of eczemas which presented with vesicular lesions or erosions were taken for the study. 75% patient with allergic contact dermatitis and 72.72% patient with irritant contact dermatitis showed more than 10 tadpole cells

in a Tzanck smear. None of the other cases of eczemas gave tadpole cells. Lymphocytic predominance was found in 75% patients with allergic contact dermatitis while neutrophil predominance was noted in 72.72% of irritant contact dermatitis. Tzanck smear taken from the vesicles gave the maximum positivity followed by pustules and least from erosions. In allergic and irritant contact dermatitis, Tzanck smear has a sensitivity of 73.91%. Taking all the eczemas, sensitivity of Tzanck smear is only 34%.

DISCUSSION

During the 18 months duration of the study, there were 66 cases of chronic immunobullous diseases, 65 cases of viral vesicular skin lesions and 50 cases of eczemas. Among pemphigus group of disease, pemphigus vulgaris constituted 80%, pemphigus foliaceus 15% and pemphigus vegetans comprised 5% cases in this study. According to Arya SR et al, pemphigus vulgaris was 61.43%, followed by pemphigus foliaceus in 35.71% and pemphigus vegetans in 2.86%.³ Arya SR et al study showed a slight male predominance while our study showed a female predominance in pemphigus group, attributable to high female sex ratio in Kerala. Mean age of bullous pemphigoid in this study (58.15 yrs) was higher compared to that of pemphigus vulgaris (52.41 yrs). Acantholytic cells were present in 93.75% cases of pemphigus vulgaris, 100% cases pemphigus vegetans and pemphigus foliaceus.

This study showed a Tzanck smear sensitivity of 95% in pemphigus as a whole. Positivity of acantholytic cells in Tzanck smear test in cases with pemphigus has been reported between 93.3% by Ruocco et al⁴ and 100% by Durdu M et al.⁵ Sensitivity of Tzanck smear in the study is comparable with these studies. The two cases of pemphigus vulgaris which yielded negative Tzanck smears; one was from a vesicle and the other from oral erosion. Negative Tzanck smear from a vesicle is a curious observation that needs explanation. It can be proposed that too early a vesicle may be only a spongiotic vesicle rather than an acantholytic vesicle because eosinophilic spongiosis is the earliest histopathologic finding in pemphigus. Tzanck smear in this case didn't give any inflammatory cells as well. The evaluation of patients with only oral lesions is difficult, because intact blisters are rarely encountered due to the trauma mastication, and constant flow of saliva can wash away the acantholytic cells. Hence the negativity of the Tzanck smear from the oral lesion can be justified.

The literature states that in pemphigus vegetans, numerous eosinophils are present within the epidermis and dermis, producing both eosinophilic spongiosis and eosinophilic pustules⁶. Out of the two cases of pemphigus vegetans in this study, Tzanck smear of only one case showed eosinophils along with acantholytic cells and the second case showed acantholytic cells with neutrophils although histopathological study of both cases yielded eosinophilic microabscesses. In single case report of pemphigus vegetans by Jain et al, Tzanck smear showed

eosinophils and no acantholytic cells⁷. All the cases pemphigus foliaceus showed oval acantholytic cells with granular cytoplasm.

In this study there were no cases of pemphigus which showed streptocytes or Sertoli rosette in Tzanck smear. In the study by Durdu M et al, streptocytes were noted in 4.7% (n=1) cases of pemphigus and Sertoli rosette in 19% (n=4) cases indicating that these findings have a very low sensitivity in pemphigus.⁵ Along with acantholytic cells, inflammatory cells were also present in the Tzanck smear. In this study, the majority of inflammatory infiltrate constituted neutrophils (100%) followed by eosinophils (34.37%). Lymphocytes were the least common infiltrate. In the study by Leena et al,⁸ all the cases showed the presence acantholytic cells and mixed inflammatory cells which were composed of eosinophils and lymphocytes.

The histopathologic features of pemphigus vulgaris in this study correlates with those of the Arya S R et al study.³ The most consistent features were suprabasal blister information, acantholytic cells in the blister and dermal inflammatory infiltrate. The tomb stone appearance and acantholysis extending to the follicular sheath are features specific a pemphigus vulgaris which is present in a smaller number of cases (31.25% and 18.75% respectively). 6 cases showed acanthosis and 2 cases had villi formation; both these findings have a very low sensitivity and specificity. 40.62% had inflammatory infiltrate in the blister cavity compared to 53.5% in Arya et al study.³ The predominant inflammatory infiltrate was neutrophils followed by eosinophils in both the studies. In this study 100% of the cases had clinicopathologic correlation on account of the site of blister while acantholytic cells in the blister cavity had a sensitivity of 96.87%.

The study had 100% DIF positivity in pemphigus vulgaris while the earlier studies have shown a lesser sensitivity for DIF.⁹ The authors have attributed major part of this negativity to various reasons like absence of epidermis in the tissue specimen and technical errors; otherwise DIF is a very sensitive study. A mixed deposit of IgG and C3 in an intercellular fish net pattern is the most common (84.37%) pattern in our study while Buch et al got IgG alone (75.86%) as the common deposit. Both the cases of pemphigus vegetans showed hyperkeratosis, papillomatosis, acanthosis, suprabasal blister, a few acantholytic cells in the blister cavity and intra epidermal eosinophilic microabscess formation. One case showed villi formation. Arya S R et al³ and Leena et al⁸ study has also shown similar findings. Among all the cases of pemphigus, intra epidermal microabscess formation was found only in pemphigus vegetans. Hence this feature is 100% sensitive and specific for pemphigus vegetans.

Acanthosis was noted not only in pemphigus vegetans but also in pemphigus vulgaris. Although a sensitive finding, acanthosis is not specific for vegetans. A histopathologic differentiation between Hallopeau's and Neumann type pemphigus vegetans cannot be made. DIF has 100% sensitivity of pemphigus vegetans in this study. Both the cases of pemphigus vegetans showed intercellular deposition of IgG and C3 while Buch et al¹⁰ only IgG was present. Subcorneal blister and acantholysis were present in 100%

cases of pemphigus foliaceus while dyskeratosis was present only in 1 case in this study which similar to the other studies. Therefore, dyskeratosis; although a specific feature for pemphigus foliaceus has a very low sensitivity of 16.67% in this study. 66.67% cases had dermal infiltrate. There was a single case with focal parakeratosis and atrophy of rete ridges. All the 6 cases were DIF positive making it 100% sensitive. 50% showed only IgG and the remaining 50% showed both IgG and C3 in a fish net pattern in the upper epidermis. While in Buch et al study all the cases yielded only IgG.

In bullous pemphigoid 95% cases showed neutrophils in Tzanck smear and 70% of cases also gave eosinophils. In the study by Durdu Met al⁵ 77.78% cases showed eosinophils which is agreement with our study. Hence the finding of eosinophils in Tzanck smear is only 70% sensitive in view of this study. According to Durdu M et al it is a nonspecific finding as well. The neutrophilic predominance in this study may be attributed to the age of lesions. All the 20 cases of bullous pemphigoid had sub epidermal blister and 6 cases (30%) had eosinophilic spongiosis. Comparing this with Nishioka et al¹¹ study, 100% cases in this study also showed subepidermal blister and 24% had eosinophilic spongiosis which is in close agreement with our study. There were four cases which had suprabasal blister with features of re epithelialization along with subepidermal blister. The subepidermal blister is a 100% sensitive finding in bullous pemphigoid; but not a specific finding since it is present in other subepidermal autoimmune blistering diseases as well. Eosinophilic spongiosis is neither a specific nor a sensitive finding. DIF is sensitive in 95% cases of bullous pemphigoid in this study, while it is 100% sensitive according to Metha V study¹² and in Buch et al study sensitivity is still lower (84%).

50% (n=1) of lichen planus pemphigoides had eosinophils with neutrophils and the reminder had lymphocytes with neutrophils. From the literature, cytology of lichen planus pemphigoides is similar to that of bullous pemphigoid.¹³ Here the sensitivity of Tzanck smear is only 50% according to this study. Out of the two cases of lichen planus pemphigoides in this study, one case showed typical histology for lichen planus along with a subepidermal blister and spongiosis which is diagnostic of lichen planus pemphigoides. In the other case typical features of lichen planus were lacking and the plane of the blister was intraepidermal due to re epithelialization from the margins of subepidermal blister. Here the sensitivity and specificity of histopathologic examination is only 50%. These finding are similar to those of Zarea et al¹⁴ and Washio K et al.¹⁵ DIF was confirmatory in both the cases of lichen planus pemphigoides with IgM and C3 staining of colloid bodies along with linear basement membrane zone deposition of IgG in one case; IgG and C3 in the other. Therefore, DIF is 100% sensitive in lichen planus pemphigoides. In this study Tzanck smear of pemphigoid gestationis showed neutrophils and eosinophils.

In a case report of postpartum pemphigoid gestationis, Thomas et al¹⁶ has demonstrated a similar finding. Therefore, presence of eosinophils in Tzanck smear in pregnant or immediate postpartum patient is highly suggestive of

pemphigoid gestationis. In pemphigoid gestationis histopathology showed subepidermal cleft, dermal infiltrate with neutrophils and eosinophils. DIF showed basement membrane zone deposition of linear IgG and C3 and DIF was 100% sensitive. In a study of 20 cases of pemphigoid gestationis by Mokni M, et al¹⁷, histopathologic examination was positive in 55% cases only while DIF was positive in 100% cases. 100% DIF sensitivity is described by Shornick J K et al¹⁸ and Castro LA et al¹⁹ which is similar to the findings of the study. The only case of dermatitis herpetiformis in this study showed neutrophils, eosinophils and lymphocytes in Tzanck smear, which is similar to Hertz study.²⁰ Histopathology and DIF showed typical features of DH. Arundathi S had shown similar results.²¹ A case of LAD showed neutrophils in Tzanck smear. Biopsy and DIF were 100% sensitive. A 3-year-old child with chronic bullous disease of childhood in this study had both neutrophils and eosinophils. The case reports of chronic bullous disease of childhood by Thappa et al²² had shown only neutrophils while report by Haneef et al²³ had not shown any abnormality in Tzanck smear.

Histopathology of chronic bullous disease of childhood was similar to that of Linear IgA disease with a subepidermal blister and neutrophilic dermal infiltrate which is not a specific finding. DIF should be done for a specific diagnosis so as to differentiate it from childhood bullous pemphigoid. DIF was 100% sensitive and specific with linear deposits of IgA along the basement membrane zone. Chorzelski TP et al,²⁴ Hertz et al and Thappa DM et al have similar findings in histopathology and DIF with 100% sensitivity for DIF in this disease. Haneef et al describes a case of chronic bullous disease of childhood with IgG predominance rather than IgA which could be called as a mixed immunobullous disease. This study didn't come across such a finding.

Tzanck Smear in Vesicular Viral Infections

Tzanck smears from 65 cases of viral vesicular skin lesions were studied. This study agrees with Solomon AR et al²⁵ and Durdu M et al in that early vesicles yield maximum Tzanck smear positivity. Our study had a sensitivity of 84% in varicella zoster infections, but a much lower sensitivity (69.44%) in herpes simplex infections. This must be due to the fact that majority of Tzanck smears in varicella zoster infections were taken from vesicles where most of the herpes simplex lesions were taken from erosion. Taking herpetic infections as a whole sensitivity of Tzanck smear in this study is 70.77%. Intranuclear infections (Cowdry A body) were observed in only 9 of 92 specimens (9.8%) of herpes zoster by Durdu M et al. in this study Cowdry A bodies were observed in two case only; hence not a sensitive marker. 2 out of 4 cases of hand foot mouth disease showed cells with syncytial nuclei in Tzanck smear. While Durdu M et al showed these cells with syncytial nuclei in 6 out of 7 cases. There are no other studies so far investigating the usefulness of Tzanck smear in hand foot mouth disease. The Tzanck smear properties in the 50 cases of eczemas which presented with vesicular lesions and erosions were studied. 75% patients with allergic contact dermatitis and 72.72%

patients with irritant contact dermatitis showed more than 10 tadpole cells in a Tzanck smear. None of the other cases of eczemas gave tadpole cells. Lymphocytic predominance was found in 75% patients with allergic contact dermatitis while neutrophil predominance was noted in 72.72% of irritant contact dermatitis. In the case of eczemas also vesicles gave maximum positivity (72.22%) followed by pustules (37.5%) and erosions (4%). Taking all the eczemas into account, sensitivity of Tzanck smear drops down to 34%. Hence Tzanck smear is a very useful test in eczemas when performed in those cases of allergic and irritant contact dermatitis when the patient presents with vesicles rather than crusted erosions. Our study is also in agreement with the two studies that lymphocytic predominance is noted in allergic contact dermatitis and neutrophilic predominance is noted in irritant contact dermatitis.^{5,26} Pavithran K²⁶ has also proposed that cytology would also be of help in differentiating the two types of contact dermatitis.

CONCLUSIONS

In chronic immunobullous diseases Tzanck smear helps the dermatologist to make a primary diagnosis with ease and rapidity without much discomfort to the patient. Sensitivity of Tzanck smear was 95% in pemphigus group of diseases and low in other diseases studied. Tzanck smear is a cost effective, rapid and patient friendly diagnostic tool which should be a part of daily dermatology practice.

REFERENCES

- [1] Gupta LK, Singhi MK. Tzanck smear: a useful diagnostic tool. *Indian J Dermatol Venereol Leprol* 2005;71(4):295-299.
- [2] Barr RJ. Cutaneous cytology. *J Am Acad Dermatol* 1984;10(2 Pt 1):163-180.
- [3] Arya SR, Valand AG, Krishna K. A clinic-pathological study of 70 cases of pemphigus. *Indian J Dermatol Venereol Leprol* 1999;65(4):168-171.
- [4] Ruocco V, Coscia-Porrazzi L, Pisani M. Reliability of cytodiagnosis in oral pemphigus. A study of 30 cases. *J Dermatol* 1984;11(6):535-540.
- [5] Durdu M, Baba M, Seckin D. The value of Tzanck smear test in diagnosis of erosive, vesicular, bullous and pustular skin lesions. *J Am Acad Dermatol* 2008;59(6):958-964.
- [6] Wu H, Bennet H, Harris TJ. Noninfectious vesiculobullous and vesiculopustular diseases. In: Elder D, Elenitsas R, Johnson B, et al, eds. *Lever's histopathology of skin*. 10th edn. Philadelphia: Lipincott- Raven 2009:244-272.
- [7] Jain VK, Jindal N, Imchen S. Localized pemphigus vegetans without mucosal involvement. *Indian J Dermatol Venereol Leprol* 2014;59(2):210.

- [8] Leena VB, Manjunath GV, Sunila R, et al. A clinic-pathological study of 22 cases of pemphigus. *J Clin Diagn Res* 2010;4:2446-2451.
- [9] Inchara YK, Rajalakshmi T. Direct immunofluorescence in cutaneous vesicobullous lesions. *Indian J Pathol Microbiol* 2007;50(4):730-732.
- [10] Buch AC, Kumar H, Panicker N, et al. A cross sectional study of direct immunofluorescence in diagnosis of immunobullous dermatoses. *Indian J Dermatol Venereol Leprol* 2014;59(4):364-368.
- [11] Nishioka K, Hashimoto K, Katayama I, et al. Eosinophilic spongiosis in bullous pemphigoid. *Arch Dermatol* 1984;120(9):1166-1168.
- [12] Mehta V, Balachandran C. Localized flexural bullous pemphigoid. *Indian J Dermatol Venereol Leprol* 2008;53(3):157-158.
- [13] Valia AR, Ramesh C, Jerjani HR, et al. Blistering disorders. In: Valia RG, Valia AR, Sidappa K, eds. *IADVL textbook of dermatology*. 3rd edn. Vol. 2. Bhalani Publishing House 2008:1087-1117.
- [14] Zarea I, Mahfoudh A, Sellami MK, et al. Lichen planus pemphigoides: four new cases and a review of the literature. *Int J Dermatol* 2013;52(4):406-412.
- [15] Washio K, Nakamura A, Fukuda S, et al. A case of lichen planus pemphigoides successfully treated with a combination of cyclosporine and prednisolone. *Case Rep Dermatol* 2013;5(1):84-87.
- [16] Thomas S, Rajan U, George S, et al. Postpartum pemphigoid gestationis *Indian J Dermatol Venereol Leprol* 2012;57(2):146-148.
- [17] Mokni M, Fourati M, Karoui I, E et al. Pemphigoid gestationis: a study of 20 cases. *Ann Dermatol Venereol* 2004;131(11):953-956.
- [18] Shornick JK, Bangert JL, Freeman RG, et al. Herpes gestationis: clinical and histologic features of twenty eight cases. *J Am Acad Dermatol* 1983;8(2):214-224.
- [19] Castro LA, Lundell RB, Krause PK, et al. Clinical experience in pemphigoid gestationis: report of 10 cases. *J Am Acad Dermatol* 2006;55(5):823-828.
- [20] Hertz KC, Katz SI. Juvenile dermatitis herpetiformis: an immunologically proven case. *Pediatrics* 1977;59(6):945-948.
- [21] Arundhati S, Ragunatha S, Mahadeva KC. A cross-sectional study of clinical, histopathological and direct immunofluorescence spectrum of vesicobullous disorders. *J Clin Diagn Res* 2013;7(12):2788-2792.
- [22] Thappa DM, Jeevankumar G. Chronic bullous dermatosis of childhood. *Postgrad Med J* 2003;79(934):437.
- [23] Haneef NS, Ramachandra S, Metta AK, et al. Chronic bullous disease of childhood with IgG predominance: what is the Locus Standi? *Indian J Dermatol Venereol Leprol* 2012;57(4):285-287.
- [24] Chorzelski TP, Jablonska S, Beutner EE, et al. Juvenile dermatitis herpetiformis versus "benign chronic bullous dermatosis of childhood." Are these immunologic diseases? *J Invest Dermatol* 1975;65(5):447-450.
- [25] Solomon AR, Rasmussen JE, Varani J, et al. The Tzanck smear in diagnosis of cutaneous herpes simplex. *JAMA* 1984;251(5):633-635.
- [26] Pavithran K. Cytodiagnosis in contact dermatitis. *Indian J Dermatol Venereol Leprol* 1998;49(3):99-101.