

A STUDY ON AETIOLOGICAL CAUSES AND CLINICAL MANIFESTATIONS OF PORTAL VEIN THROMBOSIS

Radhakrishnan Natarajan¹, Premkumar Karunakaran², Venkateshwaran Arcot Rajeshwaran³, Kanisheikh Mohammed⁴, Ratnakar Kin⁵

¹Junior Resident, Department of Medical Gastroenterology, Institute of Medical Gastroenterology, Madras Medical College, Chennai.

²Professor, Department of Medical Gastroenterology, Institute of Medical Gastroenterology, Madras Medical College, Chennai.

³Professor and HOD, Department of Medical Gastroenterology, Institute of Medical Gastroenterology, Madras Medical College, Chennai.

⁴Associate Professor, Department of Medical Gastroenterology, Institute of Medical Gastroenterology, Madras Medical College, Chennai.

⁵Associate Professor, Department of Medical Gastroenterology, Institute of Medical Gastroenterology, Madras Medical College, Chennai.

ABSTRACT

BACKGROUND

Portal Vein Thrombosis (PVT) has become an increasingly recognisable disorder during evaluation of cases of abdominal pain with usage of widespread imaging techniques. VT can result due to various clinical conditions like chronic liver disease, infections, malignancies and hypercoagulable states.

The aim of the study is to observe the clinical presentation and to do the aetiological workup of cases of PVT in a tertiary care centre.

MATERIALS AND METHODS

The study is a cross-sectional observational study done on patients having PVT who presented to Institute of Medical Gastroenterology, MMC and RGGGH, during the period of January 2016-July 2017 were taken up for the study. The clinical presentation of the above patients was observed and their aetiological workup were done.

RESULTS

Totally, 45 cases were taken into study. 27 were males and 18 were females. Clinical presentation- The main symptoms were abdominal distension (18 patients, 51%), abdominal pain (10 patients, 27%), pain associated with diarrhoea and vomiting (5 patients, 14%), pain with nausea and anorexia (3 patients, 8%). Aetiological workup showed chronic liver disease (24 patients, 54%), prothrombotic states (9 patients, 20%), local factors, prothrombotic risks and idiopathic causes (12 patients, 26%). Detection of PVT were done mostly by portal vein Doppler (32 patients, 72%) and computed tomography (13 patients, 27%).

CONCLUSION

Higher incidence of PVT were seen among patients with chronic liver disease. Prothrombotic states like myeloproliferative disorders and coagulation defects were the next common causes detected. PVT presenting as plain abdominal pain, pain associated with nausea, vomiting and diarrhoea were seen in patients as well thereby suggesting that PVT is an important differential diagnosis in patients presenting as abdominal pain with a negative workup for common causes. With the help of widespread and improved imaging techniques, earlier diagnosis of PVT can be achieved and early intervention can greatly reduce the morbidity of patients.

KEYWORDS

Hypercoagulable State, Myeloproliferative Disorder, Portal Vein Thrombosis.

HOW TO CITE THIS ARTICLE: Natarajan R, Karunakaran P, Rajeshwaran VA, et al. A study on aetiological causes and clinical manifestations of portal vein thrombosis. J. Evid. Based Med. Healthc. 2017; 4(93), 5666-5669. DOI: 10.18410/jebmh/2017/1137

Financial or Other, Competing Interest: None.
Submission 17-11-2017, Peer Review 26-11-2017,
Acceptance 05-12-2017, Published 06-12-2017.

Corresponding Author:

Dr. Premkumar Karunakaran,
Kandan Kudil, 57, Lakshmi Vadana Nagar,
ECR Kottivakkam, Chennai-600041.

E-mail: drpremgastro@gmail.com

DOI: 10.18410/jebmh/2017/1137



BACKGROUND

Portal Vein Thrombosis (PVT) is defined as a state of obstruction of blood flow in portal vein, which can be either partial or complete and associated with thrombus inside the vascular lumen.¹ First case of portal vein thrombosis was reported in a patient with ascites, splenomegaly and varices by Balfour and Steward in 1868.² PVT in general is a rare clinical state with a low incidence of 0.7% and with a prevalence of 3.7% among general population.³ Higher incidence and prevalence rates are seen among cirrhotic

patients with about 10% of PVT cases.⁴ Acute Portal Vein Thrombosis (PVT) is diagnosed by the presence of thrombus in PV. Chronic PVT is made out by the presence of collaterals resulting due to longstanding PVT.^{5,6} Patients with acute PVT present with nonspecific symptom making the diagnosis of PVT difficult. Diagnosis of PVT is done mostly using USG or CT imaging. Chronic liver disease-cirrhosis accounts for nearly 11.2%-25.2%⁸ of PVT patients. In patients with no chronic liver disease, hypercoagulable states and myeloproliferative disorders accounts for 40%-70%. Local factors like intra-abdominal surgeries, cancers and inflammatory conditions accounts for 10%-50% of PVT cases.^{8,9} Mortality due to PVT accounts for 2-3% in cases with no underlying liver disease or cancers.^{8,10} Previous few studies explains us about the clinical features and outcomes of PVT.^{5,6} To increase our knowledge and awareness about PVT, we hereby report our study on 45 cases of PVT who presented during January 2016-July 2017 in our centre, Institute of Medical Gastroenterology, Madras Medical College, Chennai, India.

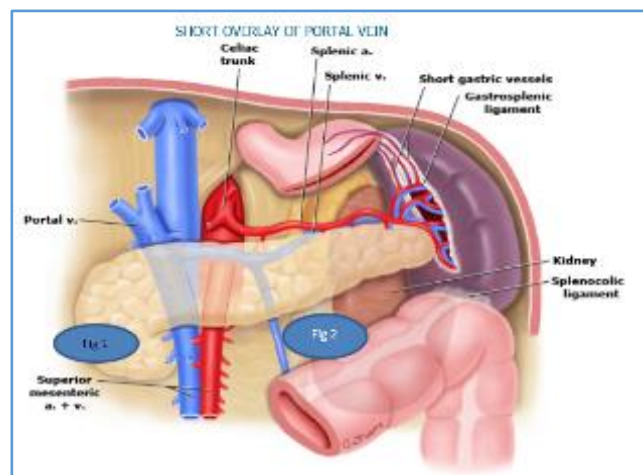
Aim and Objectives

1. To observe the clinical presentation of the portal vein thrombosis cases presented to the centre.
2. To do the aetiological workup of cases of PVT.

MATERIAL AND METHODS

Patients who presented to our centre with various symptomatology and diagnosed to have PVT by USG-portal vein Doppler and computed tomography were taken into study. A total of 45 patients with PVT were identified, their clinical profile and aetiological workup done. The clinical presentation includes patient's age, sex, thrombus staging acute or chronic. Acute cases identified as having thrombus in portal vein and chronic cases identified as having established collaterals, patients presenting symptoms. PVT aetiological workup and diagnostic procedures includes routine blood haemogram (leucocyte count, platelet count) blood chemistry like C-reactive protein, LDH, aspartate and alanine aminotransferase, alkaline phosphatase, serum amylase, procoagulant workup and imaging techniques.

Procoagulation screen includes the following tests-Protein C and protein S levels, antithrombin levels, factor V Leiden mutation analysis, antiphospholipid antibodies and homocysteine levels. Patients on OCPs were taken into account as well because of thrombotic property of OCPs. Bone marrow biopsy done for detecting myeloproliferative disorders.



RESULTS

The study was carried out on 45 patients of portal vein thrombosis. The following results were observed. Median age was found to be 45 (ranging from 18-72), 23 (52%) were males. 36 patients had acute portal vein thrombosis and 9 patients had chronic presentation. In patients with acute presentation, the main presenting symptom was abdominal distension in 18 (51%) abdominal pain in 10 (27%) pain with vomiting and diarrhoea in 5 (14%) pain with nausea and anorexia in 3 (8%). One patient presented with fever, 1 with hypotension and 2 with haematemesis. In patients with chronic presentation, 2 presented with mild abdominal pain, rest 7 were asymptomatic.

Diagnostic procedure observations- Blood examination results showed elevated leucocyte count in 20 (55%), increased C-reactive protein in 28 (77%), increased LDH levels in 14 (22 tested, 64%) of the 36 acute cases tested. D-dimer levels were detected in all 18 patients (100%) tested. Patients with normal serum amylase levels were ruled out of acute pancreatitis being a cause. Thrombocytosis were seen in patients with myeloproliferative disorder.

Imaging study results- Portal vein Doppler aided in detecting 32 (72%) cases of PVT. Computed tomography were used to diagnose in 12 (26%). PVT was accidentally discovered in 1 (2%) patient who underwent MRI abdomen.

Aetiological workup results- Our study on 45 patients with PVT showed the following aetiological workup observations. 24 (54%) patients had chronic liver disease, some with cirrhosis, 9 (20%) patients had prothrombotic conditions, out of which, 6 (13%) patients had myeloproliferative disorders diagnosed using bone marrow biopsy and 3 (7%) patients had procoagulant states, 2-Antiphospholipid Antibodies (APLA) and 1-protein C and protein S deficiency. Prothrombotic risks were seen in 4 (9%) patients out of which, 2 had increased homocysteine levels and 2 patients were taking OCPs. The cause for PVT could not be identified in 2 (4%) cases. Local factors were leading to PVT in 6 (13%) of cases due to factors like postsurgical complication (post-subtotal gastrectomy and splenectomy), septic cholangitis, chronic pancreatitis and Crohn's disease. In 2 (4%) cases, cause could not be identified.

Total Sample	N=45	100%
Median age (years)	45	
Males	23	50%
Thrombosis Staging		
Acute	14	32%
Chronic	9	20%
Chronic plus acute	22	48%
Presentation of acute thrombosis		
Abdominal distension	18	51%
Abdominal pain	10	27%
Vomiting and diarrhoea	5	14%
Nausea and anorexia	3	8%
Laboratory- Elevated Parameters		
WBC	20	55%
CRP	28	77%
22 patient tested LDH	14	64%
18 patients tested D-dimers	18	100%
Diagnostic method (primary diagnosis)		
Ultrasound- PV Doppler	32	72%
Computed tomography	13	26%
Magnetic resonance imaging	1	2%
Causal factors of PVT		
Chronic liver disease	24	54%
Prothrombotic disorder	9	20%
Myeloproliferative disease	6	13%
Coagulation disorder	3	7%
Local factor	6	13%
Prothrombin risk	4	9%
Idiopathic	2	4%
Main Characteristics of Study Population		

DISCUSSION

Our analysis on 45 patients with PVT thrombosis who presented in our centre showed that the median age of the PVT patients was 45 ranging from 18 to 72.

Clinical presentation of PVT in acute state were abdominal distension (ascites), abdominal pain, which could not be explained by clinical examination or laboratory findings. Some patients with abdominal pain had associated vomiting, diarrhoea and anorexia symptoms as well. The blood investigation results were nonspecific, still some patients had elevated leucocyte count, C-reactive protein and LDH levels. Patients who underwent D-dimer testing showed elevated levels thereby aiding in suspecting PVT in cases of abdominal pain and elevated D-dimer levels, though it is sensitive, but not specific.

Imaging studies mostly used to establish PVT was USG-portal vein Doppler and computed tomography. Patients diagnosed to have PVT by portal vein Doppler were confirmed again by CT scan. CT scan used to picture thrombus in portal and mesenteric circulation also provided a clear picture of abdominal organ examination and aided in detecting local precipitating factors for PVT; e.g., pancreatitis.

The aetiological workup of patients with PVT showed that more than one causative factor were seen in many cases, which showed that their occurrence were similar to some previous studies done to find the cause of PVT.^{8,9,11} The causes identified falls under three major categories, chronic liver disease, prothrombotic states and local factors

with a prevalence of 54%, 29% and 13%, respectively, in our study. In two cases, cause could not be identified. Prothrombotic states includes myeloproliferative disorder, procoagulant states and patients with prothrombotic risks with a contribution of 13%, 7% and 9%, respectively. Prothrombotic state included patients on oral contraceptive pills¹² and patients with elevated homocysteine levels.^{13,14} The local factors leading to PVT consists of inflammatory conditions like cholangitis,¹⁵ pancreatitis,⁵ inflammatory bowel disease,¹⁶ abdominal trauma,¹⁷ intra-abdominal surgeries, especially post splenectomy¹⁸ and carcinomas of stomach. Liver and pancreas encroaching the portal vein.

Inflammatory	Surgery related
Cirrhosis	Post liver transplant
Sepsis	Splenectomy
Pancreatitis	Colectomy
Diverticulitis	Portacaval shunting
Appendicitis	Umbilical vein catheterisation
Peptic ulcer disease	
Inflammatory bowel disease	
Abdominal trauma	
Local Factors	

Inherited disorders	Acquired disorders
Factor V Leiden mutation	Myeloproliferative disorders
Prothrombin gene mutation	Malignancies
Anti-thrombin III deficiency	Anti-phospholipid syndrome
Protein C deficiency	Anti-cardiolipin antibody
Protein S deficiency	Increased homocysteine levels
	Oral contraceptive pills
	Pregnancy/postpartum state
Hypercoagulable Aetiologies	

The goals of treatment are the same in acute and chronic PVT, which are¹ to correct the cause² to prevent the thrombus from extending and³ to maintain portal vein patency. Anticoagulants are the best options to recanalise portal vein. Till date, no clear literature or controlled trails are available for anticoagulants use in PVT.¹⁹

CONCLUSION

Higher incidence of PVT were seen among patients with chronic liver disease. Prothrombotic states like myeloproliferative disorders and coagulation defects were the next common causes detected. PVT presenting as plain abdominal pain, pain associated with nausea, vomiting and diarrhoea were seen in patients as well, thereby suggesting that PVT is an important differential diagnosis in patients presenting as abdominal pain with a negative workup for common causes. With the help of widespread and improved imaging techniques, earlier diagnosis of PVT can be achieved and early intervention can greatly reduce the morbidity of patients.

REFERENCES

- [1] Kocher G, Himmelmann A. Portal vein thrombosis (PVT): a study of 20 non-cirrhotic cases. Swiss Med Wkly 2005;135(25-26):372-376.

- [2] Wang JT, Zhao HY, Liu YL. Portal vein thrombosis. *Hepatobiliary Pancreat Dis Int* 2005;4(4):515-518.
- [3] Plessier A, Darwish-Murad S, Hernandez-Guerra M, et al. Acute portal vein thrombosis unrelated to cirrhosis: a prospective multicenter follow-up study. *Hepatology* 2010;51(1):210-218.
- [4] Ponziani FR, Zocco MA, Campanale C, et al. Portal vein thrombosis: insight into physiopathology, diagnosis, and treatment. *World J Gastroenterol* 2010;16(2):143-155.
- [5] Valla DC, Condat B. Portal vein thrombosis in adults: pathophysiology, pathogenesis and management. *J Hepatol* 2000;32(5):865-871.
- [6] Sheen CL, Lamparelli H, Milne A, et al. Clinical features, diagnosis and outcome of acute portal vein thrombosis. *Q J Med* 2000;93(8):531-534.
- [7] Amitrano L, Guardascione MA, Brancaccio V, et al. Risk factors and clinical presentation of portal vein thrombosis in patients with liver cirrhosis. *J Hepatol* 2004;40(5):736-741.
- [8] Janssen H, Wijnhoud A, Haagsma E, et al. Extrahepatic portal vein thrombosis: etiology and determinants of survival. *Gut* 2001;49(5):720-724.
- [9] Denninger MH, Chait Y, Casadevall N, et al. Cause of portal or hepatic venous thrombosis in adults: the role of multiple concurrent factors. *Hepatology* 2000;31(3):587-591.
- [10] Condat B, Pessione F, Hillaire S, et al. Current outcome of portal vein thrombosis in adults: risk and benefit of anticoagulant therapy. *Gastroenterology* 2001;120(2):490-497.
- [11] Bombeli T, Basic A, Fehr J. Prevalence of hereditary thrombophilia in patients with thrombosis in different venous systems. *Am J Hematol* 2002;70(2):126-132.
- [12] Belicova M, Lukac B, Dvorsky J, et al. Thromboembolic disease and present oral contraception. *Clin Appl Thromb Hemost* 2003;9(1):45-51.
- [13] den Heijer M, Rosendaal FR, Blom HJ, et al. Hyperhomocysteinemia and venous thrombosis: a meta-analysis. *Thromb Haemost* 1998;80(6):874-877.
- [14] Hainaut P, Jaumotte C, Verhelst D, et al. Hyperhomocysteinemia and venous thromboembolism: a risk factor more prevalent in the elderly and in idiopathic cases. *Thromb Res* 2002;106(2):121-125.
- [15] Plemmons RM, Dooley DP, Longfield RN. Septic thrombophlebitis of the portal vein (pylphlebitis): diagnosis and management in the modern era. *Clin Infect Dis* 1995;21(5):1114-1120.
- [16] Tsujikawa T, Ihara T, Sasaki M, et al. Effectiveness of combined anticoagulant therapy for extending portal vein thrombosis in Crohn's disease. *Dis Colon Rectum* 1996;39(7):823-825.
- [17] Duvoux C, Radier C, Gouault-Heilmann M, et al. A rare cause of portal vein thrombosis: closed abdominal trauma. *Gastroenterol Clin Biol* 1994;18(2):165-167.
- [18] Hassn AM, Al-Fallouji MA, Ouf TI, et al. Portal vein thrombosis following splenectomy. *Br J Surg* 2000;87(3):362-373.
- [19] Lee HK, Park SJ, Yi BH, et al. Portal vein thrombosis: CT features. *Abdom Imaging* 2008;33(1):72-79.