

# A STUDY OF COMPARATIVE ASSESSMENT OF THE THERAPEUTIC EFFICACY OF TOPICAL LULICONAZOLE VERSUS TOPICAL KETOCONAZOLE IN THE TREATMENT OF PITYRIASIS VERSICOLOR

Vedartham Kishore Kumar<sup>1</sup>

<sup>1</sup>Associate Professor, Department of Dermatology, Government Medical College and Government General Hospital, Anantapur, Andhra Pradesh.

## ABSTRACT

### BACKGROUND

Pityriasis versicolor is one of the most common and recurring superficial fungal infections of the skin occurring in the patients attending the Dermatology Outpatient Department. Malassezia species are the causative organisms for the Pityriasis versicolor. Many different modalities of treatment are available to treat Pityriasis versicolor.

The aim of the present study is to evaluate the drug, which is more therapeutically efficacious among topical luliconazole 1% cream versus topical ketoconazole 2% cream in the treatment of Pityriasis versicolor.

### MATERIALS AND METHODS

A total of 70 patients with skin lesions of Pityriasis versicolor attending the Dermatology Outpatient Department, Government General Hospital, Anantapur, Andhra Pradesh, were selected to this study. These patients were divided into two groups (A and B) randomly with 35 patients in each group. The group A patients were treated with topical luliconazole 1% cream twice daily and group B patients were treated with topical ketoconazole 2% cream twice daily for 28 days. Clinical assessment and mycological (by KOH mount) assessment was done to all the patients in both the groups at the beginning and at the two follow up visits, first follow up on the 14<sup>th</sup> day and second follow up on the 28<sup>th</sup> day of this study to evaluate the comparative therapeutic efficacy of both these drugs.

### RESULTS

At the first follow up (on 14<sup>th</sup> day), clinical and mycological (by KOH mount) assessment in both the groups showed KOH mount negativity of 81.82% and 69.70% of patients in the luliconazole-treated group and ketoconazole-treated group, respectively. At the second follow up (on 28<sup>th</sup> day), 96.77% and 72.41% of patients showed KOH mount negativity in the luliconazole-treated group and ketoconazole-treated group, respectively. No statistically significant difference of change in therapeutic efficacy was observed in between luliconazole and ketoconazole-treated groups at the first follow up ( $p > 0.05$ ), but statistically significant difference of change in the therapeutic efficacy of luliconazole-treated group was observed against ketoconazole-treated group at the second follow up ( $p < 0.05$ ).

### CONCLUSION

Both topical luliconazole 1% cream and topical ketoconazole 2% cream are having nearly equal therapeutic efficacy in the treatment of Pityriasis versicolor when treated for 2 weeks, but topical luliconazole 1% cream is more therapeutically efficacious over topical ketoconazole 2% cream when treated for 4 weeks in the treatment of Pityriasis versicolor.

### KEYWORDS

Pityriasis Versicolor, Luliconazole, Ketoconazole.

**HOW TO CITE THIS ARTICLE:** Kishore Kumar V. A study of comparative assessment of the therapeutic efficacy of topical luliconazole versus topical ketoconazole in the treatment of pityriasis versicolor. J. Evid. Based Med. Healthc. 2018; 5(1), 53-56. DOI: 10.18410/jebmh/2018/11

### BACKGROUND

Pityriasis versicolor also called as Tinea versicolor is one of the common chronic recurring superficial fungal infections of the skin caused by the dimorphic and lipophilic fungi

*Financial or Other, Competing Interest: None.*  
*Submission 17-12-2017, Peer Review 24-12-2017,*  
*Acceptance 31-12-2017, Published 01-01-2018.*

*Corresponding Author:*

Dr. Vedartham Kishore Kumar,  
House No. 6-3-159, Flat No. 203,  
Fantasy Enclave, Ram Nagar,  
Anantapur-515004, Andhra Pradesh, India.  
E-mail: drvkishorekumar@yahoo.co.in  
DOI: 10.18410/jebmh/2018/11



belonging to the genus Malassezia.<sup>1,2</sup> Pityriasis versicolor is one of the most common pigmentary disorders of the skin occurring worldwide.<sup>3</sup> It usually occurs in adolescents and young adults, but also seen in other age groups of patients. Many different modalities of treatment, both systemic and topical antifungal drugs are available to treat Pityriasis versicolor. The aim of the present study is to evaluate the drug, which is more therapeutically efficacious among the topical luliconazole 1% cream versus topical ketoconazole 2% cream in the treatment of Pityriasis versicolor.

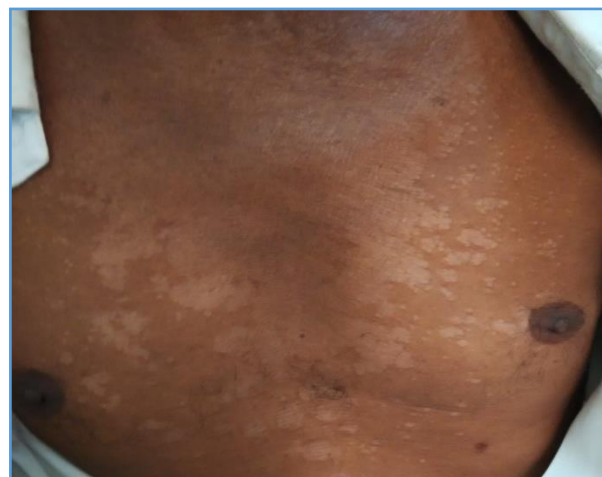Luliconazole is a newer, optically active and novel imidazole group of antifungal drug.<sup>4</sup> The unique chemical structure of luliconazole was augmented by introduction of a ketene dithioacetate structure in the imidazole moiety.

Luliconazole has high potency inhibitory action against filamentous fungi like dermatophytes as well as *Malassezia* species.<sup>5</sup>

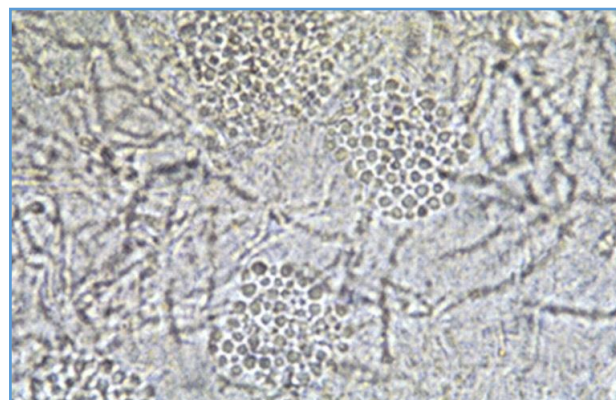
Ketoconazole is a water soluble synthetic imidazole group of antifungal drug having broad spectrum of antimycotic activity against dermatophytes and yeasts.<sup>6,7</sup>

## MATERIALS AND METHODS

A total of 70 patients with skin lesions of Pityriasis versicolor attending the Dermatology Outpatient Department, Government General Hospital, Anantapur, Andhra Pradesh, during the period from July 2016 to September 2016 were selected in this study. Confirmation of the diagnosis of Pityriasis versicolor was done by collecting the skin scrapings from the skin lesions of patients with Pityriasis versicolor and finding both the yeast form (large number of variable size of spores producing grape-like clusters of yeast) and mycelial form (short, thick hyphae) of the *Malassezia* fungi producing the characteristic Spaghetti and meat-balls appearance<sup>8</sup> in 10% KOH mount preparation, which was examined under the microscope. Patients with Pityriasis versicolor skin lesions who were already undergoing antifungal treatment either topically or systemically and pregnant women were excluded from this study. As this study is a prospective, open, randomised controlled study, after the informed consent, all the patients in this study were randomly allotted to two groups (A and B) with 35 patients in each group. The group A patients were treated with topical luliconazole 1% cream twice daily and group B patients were treated with topical ketoconazole 2% cream twice daily for 28 days. Clinical assessment and mycological (by doing the KOH mount) assessment was done to all the patients in both the groups at the beginning and at the two follow up visits of this study. The first follow up assessment was done on the 14<sup>th</sup> day and the second follow up assessment was done on the 28<sup>th</sup> day of this study to evaluate the comparative therapeutic efficacy of both these drugs. The clinical assessment of all the patients in both the groups was done by noting the characteristic clinical features of the Pityriasis versicolor skin lesions like the presence of hypo or hyperpigmented macules or patches covered by tiny dust like scales with irregular margins<sup>2</sup> and their distribution on the body over the chest, back, face, neck, upper extremities and abdomen (Figure 1) along with the clinical examination to determine the presence of any other dermatological diseases and systemic diseases in these patients. The mycological assessment of all the patients in both the groups was done in which skin scrapings were collected from the skin lesions to prepare for 10% KOH mount,<sup>8</sup> which was examined under the microscope to note the findings as KOH mount positive or negative for *Malassezia* fungi (Figure 2). At the end of this study, i.e. on the 28<sup>th</sup> day, comparative therapeutic efficacy evaluation of topical luliconazole 1% cream against topical ketoconazole 2% cream in the treatment of Pityriasis versicolor was done by noting the number of patients in both the groups of this study who attained the mycological cure, i.e. KOH mount negative for *Malassezia* fungi.



**Figure 1. Shows the Skin Lesions of Pityriasis Versicolor Over the Chest in a Patient of this Study**



**Figure 2. Microscopic Findings of 10% KOH Mount Preparation Collected from a Patient of this Study showing the Spaghetti and Meat Balls Appearance of Malassezia Fungus of Pityriasis Versicolor**

## RESULTS

Among the total 60 out of 70 patients selected to this study, 42 patients (70%) were males and 18 patients (30%) were females showing the male preponderance of the disease with the male-to-female ratio of 2.3:1. Majority of patients in this study were in the 21-40 years age group (80%). A total number of 10 patients did not turn to the follow up visits, i.e. 4 patients at the first follow up visit in which 2 patients from each group and 6 patients at the second follow up visit in which 4 patients from ketoconazole-treated group and 2 patients from luliconazole-treated group. So, these patients were excluded, while evaluating the final results of this study. At the beginning of this study, KOH mount was positive in 90% of patients, i.e. 3 patients (10%) were negative in the luliconazole-treated group and 85% of patients were positive, i.e. 5 patients (15%) were negative in the ketoconazole-treated group. At the first follow up (on 14<sup>th</sup> day) assessment of patients, KOH mount was negative in 27 patients (81.82%) of Luliconazole-treated group and 23 patients (69.70%) of Ketoconazole-treated group. At the second followup (on 28<sup>th</sup> day) assessment of patients, KOH mount was negative in 30 patients (96.77%) of luliconazole-treated group and 21 patients (72.41%) of Ketoconazole-treated group.

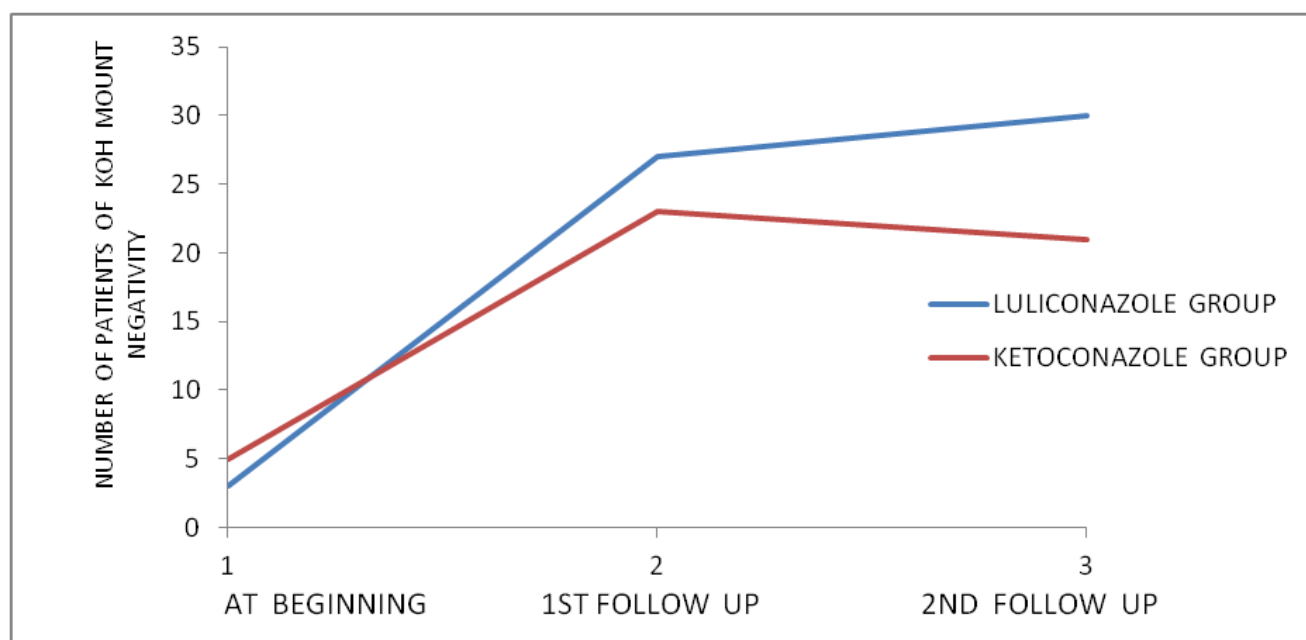
Mycological improvement of Pityriasis versicolor lesions was statistically significant in each patient of both the groups during the follow up assessments of this study ( $p < 0.0001$ ). On comparison of the therapeutic efficacy of topical luliconazole 1% cream versus topical ketoconazole 2% cream at the first follow up assessment (on 14<sup>th</sup> day) of this study did not show statistically significant difference

between them ( $p > 0.05$ ). But, at the second follow up assessment (on 28<sup>th</sup> day) of this study, statistically significant better improvement was noted in the topical luliconazole-treated group over the topical ketoconazole-treated group ( $p < 0.05$ ). P value was calculated by Fisher's exact test (Table 1 and Figure 3).

Time Period	Luliconazole Group (A) (Number of Patients with Negative KOH Mount)	Ketoconazole Group (B) (Number of Patients with Negative KOH Mount)	P value*
At the beginning	3	5	$>0.05$
1 <sup>st</sup> follow up (on 14 <sup>th</sup> day)	27	23	$>0.05$
2 <sup>nd</sup> follow up (on 28 <sup>th</sup> day)	30	21	$<0.05$

**Table 1. Number of Patients with Negative KOH Mount in Both the Groups at the beginning, on 14<sup>th</sup> Day and on 28<sup>th</sup> Day of this Study**

\*P value calculated by Fisher's exact test.



**Figure 3. Graphical Representation of KOH Mount Negativity in Both the Groups of This Study as it Increases Over Time**

## DISCUSSION

Various treatment modalities are now available to treat Pityriasis versicolor including both topical and systemic antifungal drugs like azoles, selenium sulphide, allylamines and sodium thiosulphate, etc. Most of these drugs showed similar clinically effective results in the treatment of Pityriasis versicolor, but randomised controlled studies are needed to compare their therapeutic effectiveness.<sup>9</sup> Hence, this study was undertaken to evaluate the comparative therapeutic efficacy of topical luliconazole 1% cream versus topical ketoconazole 2% cream in the treatment of Pityriasis versicolor.

Results of this study showed that topical luliconazole 1% cream was therapeutically more effective in comparison to the topical ketoconazole 2% cream in the treatment of Pityriasis versicolor when treated for a four-week period, but its therapeutic efficacy was nearly equal when treated for a two-week period. Luliconazole is a newer, optically active and a novel imidazole antifungal drug<sup>4</sup> having unique

chemical structure, which is augmented by the incorporation of ketene dithioacetate structure in its imidazole moiety. So, luliconazole 1% cream has high potency inhibitory action against many dermatophytic filamentous fungi including *Malassezia* species<sup>5</sup> in the stratum corneum of skin. Ketoconazole is a water soluble imidazole derivative antifungal drug. Ketoconazole is a synthetic antifungal drug having broad spectrum of antimycotic activity against dermatophytes and yeasts.<sup>6,7</sup> In other studies, ketoconazole showed a wide spectrum of antimycotic activity against dermatophytes, *Malassezia* species and *Candida* species in vitro.<sup>10</sup> Topical ketoconazole 2% cream was used in this study for the treatment of Pityriasis versicolor, which had previously given 80%-90% of cure rate in the treatment of Pityriasis versicolor in other studies.<sup>11-14</sup>

## CONCLUSION

According to the results obtained in this study, topical luliconazole 1% cream was therapeutically more effective in

comparison to the topical ketoconazole 2% cream in the treatment of pityriasis versicolor when treated for a four-week period, but the therapeutic efficacy of these two drugs are nearly equal when treated for a two-week period.

## REFERENCES

- [1] Dutta S, Bajaj AK, Basu S, et al. Pityriasis versicolor: socioeconomic and clinicomycologic study in India. *Int J Dermatol* 2002;41(11):823-824.
- [2] Hay RJ, Ashbee HR. Mycology. In: Burns T, Breathnach S, Cox N, et al, eds. *Rook's textbook of dermatology*. 8th edn. Blackwell Publishing Ltd 2010:36.1-36.93.
- [3] Szepletowski JC, Baran E, Ewa W. Tinea versicolor: a prospective study. *Korean J Med Mycol* 2000;5(3):108-112.
- [4] Niwano Y, Kuzuhara N, Kodama H, et al. In vitro and in vivo antidermatophyte activities of NND-502, a novel optically active imidazole antimycotic agent. *Antimicrob Agents Chemother* 1998;42(4):967-970.
- [5] Uchida K, Nishiyama Y, Tanaka T, et al. In vitro activity of novel imidazole antifungal agent NND-502 against *Malassezia* species. *Int J Antimicrob Agents* 2003;21(3):234-238.
- [6] Odds FC, Milne LJR, Gentles JC, et al. The activity in vitro and in vivo of a new imidazole antifungal, Ketoconazole. *J Antimicrobial Chemotherapy* 1980;6(1):97-104.
- [7] Thienpont D, Van Cutsem J, Van Gerven F, et al. Ketoconazole - a new broad spectrum orally active antimycotic. *Experientia* 1979;35(5):606-607.
- [8] Gupta AK, Batra R, Bluhm R, et al. Pityriasis versicolor. *Dermatol Clin* 2003;21(3):413-429.
- [9] Hu SW, Bigby M. Pityriasis versicolor: a systematic review of interventions. *Arch Dermatol* 2010;146(10):1132-1140.
- [10] Heeres J, Backx LJ, Mostmans JH, et al. Antimycotic imidazoles. Part 4. Synthesis and antifungal activity of ketoconazole, a new potent orally active broad-spectrum antifungal agent. *J Med Chem* 1979;22(8):1003-1005.
- [11] Savin RC, Horwitz SN. Double-blind comparison of 2% ketoconazole cream and placebo in the treatment of tinea versicolor. *J Am Acad Dermatol* 1986;15(3):500-503.
- [12] Balwada RP, Jain VK, Dayal S. A double-blind comparison of 2% ketoconazole and 1% clotrimazole in the treatment of pityriasis versicolor. *Indian J Dermatol Venereol Leprol* 1996;62(5):298-300.
- [13] Chopra V, Jain VK. Comparative study of topical terbinafine and topical ketoconazole in pityriasis versicolor. *Indian J Dermatol Venereol Leprol* 2000;66(6):299-300.
- [14] Nagpal VB, Jain VK, Aggarwal K. Comparative study of oral and topical ketoconazole therapy in pityriasis versicolor. *Indian J Dermatol Venereol Leprol* 2003;69(4):287-288.