CASE REPORT

A RARE EVENT OF ISOLATED TORSION OF FALLOPIAN TUBE CONTAINING ECTOPIC PREGNANCY - A CASE REPORT

Sreelatha S[1], Nataraj[2], Ashwini Rani[3], Sowmya[4]

HOW TO CITE THIS ARTICLE:
Sreelatha S, Nataraj, Ashwini Rani, Sowmya. "A Rare Event of Isolated Torsion of Fallopian Tube Containing Ectopic Pregnancy - A Case Report". Journal of Evidence Based Medical and Healthcare; Volume 1, Issue 6, August 2014; Page: 331-333.

ABSTRACT: The adnexal torsion is relatively common, accounting for 2.7% of all gynecological emergencies; isolated torsion of fallopian tube alone, is an infrequent, yet significant cause of lower abdominal pain in women, which generally presents in reproductive age group. Overall incidence of isolated tube torsion is 1 in 1.5 million women. It is generally unilateral, more on the right side. It should be considered as one of the differential diagnosis of abdominal pain in young women. Early diagnosis and treatment is required for the salvage of the twisted tube or part of it.[2] We, report a case of isolated tubal torsion containing ectopic pregnancy.

INTRODUCTION: While adnexal torsion is relatively common, isolated torsion of fallopian tube alone, first described in 1890 (Sutton. 1890), remains a rare occurrence with incidence of 1 in 1.5 million women (Hansen, 1970).[1] Much rarer is isolated torsion of fallopian tube containing ectopic pregnancy. Diagnosis is difficult, often established intraoperatively. We report a rare case of torsion of tubal ectopic pregnancy. To the best of our knowledge, this is the first reported case of this kind in an interval of 5 years, 2nd reported case so far.

CASE REPORT: A 24years old nulliparous lady presented with c/o on and off pain in lower abdomen for the last 12hours, associated with 2 episodes of vomiting. She gave H/o spotting per vagina for the past 15 days which started on the date of her LMP. There was no H/o amenorrhea. O/E she was pale with haemodynamic parameters stable. Tenderness noted in the right lower abdomen. P/S examination showed minimal bleeding from cervical os. Pelvic USG showed a retort shaped right adnexal mass of about 10x5cms size, containing a clear sac like structure of 2x 1cm. No evidence of fetal /yolk sac structures seen. Measurement of sac shows gestational age corresponding to 5 weeks urine pregnancy test was positive.

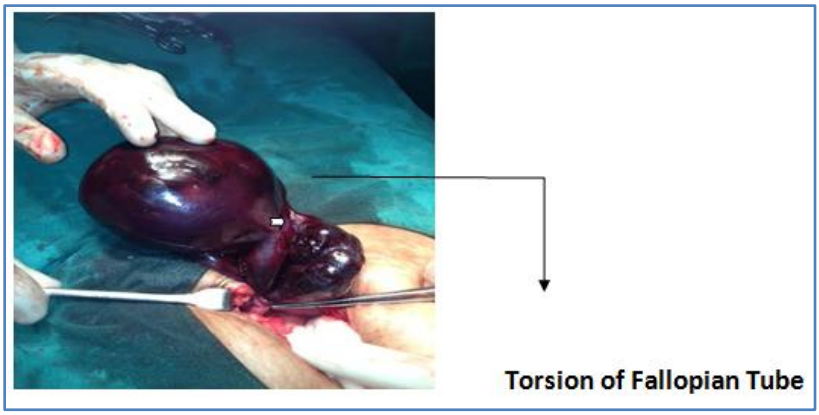

Patient was taken for emergency laporotomy with the diagnosis of ectopic pregnancy. Intraoperatively haemoperitoneum of 300 ml noted. Distal 2/3rd of right fallopian tube was distended with blood and clots, was about 15 x 5cms dimensions. On further examination, it was found that the distal 2/3rd of right fallopian tube had undergone torsion at isthmoampullary junction. Clots were seen to be coming from the fimbrial end. During detorsion (untwisting), it was noted that the tube had undergone torsion of about 2½ turns.

After detorsion, right partial salpingectomy was done. Left fallopian tube was examined, it was longer than normal and left ovary appeared normal. Post operative period was uneventful. Histopathological examination confirmed tubal ectopic Pregnancy. Patient was discharged on the 7th post operative day.

DISCUSSION: Isolated torsion of tubal ectopic is a rare event. Regad reported that only 12% of isolated tubal torsion are associated with pregnancy.[5] Though rare, it is a noteworthy cause of lower abdominal pain in women of reproductive age group.[1] It is a difficult condition to evaluate clinically and surgery is often necessary to establish the diagnosis.[5] The exact etiology of fallopian tube torsion is not known. The various theories proposed for torsion of fallopian tube includes.[6]

1. Anatomic abnormalities (long tube, long mesosalpinx, tubalabnormality, hematosalpinx, hydro salpinx, hydatid of morgagni).
2. Physiological abnormalities (abnormal peristalsis, hypermotility of tube, tubal spasm, intestinal peristalsis).
3. Hemodynamic abnormalities (venous congestion in mesosalpinx).
4. Sellheim theory- sudden body positional changes.
5. Trauma, previous surgery or disease (tubal ligation, PID).
6. Gravid uterus.

Once twist has occurred, it is easy to understand the sequential mechanism of torsion. Mechanical obstruction of adnexal veins and lymphatic's due to twist, cause pelvic congestion and edema causing enlargement of fimbrial end leading to subsequent partial or complete torsion of involved tube[7].Blood supply of fallopian tube and ovary comes from both ovarian and uterine vessels, hence isolated torsion of the tube does not cause vascular compromise of ovary.

Tubal torsion is more common in right sided fallopian tube, as in our case too, because of possible immobilization of left tube because of its proximity to sigmoid mesentery and slow venous flow in right side, causing congestion. Right lower quadrant pain is more often explored surgically, secondary to concern for appendicitis.[3,4]

Most common presenting symptom is lower abdominal pain, sudden onset, cramp like, intermittent pain, may be associated with nausea, vomiting, bowel and bladder complaints with scanty uterine bleeding. Pelvic examination often shows a tender adnexal mass. Due to above vague symptoms, this condition is frequently misdiagnosed as acute appendicitis, ovarian torsion, PID, diverticulitis, IBD, UTI, renal colic, degenerated leiomyoma etc. USG appearance includes elongated convoluted cystic mass, tapering as it nears uterine cornu.

Usually diagnosis of torsion of tubal ectopic is often established intraoperatively, as in our case. Complications are ruptured ectopic, hemoperitoneum, shock, fallopian tube necrosis and gangrene due to torsion, increased risk of infection, peritonitis etc.

Management includes early decisions regarding laporotomy and procedure but in our case detorsion and salpingectomy was done. Nowadays, laparoscopy is getting popularized.

CONCLUSION: Torsion of fallopian tube containing ectopic pregnancy is extremely rare, but tubal torsion needs to be considered as a differential diagnosis in young women. Early surgical intervention is recommended in order to salvage the affected tube and preserve fertility.

REFERENCES:

1. Hansen OH. Isolated torsion of the fallopian tube. Acta Obstet Gynecol Scand 1970; 49: 3-6.
2. Silja Renjit, Evelyn U Morale, Mariam Mathew. Isolated torsion of tubal ectopic pregnancy: A rare event. Oman Medical Journal 2008; 23: 4.
3. Phupong V, Intharasakda P. Twisted fallopian tube in pregnancy: A case report. BMC Pregnancy and childbirth 2001; 1: 5.
4. Yalcin O T, Hassa H, Zeytinoglu S, Isiksoy S. Isolated torsion of fallopian tube during pregnancy: Report of two cases. Eur J Obstet Gynecol Reprod Biol 1997; 74: 179-82.
5. Regad J. Etude anatomo-pathologique de la torsion des trompets uterines. Gynaecol Obstet 1933; 27: 519-3.
6. Youssef AF, Fayad MM, Shafeek MA. Torsion of fallopian tube-a clinic pathological study. Acta Obstet Gynecol Scand 1962; 41: 292-309.
7. Bernadus RE, Vander Slikke JW, Roex AJ, Dijkhuizen GH, Stolk JG. Torsion of the fallopian tube: some considerations on its aetiology. Obstet Gynecol 1984; 64: 675-678.

AUTHORS:

1. Sreelatha S.
2. Nataraj
3. Ashwini Rani
4. Sowmya

PARTICULARS OF CONTRIBUTORS:

1. Associate Professor, Department of Obstetrics & Gynaecology, ESIC Medical College & PGIMSR, Bangalore, Karnataka.
2. Senior Resident, Department of Obstetrics & Gynaecology, ESIC Medical College & PGIMSR, Bangalore, Karnataka.
3. Junior Resident, Department of Obstetrics & Gynaecology, ESIC Medical College & PGIMSR, Bangalore, Karnataka.
4. Junior Resident, Department of Obstetrics & Gynaecology, ESIC Medical College & PGIMSR, Bangalore, Karnataka.

NAME ADDRESS EMAIL ID OF THE CORRESPONDING AUTHOR:

Dr. Sreelatha S,
Associate Professor,
Department of Obstetrics & Gynaecology,
ESIC Medical College & PGIMSR,
Bangalore, Karnataka.
E-mail: drsreelatha2011@gmail.com

Date of Submission: 25/07/2014.
Date of Peer Review: 28/07/2014.
Date of Acceptance: 30/07/2014.
Date of Publishing: 01/08/2014.