

# CASE REPORT

---

## A RARE CASE REPORT ON NASAL CAVITY PARAGANGLIOMA

Ashfaque Ansari<sup>1</sup>, Suma Moni Mathew<sup>2</sup>

### HOW TO CITE THIS ARTICLE:

Ashfaque Ansari, Suma Moni Mathew. "A Rare Case Report on Nasal Cavity Paraganglioma". Journal of Evidence Based Medicine and Healthcare; Volume 1, Issue 7, September 2014; Page: 744-747.

**ABSTRACT:** Paragangliomas are rare neuroendocrine neoplasm of extra adrenal autonomic nervous system. These are usually benign, slow growing vascular tumors found in the abdomen, thorax, head and neck region. Head and neck paraganglioma is primarily located in the temporal bone and carotid body, paraganglioma of nose and paranasal sinuses are rare. We report a case of paraganglioma of the nose and Para nasal sinus in a 65 year old male patient, who was submitted to surgical excision, and histopathologically confirmed. He has been followed up since 2 years with no signs of recurrence.

**KEYWORDS:** nasal paraganglioma, nasal cavity.

**INTRODUCTION:** Paragangliomas are neoplasias arising from paraganglionic tissue of the autonomic nervous system. Paraganglions are of neuroectodermal origin Paraganglions are broadly distributed in the human body, found in the lungs, heart, mediastinum, gastrointestinal tract, retroperitoneal region and bladder. In the head and neck, they were found in trachea, tongue, larynx, hypophysis, pineal gland and orbit. Despite these findings, the most prevalent sites of paragangliomas are the carotid body, jugular body, along glossopharyngeal nerve and its tympanic branch, and the vagus nerve; especially next to nodal ganglion.<sup>2</sup> We report this case due to its rare incidence and rare site.

**CASE REPORT:** A 65-year-old man not a diabetic or hypertensive came to the OPD with complaints of left sided nasal obstruction for 4 years, also with history of chronic nasal secretion with periods of purulent rhinorrhea and associated headache, with a history of left nasal swelling and mass protruding since 2 months (Fig. 1). There was no history of bleeding, pain, visual disturbance, dental issues or trauma.

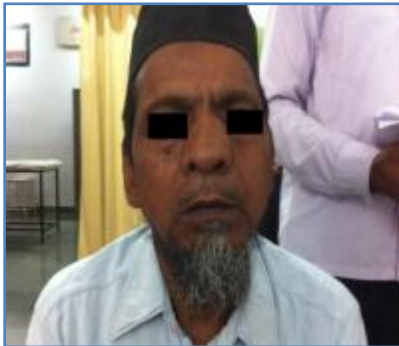On Otolaryngological examination, rhinoscopy showed a non-bleeding, firm, insensitive, polypoidal mass in the left nasal cavity (Fig. 2) with mucopurulent discharge, completely obstructing the ipsilateral choana. Ophthalmological and dental examinations revealed no abnormality. Haematological and serum biochemistry tests were normal. Computed tomography scan (CT) showed a well-defined soft tissue density in the left nasal cavity and left maxillary sinus with no bony erosion.

The patient was submitted to surgery, where total excision of lesion was carried out with lateral rhinotomy (Fig. 3) approach due difficulty transnasal endoscopically. No immediate or late postoperative complications were observed.

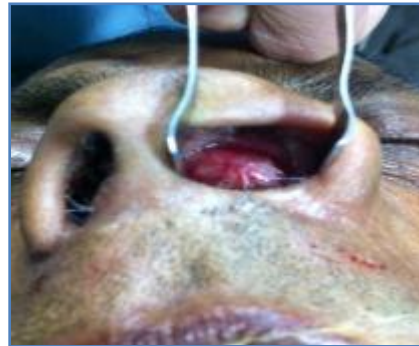Histo pathologically, the specimen reported large polygonal to oval cells arranged in chemodectomatous and nesting pattern, surrounded by a delicate fibrovascular stroma forming characteristic 'zellebellan' pattern (Fig. 4) and the margins are free. This confirmed the diagnosis of paraganglioma.

## CASE REPORT

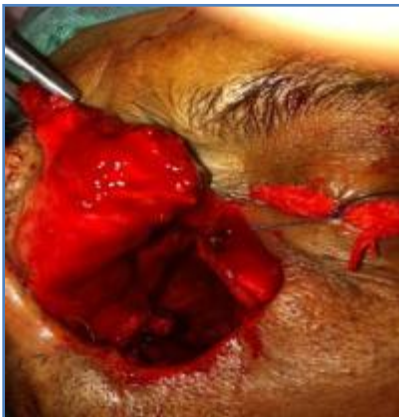After 1 months of surgery, the patient was asymptomatic and attending outpatient follow-up. So far, he has not showed evidences of relapses.



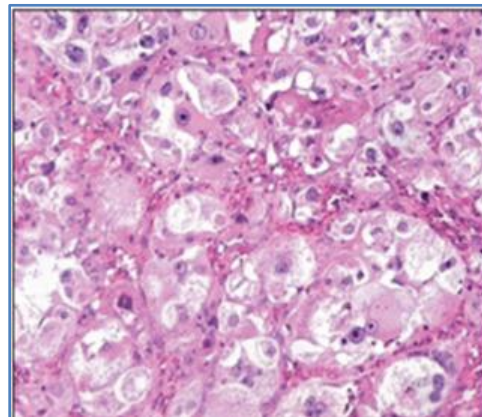
**Fig. 1: Left nasal swelling**



**Fig. 2: Left nasal mass**



**Fig. 3: Lateral rhinotomy approach**



**Fig. 4: HPE- epithelioid cells forms nests named 'zellballen' pattern**

**DISCUSSION:** Paragangliomas of the nose and of paranasal sinuses are very infrequent. An updated literature review demonstrated only 22 cases of paragangliomas on that anatomical site.<sup>3</sup>

Nasal paraganglioma is a slow-growing neoplasia, with a time interval between symptoms' onset and diagnosis of 2 or more years<sup>5</sup>. There is a well-defined and natural tendency towards multi centricity. Many synchronic tumors are incidentally revealed during arteriography. Usually, incidence of bi laterality and multi centricity of these tumors are of 3%, going up to 26% among patients with positive family history, which corroborates family predisposition<sup>6</sup>.

Clinical expression is recurrent episodes of mild to profuse epistaxis, rhinorrhea, nasal obstruction and facial edema, which may be followed by blurred vision.<sup>3,5</sup> In general, this neoplasia presents with a polypoid mass fixed to the lateral wall of the nasal fossa or on the upper region of the rhinopharyngeal roof.<sup>3</sup> In some cases, the paranglioma extends to the paranasal sinuses, with erosion of bone walls.<sup>5</sup>

# CASE REPORT

---

Macroscopically, paragangliomas are hard lesions of greyish or rosy colour and with encapsulated aspect<sup>3</sup>. Histologically, these neoplasias are peculiarly formed by epithelioid cells with round nuclei and eosinophilic cytoplasm, forming nests called zellballen which are separated by a rich capillary net of reticulin.<sup>1,5,7</sup> Electronic microscopy reveals the presence of cytoplasmatic neurosecreting granules in these cells of the cytoplasm.<sup>1</sup> Some benign neoplasias present cell pleomorphism and nuclear hyperchromic aspect, including mitotic figures.

Use of special histological staining is important to demonstrate neurosecreting cytoplasmatic granules.<sup>3</sup>

**MANAGEMENT:** Considering that paragangliomas present tendency towards progressive invasion of vital structures leading to morbidity, and also count on improved surgical techniques available, surgical excision with disease-free borders remains the treatment of choice for these neoplasias.<sup>3</sup> However, paragangliomas tend to locally relapse due to its nature and localization.<sup>1</sup> Radiotherapy for the treatment of paragangliomas is reported in the literature, but with variable results. Many authors reported an appropriate disease control with radiotherapy, although not reaching the cure. Thus, this therapeutic approach is reserved for patients without surgical indication or those with inadequate tumor excision. Chemotherapy was clearly ineffective in the treatment of paragangliomas. Embolization has been primarily used to restrict blood volume during surgery.<sup>1, 8</sup>

In our case, we could not demonstrate any evidence of metastasis to the regional nodes or distant organs. He has been followed up for 24 months and no additional symptoms or signs indicating recurrence have been identified.

**CONCLUSION:** The rare occurrence of paragangliomas of the nasal fossa has motivated our study. Once diagnosed, they should be treated surgically, considering its morbidity due to tendency towards progressive invasion of vital structures. However, even with adequate surgical approach, paragangliomas tend to present local relapse due to its nature and localization.

## REFERENCES:

1. Nguyen Q, Gibbs P, Rice D. Malignant nasal paraganglioma: a case report and review of the literature. *Otolaryngology – Head and Neck Surgery* 1995; 113(1): 157-61.
2. Talbot A. Paraganglioma of the maxillary sinus. *J Laryngol Otol* 1990; 104: 248-51.
3. Lack E, Cubilla A, Woodruff J, Farr H. Paragangliomas of the head and neck region: a clinical study of 69 patients. *Cancer* 1977; 39: 397-409.
4. Battista B, Vander W, Adair C, Mair E. Quiz case. *Archives of Otolaryngology – Head and Neck Surgery* 2001; 127(3): 329-30.
5. Himelfarb M, Ostrzega N, Samuel J, Shanon E. Paraganglioma of the nasal cavity. *Laryngoscope* 1983; 93: 350-2.
6. Mavez M, Carl Rusty. In: Bailey B, Healy G, Johnson J. *Head & Neck Surgery- Otolaryngology*, 3rd Edition. Philadelphia: Lippincott-Williams & Wilkins, 2001; p. 1562-73.
7. Kuhn J, Aronoff B. Nasal and nasopharyngeal paraganglioma. *J Surg Oncol* 1989; 40: 38-45.
8. Watson DJ. Nasal paraganglioma. *J Laryngol Otol* 1988; 102: 526-9.

# CASE REPORT

---

**AUTHORS:**

1. Ashfaque Ansari
2. Suma Moni Mathew

**PARTICULARS OF CONTRIBUTORS:**

1. Associate Professor, Department of ENT, MGM Medical College & Hospital, Aurangabad.
2. Senior Resident, Department of ENT, MGM Medical College & Hospital, Aurangabad.

**NAME ADDRESS EMAIL ID OF THE CORRESPONDING AUTHOR:**

Dr. Ashfaque Ansari,  
Associate Professor,  
Department of ENT and Head & Neck Surgery,  
MGM Medical College & Hospital,  
Aurangabad.  
E-mail: ashfaque.dr@gmail.com

Date of Submission: 26/08/2014.  
Date of Peer Review: 27/08/2014.  
Date of Acceptance: 05/09/2014.  
Date of Publishing: 11/09/2014.