

A RARE CASE OF EXTRAMEDULLARY PLASMACYTOMA MASQUERADING AS JUVENILE NASOPHARYNGEAL ANGIOFIBROMA

Harshita V. Sabhahit¹, Shruthi Gaddamane Shankar², Satish Kumar S³, G. Mohan⁴, Suha Venkatesh⁵

¹Assistant Professor, Department of ENT, Vydehi Institute of Medical Sciences & Research Centre, Bangalore.

²Assistant Professor, Department of ENT, Vydehi Institute of Medical Sciences & Research Centre, Bangalore.

³Professor & HOD, Department of ENT, Vydehi Institute of Medical Sciences & Research Centre, Bangalore.

⁴Professor, Department of ENT, Vydehi Institute of Medical Sciences & Research Centre, Bangalore.

⁵Postgraduate, Department of ENT, Vydehi Institute of Medical Sciences & Research Centre, Bangalore.

ABSTRACT

BACKGROUND

Plasmacytomas are rare plasma cell tumours occurring consequent to monoclonal proliferation of plasma cells. They are divided into Solitary bone plasmacytoma, Extramedullary plasmacytoma (EMP) and Multiple myeloma. EMPs are commonly housed in the head and neck region with a predilection to the mucosa associated lymphoid tissue in the aerodigestive tract. The nasal cavity, paranasal sinuses, and nasopharynx are the most common sites.

OBJECTIVE

We describe our experience with this tumour owing to its clinical rarity and a different way of presentation.

METHODS

After complete surgical excision of a nasal mass presenting in a young male with features masquerading that of Juvenile Nasopharyngeal Angiofibroma, a diagnosis of plasma cell tumour was made on histopathological analysis which was confirmed using immunohistochemistry. Serum electrophoresis, urine Bence Jones proteins, complete skeletal survey were done to rule out any progression into multiple myeloma. Radiation therapy was given with 45 Gy in 25 fractions at 1.8 Gy per day, 5 days a week.

RESULTS

Followup after 2 years showed no recurrence locally as well as in regional nodes.

CONCLUSION

Given to the rarity of the tumour, undefined manner of presentation and a predominant prevalence in the head and neck region, every otolaryngologist should keep EMP in mind while considering sinonasal masses. A multidisciplinary approach with a combination of surgery and radiotherapy is found to benefit the patient significantly. A long term watch out for progression to MM is mandatory to commence early treatment and thus prolonged disease-free survival from the same.

KEYWORDS

Plasmacytoma, Nasal Mass.

HOW TO CITE THIS ARTICLE: Sabhahit HV, Shankar SG, Kumar SS, et al. A rare case of Extramedullary Plasmacytoma masquerading as Juvenile Nasopharyngeal Angiofibroma. J. Evid. Based Med. Healthc. 2016; 3(71), 3898-3901.

DOI: 10.18410/jebmh/2016/833

INTRODUCTION: Extramedullary Plasmacytomas are rare plasma cell tumours constituting about 3-4% of all plasma cell neoplasms. Plasma cells are mature B lymphocytes which are responsible for the production of immunoglobulins which function as watchdogs to protect our bodies from attack by pathogens. However, when this goes haywire and starts producing immunoglobulins indiscriminately without any inciting pathogen, they lead to plasma cell dyscrasias, thus becoming a double edged sword.

Plasma cell disorders can be divided into multiple myelomas which form in the bone marrow in multiple areas of the body and more localised plasmacytomas, which can be further classified into solitary plasmacytomas which are isolated tumours placed in the marrow of the axial skeleton and extramedullary plasmacytomas (EMP) which are limited to soft tissues. Around 80% of EMPs are housed in the head and neck region predominantly involving the aerodigestive tract which includes paranasal sinuses, nasopharynx, nasal cavity, oropharynx, pharynx, and larynx. It may also involve other areas such as GIT, lymph nodes, skin, urinary tract rarely. The high rate of incidence in the upper aerodigestive tract could be attributed to the predisposition of these areas to chronic irritation by allergens and viruses, but the exact aetiology still remains unknown.

Financial or Other, Competing Interest: None.

Submission 08-08-2016, Peer Review 18-08-2016,

Acceptance 25-08-2016, Published 05-09-2016.

Corresponding Author:

Dr. Harshita V. Sabhahit,

#1052, 11th Main, Judicial Layout,

G.K.V.K. Post, Bangalore-560065.

E-mail: havisa276@gmail.com

DOI: 10.18410/jebmh/2016/833

The clinical features of this rare entity depends on the site of the tumour rather than the nature of the tumour consequent to local invasion and pressure effects. The presentation can thus be multifaceted and hence there is a need to consider this tumour as a possibility in patients presenting with symptoms related to nose and throat. This case report is being presented considering its early age and misleading nature of presentation, thus emphasising the importance of being aware of this clinical entity as a possibility whilst investigating sinonasal masses.

CASE REPORT: A young male of 21 years with no comorbidities presented to us with complaints of left-sided nasal obstruction for 6 months. Nasal obstruction was insidious in onset, which progressed to become continuous, with no specific aggravating and relieving factors. This was associated with mucoid discharge which was occasionally blood stained. On further questioning, he gave history of two episodes of spontaneous epistaxis which required nasal packing. He also gave history of recurrent sneezing bouts with itching of nose and eyes suggestive of allergic rhinitis. There was no history of hyposmia, anosmia, loss of sensation over face, headache, visual disturbances or any other systemic complaints. On examination, the external nasal framework revealed widening of the nasal bridge and increased intercanthal distance of about 3 cm. Anterior rhinoscopy revealed a reddish, soft, friable, fleshy mass which bled on touch even with gentle probing, occupying the whole of nasal cavity and extending posteriorly into the choana. In the oral cavity, gingivobuccal sulcus, alveoli, hard palate and teeth were normal. Examination of neck was normal with no palpable cervical lymph nodes.

Routine blood investigations were normal. On subjecting the patient to radiological investigations, CT scan of the nose and PNS with 1 mm cuts with contrast showed a uniformly enhancing homogeneous soft tissue opacity occupying the left nasal cavity, extending posteriorly to choana and involving the maxillary sinus with erosion of its anterior and posterolateral walls. On coronal cuts, there was erosion of the pterygopalatine plates and inferior orbital wall. Considering the age and sex of the patient, symptoms of unilateral nasal obstruction and epistaxis with a bleeding mass on anterior rhinoscopy and a contrast enhancing mass on CT scan involving nasal cavity and nasopharynx, a provisional diagnosis of Juvenile Nasopharyngeal Angiofibroma was made and preoperative embolisation done followed by surgical clearance by lateral rhinotomy approach. Intraoperatively, a soft friable mass was found in the left nasal cavity extending into the posterior choana and left maxillary antrum with erosion of the anterior maxillary wall, posterolateral wall with intact mucoperiosteum. There was erosion of the orbital floor without any intraorbital extension. The infraorbital nerve and nasolacrimal duct were involved by the tumour and were sacrificed and tissue around the infraorbital nerve sent to histopathological analysis. The antrum and nasal cavity were packed with BIPP after securing the floor of orbit and wound sutured in layers.

Patient was on Ryle's tube feeds until 10th postop day and nasal pack was removed on the 4th postop day. Histopathological examination showed pseudostratified columnar epithelium with underlying tissue having tumour comprised of sheets of cells with moderate amount of cytoplasm, eccentric nuclei and granular chromatin suggestive of Plasmacytoma/Lymphoma/Undifferentiated carcinoma for which immunohistochemistry was positive for CD 138, negative for CD 45 and CK negative suggestive of plasmacytoma. Serum electrophoresis, bone marrow aspiration, bone marrow biopsy were within normal limits and thus multiple myeloma was ruled out. Skeletal survey did not reveal any solitary bone lesions. Haematological tests for calcium and renal function tests were normal. Patient was further managed with adjuvant radiotherapy with 45 Gy in 25 fractions at 1.8 Gy per day 5 days a week.

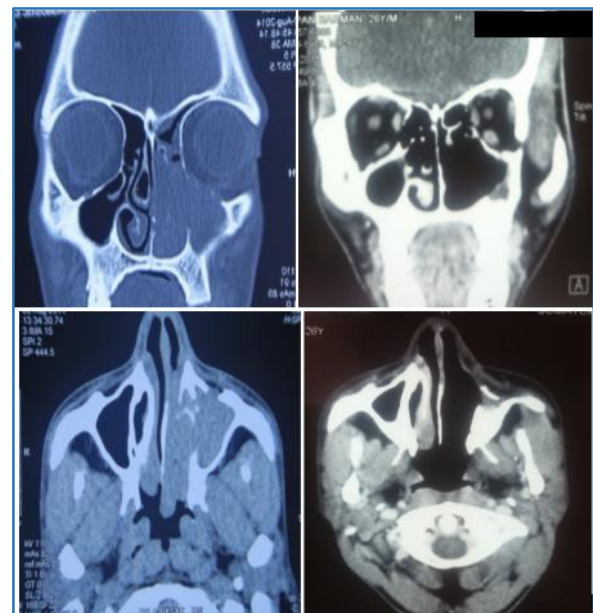


Fig. 1: Pre-op and Post-op CT after One Year which Shows No Evidence of Recurrence

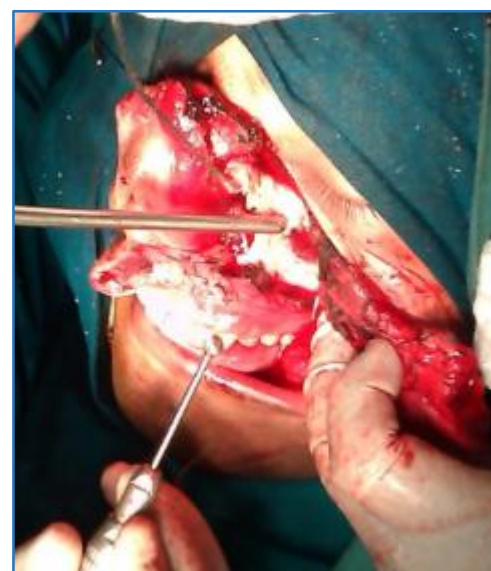

Fig. 2: Intraoperative Picture Showing Tumour Eroding the Anterior Wall of the Maxillary Sinus and Nasal Cavity

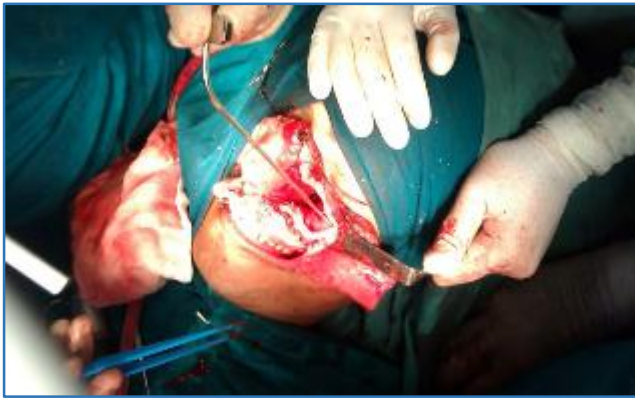

Fig. 3: Intraoperative Picture of Exposure of Tumour in the Left Maxillary Sinus

DISCUSSION: Plasma cells are mature immunocompetent cells derived from B lymphocytes and provide humoral immunity within the immune system. They produce specific antibodies against specific antigens in different tissues. Plasmacytomas are discrete, solitary mass of neoplastic monoclonal plasma cells in either bone or soft tissue (extramedullary). The commonest immunoglobulin expressed by the tumour cells is IgG. They differ from multiple myeloma in that though they have identical plasma cells similar to multiple myeloma, they do not present with systemic involvement.

The International Myeloma working group.¹ classified plasmacytomas into:

1. Solitary bone plasmacytoma.
2. Solitary extramedullary plasmacytoma.
3. Multiple Plasmacytoma (\pm Recurrent).

Extramedullary plasmacytoma consists of 3-4% of all plasma cell disorders. They commonly present in the 5th to 7th decade of life with a male preponderance of 3:1. In the head and neck region, it affects the sinonasal tract the most (45%), followed by nasopharynx, oropharynx and larynx and the clinical features depend on the site of the tumour than the nature of the tumour. First described by Schridde² in 1905, it has been mapped cytogenetically to chromosomal losses in 13, 1p and 14q and gains in 19p, 1q and 9q arms. The estimated global incidence of disease is 1 case per 5, 00,000 people.³ Wiltshaw's clinical staging⁴ of the EMP consists of the following:

Stage I: Limited to Extramedullary Site.

Stage II: Involvement of Regional Lymph Nodes.

Stage III: Multiple Metastases.

The UK Myeloma Forum¹ has laid down the diagnostic criteria of EMP as follows:

Single extramedullary mass of monoclonal plasma cells with histologically normal bone marrow aspirate, normal skeletal survey including radiology of long bones, no evidence of plasma cell dyscrasias like anaemia, hypercalcaemia or renal impairment and absence or low urinary level of monoclonal immunoglobulins. Based on the Natural history of the disease, 5 possible stages of EMP was described by Batsakis.⁵

1. Localised disease; solitary; controlled by surgery, radiotherapy, or both; without recurrence; or disseminated.
2. Disease with local recurrence controlled by additional therapy.
3. Aggressive disease, persistent or recurrent; death by uncontrollable local extensions.
4. Local disease with regional lymph node "metastasis" without evidence of distant spread.
5. Local disease, recurrent or followed by dissemination and development of another neoplasm of plasma cells and/or multiple myeloma.

CT, MRI and complete endoscopic examination of the aerodigestive and gastrointestinal tracts are required to determine the exact extent of the tumour and its potential for resectability. Deep biopsies are indicated as tumour is submucosal and the mucosal lining can become thicker because of inflammatory reaction. Tumours involving the maxillary sinus are known to have worst prognosis. Histopathologically, EMP must be distinguished from reactive plasma cell lesions and lymphoma. It should be demonstrated that the infiltrate consists entirely of plasma cells and that there is no B cell component. In this regard, CD138, MUM1/IRF4, CD20 and PAX5 are the most useful markers although it should be recognised that CD20 and PAX5 are sometimes expressed in plasma cell malignancies. Monoclonality and/or an aberrant plasma cell phenotype should be demonstrated with useful markers being CD19, CD56, CD27, CD117 and cyclin D1.⁶

In a suspected case of EMP, differential diagnoses such as multiple myeloma, Waldenstrom's macroglobulinaemia, solitary plasmacytoma of bone should be ruled out. In order to exclude MM and solitary plasmacytoma-systemic blood investigations including urine analysis for Bence Jones proteins, skeletal survey, bone marrow biopsies as well as serum electrophoresis has to be performed. Though the treatment of EMP is primarily radiotherapy, a good surgical resection with postoperative radiotherapy is found to be the best mode of treatment. It was found that the survival rate exceeded more than 300 months in combined approach when compared to radiotherapy alone.⁷ Adequate radiotherapy results in long time disease-free survival with a low frequency of progression to Multiple myeloma. The role of chemotherapy⁸ is not proven though some authors believe that it may at least delay progression to multiple myeloma. Chemotherapy may also be considered for patients with refractory or recurrent disease. In the present case, the patient was symptom free in the first two years of followup with no evidence of progression to myeloma haematologically and radiologically.

CONCLUSION: A differential diagnosis of EMP should be considered in all sinonasal tumours. EMP has a propensity to progress to Multiple Myeloma albeit lesser than Solitary Plasmacytoma, therefore a long term followup is mandatory.

This case was unique in its early age of presentation and was masquerading Juvenile Nasopharyngeal Angiofibroma. A multidisciplinary approach with a combination of surgery and radiotherapy is found to benefit the patient significantly.

REFERENCES

1. International myeloma working group. Criteria for the classification of monoclonal gammopathies, multiple myeloma and related disorders: a report of the international myeloma working group. *Br J Haematol* 2003;121(5):749-757.
2. Schridde H. Weitere Untersuchungen Uber die Kornelungen Plasmazellen. *Centralbl Allg Pathol Anatol* 1905;16:433-435.
3. Fernandes AM, Podovani JA, Maniglia JP. Plasmocitoma extramedular de nasofaringe: relato de um casoe revisão da literatura. *Rev Bras Otorrinolaringol* 1998;64:296-298.
4. Wiltshaw E. The natural history of extramedullary plasmacytoma and its relation to solitary myeloma of bone and myelomatosis. *Medicine* 1976;55(3):217-238.
5. Batsakis JG. Plasma cell tumors of the head and neck. *Ann Otol Rhinol Laryngol* 1992;92:311-313.
6. Hughes M, Soutar R, Lucraft H, et al. Guidelines on the diagnosis and management of solitary plasmacytoma of bone, extramedullary plasmacytoma and multiple solitary plasmacytomas. Working Group of UKMF Guidelines Working Group 2009.
7. Alexiou C, Kau RJ, Dietzfelbinger H, et al. Extramedullary carcinoma: tumour occurrence and therapeutic concepts. *Cancer* 1999;85(11):2305-2314.
8. Kamponis P. Maxillary sinus plasmacytoma- a case report. *Otorhinolaryngologia- Head and Neck Surgery* 2011;46:45-48.