ORIGINAL ARTICLE

A PROSPECTIVE STUDY TO ASSESS EFFICACY OF DIRECTLY OBSERVED TREATMENT SHORT-COURSE INTERMITTENT REGIME IN DIFFERENT STAGES OF SPINAL TUBERCULOSIS

Manoj Kumar H. V[1], Somashekara S. A[2], Shivaraj N[3], Abhijit Patil[4], Suresh M[5]

HOW TO CITE THIS ARTICLE:
Manoj Kumar H. V, Somashekara S. A, Shivaraj N, Abhijit Patil, Suresh M. "A Prospective Study to Assess Efficacy of Directly Observed Treatment Short-Course Intermittent Regime in Different Stages of Spinal Tuberculosis". Journal of Evidence based Medicine and Healthcare; Volume 2, Issue 7, February 16, 2015; Page: 865-878.

ABSTRACT: STUDY DESIGN: A Prospective non-randomised study. **INTRODUCTION:** Management of Tuberculosis spine still possesses many challenges. Availability of anti- tubercular drugs has changed the outcome. However, present recommendation by the WHO of Directly Observed Treatment Short-course (DOTS) has sound scientific basis, but the optimum duration is still controversial. We conducted a prospective study on a consecutive series of patients with spinal tuberculosis treated with Category I Revised National Tuberculosis Control Programme (RNTCP) regime based on DOTS strategy from June 2012 to Sep 2014 to evaluate the efficacy and come to conclusion regarding optimum duration of treatment. **MATERIALS AND METHODS:** A prospective study of 30 consecutive patients of spinal tuberculosis treated with Category I RNTCP based on DOTS strategy. All the patients were followed for minimum of 2 year. Surgical intervention was done in patients presenting with significant neurological deficits. Patients diagnosed clinicoradiologically and histopathologically (n=3) were enrolled in the study. Outcome was graded into excellent, good, fair and poor based on clinical, laboratory including return of ESR to normal and correction of lymphocytosis and radiological outcome showing - return to normal bone density and sclerosis, bony ankylosis and disappearance of marrow edema on MRI. **RESULTS:** In 30 cases, 63.4% (n=19) were males and 36.7% (n=11) were females. 10% (n=3) were with pre-destructive lesion, 53.3% (n=16) were in the early destructive phase, 30% (n=9) with mild angular kyphosis and 6.67% (n=2) with moderate angular kyphosis. Outcome of our study were excellent in 46.67% (n=14), good in 36.67% (n=11), fair in 10% (n=3) and poor in 6.67% (n=2). Duration to cure spinal TB 6 months 30% (n=9), 9 months 56.67% (n=17) and 12months 13.33% (n=4). **CONCLUSIONS:** Outcome of our study were excellent in 46.67% (n=14), good in 36.67% (n=11), fair in 10% (n=3) and poor in 6.67% (n=2). The duration of treatment for cure of spinal TB in 100% (n=3) pre-destructive and 37.5% (n=6) early destructive phases was 6 months, 62.5% (n=10) early destructive and 77.76% (n=7) mild kyphotic phases was 9 months and 22.2% (n=2) mild destructive and 100% (n=2) moderate kyphotic phases was 12 months. Favourable outcome and short duration of chemotherapy is adequate in patients treated early.

KEYWORDS: DOTS, Middle-path regime, TB spine, RNTCP.

INTRODUCTION: The treatment of TB spine has undergone changes over decades. To start with, the essence of treatment was complete, prolonged uninterrupted rest. The discovery of specific drugs revolutionized the treatment of tuberculosis. Along with advances in anesthesia and

advent of anti-tubercular drugs, surgical treatment has become possible, when indicated. Modern anti-tubercular drugs have accelerated the rate and quality of recovery and have minimized the incidence of mortality, complications, and relapse.[1, 2] Depending on the combination and number of drugs, duration of treatment, and frequency of drug administration, there are a number of treatment regimens available. Directly observed treatment, short-course (DOTS) is a brand name of the world health organization (WHO) recommended TB control strategy. It is vital for the success of TB control that the health care workers should treat TB patients within the framework of Revised National Tuberculosis Control Programme (RNTCP).[1,2,3]

In the "middle-path" regime, neither practice of universal surgical extirpation nor an absolutely conservative approach is practiced. Treatment of patients is mostly on non-operative lines with anti-tubercular chemotherapy (DOTS), rest and spinal braces when there is minimal bony destruction and no neural compression.

The efficacy of DOTS in Pulmonary TB is proven beyond doubts whereas evidence for efficacy in TB spine is lacking. This study assesses the effectiveness of DOTS regimen in spinal tuberculosis, the frequency and type of side effects, and the effect of the regimen in the various stages of the disease.

MATERIAL AND METHODS: A prospective non-randomized study of patients with spinal TB was done. A total of 30 patients were evaluated and assessed during the period from November 2012 to September 2014. The study was conducted in Victoria hospital and Bowring and Lady Curzon Hospitals Department of Orthopedics, Bangalore Medical College and Research Institute. Patients with spinal Tuberculosis fulfilling the inclusion and exclusion criteria were taken in to study after obtaining written informed consent.

INCLUSION CRITERIA:

1. Patients more than 18 yrs of age.
2. Patients with clinico-radiological evidence of spinal TB.
3. Patients with histopathological evidence of spinal TB- when diagnosis is in dilemma.
4. Patients with/without neurological deficits.

EXCLUSION CRITERIA:

1. Patients not consenting for the treatment.
2. Patients less than 18 yrs of age.
3. Patients with treatment failure and default.
4. Patients with HIV +ve/immunocompromised status, disseminated disease involving multiple organs.
5. Patients with abnormal LFT.
6. Patients associated with scoliosis/other pathologies in spine.
7. Patients with neurological conditions like Parkinsonism, Hemiplegia.
8. Pregnant women.

Patients suspected to have spinal tuberculosis were investigated with:

1. Blood investigations- Hemogram, ESR, CRP, RFT, LFT.
2. Radiological investigations: X-ray spine AP and lateral views, Magnetic Resonance Imaging(MRI).
3. Screened for HIV.
4. Histopathological examination(HPE) of specimen. Specimen taken under asepsis in elective OT under fluoroscopic guidance- when diagnosis is in dilemma.
5. Ophthalmological evaluation such as fundoscopy(at initiation).

All patients diagnosed with spinal tuberculosis were treated by Category I DOTS regimen used for seriously ill extrapulmonary disease.3 This consisted of four drugs (INH 15 mg/ kg, Rifampicin 10mg/kg, Ethambutol 25-30 mg/kg, and Pyrazinamide 50-70 mg/kg) administered under direct observation by a trained personnel, three times a week for two months, followed by two drugs (INH and Rifampicin), thrice weekly for four months or until regression of symptoms along with laboratory and radiological signs of resolution, whichever was later:

Return of ESR and CRP to normal and correction of lymphocytosis.

Radiological signs of healing like;

a) X-ray: return to normal bone density and sclerosis, reduction in paravertebral soft tissue shadow.
b) MRI scan: regression of bone marrow enhancement, pathological soft tissue swelling on magnetic resonance imaging at 9/ 12 months.

Drugs given to all patients were free of cost and assured quality supplied by the concerned health bodies under Revised National Tuberculosis Control Programme (RNTCP) of Government of India. Patients were treated initially as inpatients for 2 to 3 days to watch for any adverse drug reaction. Once the patient was tolerating the treatment well, patients were discharged with a reference letter to the nearest DOTS provider. Patients who were ambulatory at the time of diagnosis were kept ambulatory during treatment with spinal brace, with restriction of heavy and load-bearing activities. Compliance was ensured using frequent field visits, random checking, quality assessment protocols, and modern management principles by RNTCP personnel.

SUPPORTIVE THERAPY: All patients received supportive therapy with iron, multivitamins, B-complex and protein rich diet.

Patients were followed up regularly at mentioned period for (3 wks, 3, 6, 9 months):

1) Clinical improvement.
2) Return of ESR and CRP to normal and correction of lymphocytosis.
3) Radiological signs of healing like.
   - **X ray:** return to normal bone density and sclerosis, reduction in paravertebral soft tissue shadow.
   - **MRI scan:** regression of bone marrow enhancement, pathological soft tissue swelling on magnetic resonance (taken both at initiation and cessation of ATT).

If the patient develops drug intolerance like persistent allergic rash, increase in liver enzyme levels, drug therapy was altered as per the advice of the pulmonologist. This was done by stopping all the drugs for 2 to 3 days, then introducing one drug at a time over the next 10 to 15 days while keeping the patient admitted and monitoring the patient clinically and by LFT. If during the course of treatment neurological deficit progressed, the patients were subjected for a surgical decompression. Indications for surgery in Pott's spine:

1) Paraplegia arising while the patient is under adequate conservative treatment for TB spine.
2) Paraplegia deteriorating despite of adequate conservative treatment.
3) Paraplegia of rapid onset.
4) Severe paraplegia.
5) Recurrent paraplegia.
6) Posterior spinal disease.
7) Severe cauda equine paralysis.

After the completion of 6 months of ATT, if the patient has relief of pain, ESR and CRP are back to normal and imaging studies (x-ray and MRI scan) showed signs of healing, then treatment was stopped. Patients were followed up once in every three months after successful completion of ATT. However, if the patient was having persistent pain, elevated ESR, progression of neurological deficit, increase in size of the abscess or progression of kyphosis, the treatment was continued till 9 months or 12 months and surgical intervention by decompression and instrumentation was done as required.

Stage	Clinico-radiological features	Usual duration
I) Pre-destructive	Straightening of curvatures, spasm of perivertebral muscles, MRI shows marrow edema	< 3 months
II)Early destructive	Diminished disc space + para-discal erosion (knuckle <10 deg) MRI shows marrow edema and break of osseous margins	2-4 months
III, IV, V all have vertebral bodies destruction and collapse + appreciable kyphos		
III)Mild angular kyphosis	2-3 vertebrae involved K angle: 10-30 deg	3-9 months
IV)Moderate angular kyphosis	>3 vertebrae involved K angle: 30-60 deg	6-24 months
V)Severe kyphosis	>3 vertebrae involved K angle: > 60 deg	>2 yrs

Table 1: Staging of TB spine (MRC grading)[1,2]

Stage		Clinical features
I	Negligible	Patient unaware of the neural deficit, physician detected plantar extensor and/ or ankle clonus
II	Mild	Patient aware of deficit but manages to walk with support
III	Moderate	Non ambulatory because of paralysis(in extension), sensory deficits less than 50%
IV	Severe	Grade III + flexor spasms/ paralysis in flexion/ flaccid, sensory deficits more than 50% with sphincter involvement

Table 2: Grading of paraplegia is as follows:[1,2]

Surgery in TB spine is indicated only in case of neurological complications. Indications for surgery in Pott's paraplegia:[1,2,3]

8) Paraplegia arising while the patient is under adequate conservative treatment for TB spine.
9) Paraplegia deteriorating despite of adequate conservative treatment.
10) Paraplegia of rapid onset.
11) Severe paraplegia.
12) Recurrent paraplegia.
13) Posterior spinal disease.
14) Severe cauda equine paralysis.

The following criteria were taken into consideration for grading final outcome:

1) Clinical evidence of cure such as relief of symptoms, marked reduction in pain, increase in physical endurance and,
2) Return of ESR, CRP and differential counts to normal,
3) Radiological (X ray and MRI scan).
4) Frequency and nature of adverse drug reactions.
5) Progression of kyphosis (>30 degree from beginning the treatment) at affected level at the end of treatment/ side effects that forced to discontinue treatment.
6) Failure of treatment by nine months, like patient having persistent pain, elevated ESR, progression of neurological deficit, increase in size of the abscess, or progression of kyphosis, necessitating continuation beyond 9 months/addition of drugs.
7) Failure of non-operative treatment and/or progression of neurological deficit requiring surgical intervention.

On this basis of above criteria, results were classified into the following four groups:[1,4]

1) **Excellent result:** Complete resolution of disease with DOTS regimen for 6 months, with no residual disability or deformity and absent or minor adverse drug reactions.

2) **Good result:** Complete resolution of disease with DOTS regimen for 9 months with no residual disability or deformity and with the occurrence of medically manageable side effects of drug therapy, such as gastrointestinal intolerance, drug-induced jaundice, etc.
3) **Fair result:** Complete resolution of disease, but with a post-treatment kyphosis deformity of 30 degrees or more at the affected level or the patients had to be shifted to second line drugs, or patients who are having mild residual pain which is however not limiting their physical activity.
4) **Poor result:** Cases that did not respond to conservative treatment, primary or secondary line, had a deteriorating neurological deficit and had to be operated.

CASE PHOTOGRAPHS

1. CASE OF L4 – L5 POTT'S SPINE- EARLY DESTRUCTIVE STAGE:

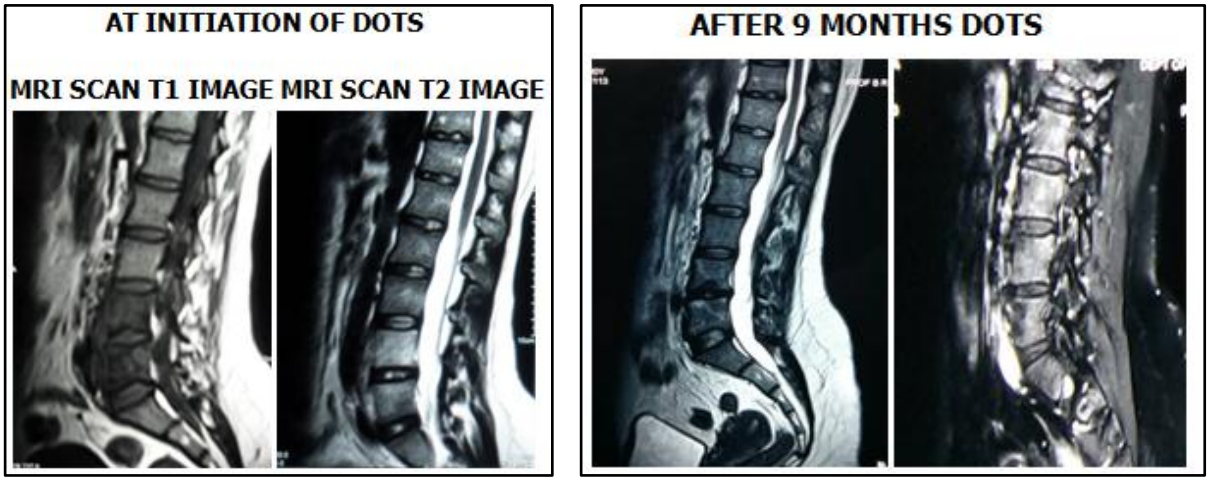

2. CASE OF L4–L5-S1-S2 POTT'S SPINE- EARLY DESTRUCTIVE STAGE

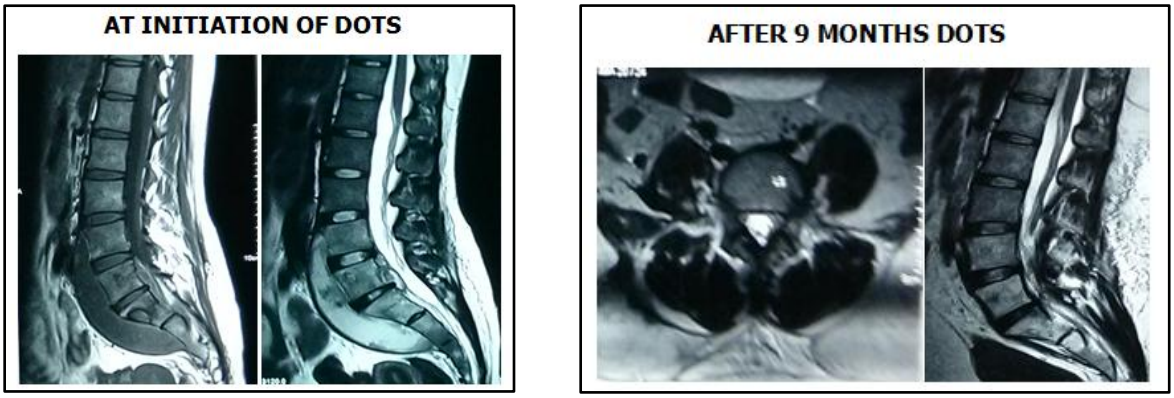

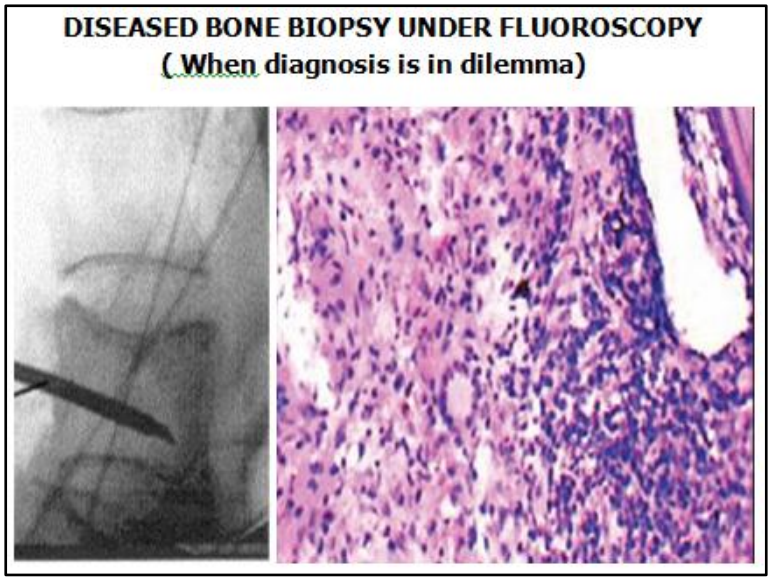

RESULTS: In 30 cases, 63.4% (n=19) were males and 36.7% (n=11) were females. 10% (n=3) were with pre-destructive lesion, 53.3%(n=16) were in the early destructive phase, 30% (n=9) with mild angular kyphosis and 6.67% (n=2) with moderate angular kyphosis. Diagnosis of TB spine was on the basis of clinical examination and radiological investigations and tissue diagnosis was obtained in 3(10%) due to dilemma in diagnosis. Majority of patients on radiological studies were in early destructive stage followed by mild destructive and pre-destructive associated with cold abscess in half the cases. Average mean angle of kyphosis was 11.3deg and skip lesion was noted in 3.3% (n=1). Bony ankylosis was noted in 7(23.3%) patients.

Among 30 patients, 10(33.3%) had neurological deficits. Overall 3(10%) were in stage I, 6(20%) in stage II and 1(3.3%) in stage III. Among 10 patients with neurological deficits, 5 (50%) recovered with conservative treatment and 5 (50%) needed surgical intervention.

Duration to cure spinal TB was 6 months in 30% (n=9), 9 months in 56.67%(n=17) and 12months in 13.33%(n=4) of the patients. Patients diagnosed early in pre and early destructive stages needed ATT for 6months, whereas the later stages like mild and moderate kyphosis stages needed continuation till 9 or 12 months. Patients were followed up regularly on mentioned period. Average mean ESR at initiation of treatment was 57mm/hr (27-80mm/hr) followed by significant fall with treatment. All patients tolerated treatment well except for minor side-effects like GI disturbances. As there is no standardized assessment score for outcome of treatment in spinal TB, outcome was graded as excellent/ Good/ Fair/ Poor. Outcome of our study were excellent in 46.67% (n=14), good in 36.67% (n=11), fair in 10% (n=3) and poor in 6.67% (n=2).

In our series, 3(21.4%) patients in pre-destructive stage and 11(78.6%) in early destructive had excellent outcome, 5(45.5%) patients in early destructive and 6(54.5%) in mild kyphotic stages had good outcome, 3(100%) patients in mild kyphotic stage had fair outcome and 2(100%) patients in moderate kyphotic stage had poor outcome.

Duration of ATT was dependent on stage of disease, 3(100%) pre-destructive lesions were cured in 6 months, 6(37.5%) and 10(62.5%) early destructive lesions were cured 6 and 9

months respectively, 7(77.8%) and 2(22.2%) mild kyphotic lesions were cured in 9 and 12 months respectively and 2(100%) moderate kyphotic lesions were cured in 12 months.

DISCUSSION: In our prospective study of 30 patients, diagnosis in 27(90%) was on the basis of clinical examination and radiological investigations and tissue diagnosis was obtained in 3(10%) patients when in dilemma about the diagnosis. Tissue diagnosis is not essential in all patients at the initiation of DOTS except, when there is dilemma about diagnosis.

Majority of patients on radiological studies were in early destructive stage 16(53.3%) followed by mild kyphosis 9(30%), pre-destructive in 3(10%) and cold abscess was noted in 15(50%) cases. In contrary to most studies, lumbar spine was most commonly involved followed by Thoraco-lumbar spine. Average mean angle of kyphosis was 11.3deg. Number of vertebral involvement was pre-dominantly 2 followed by 3 vertebrae. The average mean vertebral bodies involved are 2.3 ranging from 2-4 vertebrae.

Authors	Pre-destructive	Early destructive	Mild Kyphosis	Moderate Kyphosis	Severe Kyphosis
Valsalan et al[3]	8 (19.5)	18 (43.9)	12 (29.3)	3 (7.3)	-
Present study	3 (10)	16 (53.3)	9 (30)	2 (6.7)	-

Table 3: Stage of disease

Level of lesion	MRC (Hong Kong)[11] (%)	MRC (Madras)[12] (%)	MRC (Korea)[9] (%)	S.M.Tuli[1,2] (%)	Bavadekar[8] (%)	Valsalan et al[14] (%)	Present study (%)
Cervical	-	-	-	-	-	-	1 (3)
Dorsal	18 (36)	93 (37)	62 (41)	42 (42)	202 (27)	12 (29.3)	1 (3)
Dorsolumbar	4 (8)	33 (13)	32 (21)	12 (12)	235 (31.3)	10 (24.4)	11 (36.7)
Lumbar	28 (50)	124 (50)	57 (28)	26 (26)	160 (21)	19 (46.3)	17 (56.7)

Table 4: Level of lesion

Authors	1-2 vertebrae (%)	3-4 vertebrae (%)	5 and above (%)
MRC (Hong Kong)[5]	44 (88)	5 (10)	1 (2)
MRC (Madras)[6]	172 (69)	69 (28)	9 (4)
MRC (Korea)[7]	63 (42)	58 (38)	30 (20)
Present study	22 (73.3)	10 (26.7)	-

Table 5: Number of vertebra involved

All the patients received ATT as per DOTS strategy. Patients diagnosed early in pre and early destructive stages needed ATT for 6months, whereas the later stages like mild and moderate kyphosis stages needed continuation till 9 or12 months. As the radiological healing lags behind anatomical by 3-4 months, tissue examination should guide duration of ATT. We could not follow the same guidelines due to various difficulties in obtaining tissue biopsy and clinicoradiological assessment was supplemented as guide to duration of ATT.

Authors	Pre-destructive	Early destructive	Mild Kyphosis	Moderate Kyphosis	Severe Kyphosis
Valsalan et al[3]	8 (19.5)	18 (43.9)	12 (29.3)	3 (7.3)	-
Present study	3 (10)	16 (53.3)	9 (30)	2 (6.7)	-

Table 6: Stage of disease

Stage of disease/ Duration to the cure	6 months	9 months	12 months	Total (%)
Pre-destructive	3	0	0	3(10)
Early destructive	6	10	0	16(53.3)
Mild kyphosis	0	7	2	9(30)
Moderate kyphosis	0	0	2	2(6.7)
Severe kyphosis	0	0	0	0
Total (%)	**9(30)**	**17(56.7)**	**4(13.3)**	**30(100)**

Table 7: Stage of disease vs duration of ATT

Patients were followed up regularly on mentioned period. Average mean ESR at initiation of treatment was 57mm/hr(27-80mm/hr) followed by significant fall with treatment. All patients tolerated treatment well except for minor side-effects like GI disturbances. As there is no standardized assessment score for outcome of treatment in spinal TB so outcome graded as Excellent/ Good/ Fair/ Poor.

Authors	Excellent (%)	Good (%)	Fair (%)	Poor (%)
Nene et al[8]	34 (48.5)	19 (27)	16 (23%)	1(1.5%)
Valsalan et al[3]	26 (63.4)	6 (14.6)	6 (14.6)	3 (7.3)
Present study	14 (46.7)	11 (36.7)	3 (10)	2 (6.7)

Table 8: Outcome of treatment

The pre-destructive and early destructive groups are taken as early presenters and the rest as late presenters and also combining excellent and good as favorable outcome and fair and poor as unfavorable response, a Fishers 2-tailed exact test was done3. P value was 0.0032, association is statistically significant.

Present study	Favourable	Unfavourable
Early presenters	19	0
Late presenters	6	5

Authors	Treatment	Results (%)
Hodgson[9]	Radical operation	95
Wilkinson[10]	Radical operation	96
S.M.Tuli&Kumar[1,2]	Middle- path regime	95
Bawadekar[11]	Radical operation	98
Present series	Middle-path regime	94

Table 9: Outcome of treatment among various studies

CONCLUSION: DOTS strategy is as effective as short-course daily regimen in early stages of disease. The outcome of ATT is mainly dependent of stage of disease (destruction/collapse) at initiation. Favorable outcome and short duration of chemotherapy is needed in patients treated early.

We conclude that:

1) DOTS regime is efficacious in TB spine, Pre and Early destructive stages have excellent results with cure rate of 100% with extended DOTS regime (9months).
2) The functional outcome is Excellent in pre and early destructive, fair in mild kyphosis and poor in moderate kyphosis stages of TB spine.
3) The duration to cure TB spine is 9 months DOTS with cure rate of 86.7%.
4) The complications of anti-tubercular therapy are greatly reduced with DOTS regime with minor GI disturbance and skin rashes, not needing cessation or alteration drug therapy.

Master chart:

Sl no	Name	Age	Sex	IP/OP No/Hospital	HPE	HIV	Sputum AFB	Chief complaints	Duration of symptoms	Stage of disease	Angle of kyphosis(deg)	Abscess
1	Anupama	32	F	O-30501/VH		Neg	Neg	Backache	4 months	Early destruction	4	No
2	Ashok mandal	50	M	I-32153/BLCH		Neg	Pos	LBA, weakness	1 yr	Mod kyphosis	34	Yes
3	Basheer unissa	20	F	I-29672/BLCH	Postive	Neg	Neg	LBA	2 months	Early destructive	6	Yes
4	Dayamanna	60	M	0-20687/ BLCH		Neg	Neg	LBA	3 months	Early destruction	4	Yes
5	Fairoz	28	M	0-3688/BLCH		Neg	Neg	LBA	2.5 months	Early destructive	8	No
6	Geethamma	40	F	O-21284/VH		Neg	Neg	LBA	3 months	Early destruction	6	No
7	Haleema Bi	65	F	BLCH		Neg	Pos	Backache, weakness	1.5 yrs	Mod kyphosis	32	Yes
8	Jagadish	37	M	VH		Neg	Neg	LBA	2.5 months	Early destructive	8	No

9	Lokanathan	40	M	VH		Neg	Neg	Backache, weakness	5 months	Mild kyphosis	12	Yes
10	Lokesh	39	M	BLCH		Neg	Pos	LBA	3 months	Early destructive	6	No
11	Mala	19	F	I-944404/VH		Neg	Neg	LBA, cold abscess	8 months	Mild kyphosis	14	Yes
12	Meher Taj	52	F	I-13088/BLCH		Neg	Pos	LBA, weakness	7.5 months	Mild kyphosis	22	Yes
13	Mohan	27	M	BLCH		Neg	Pos	Backache	2 months	Early destructive	6	No
14	Amavashe	34	M	BLCH		Neg	Pos	Backache, chronic cough	4 months	Early destructive	4	Yes
15	Naseeha	45	F	BLCH		Neg	Neg	Backache	4.5 months	Early destructive	8	No
16	Pandrappa	54	M	I-963801/VH	Positive	Neg	Pos	Backache	6 months	Mild Kyphosis	16	Yes
17	Pandey	45	M	VH		Neg	Neg	Backache	3.5 months	Early destructive	4	No
18	Radha krishna	48	M	VH		Neg	Neg	Backache	2 months	Early destructive	8	No
19	Pavithra	20	F	O-143768 /BLCH		Neg	Neg	LBA, cold abscess	2 months	Early destructive	4	Yes
20	M Sangeetha	33	F	BLCH		Neg	Neg	LBA	3 months	Early destructive	6	No
21	Selvam	45	M	I-74366/BLCH		Neg	Neg	Backache, weakness, cold a	5 months	Mild kyphosis	18	Yes
22	Shaheen Taj	45	F	BLCH		Neg	Pos	Backache	7 months	Mild kyphosis	26	Yes
22	Shaheen Taj	45	F	BLCH		Neg	Pos	Backache	7 months	Mild kyphosis	26	Yes
23	sharfinuissa	26	F	I-02283/BLCH		Neg	Neg	LBA	5.5 months	Mild kyphosis	14	Yes
24	Siddique faizal	19	M	O-42238/VH		Neg	Neg	Constitutional symptoms	1.5 months	Pre destructive		No
25	Sunil kumar	19	M	O-0565/BLCH		Neg	Neg	Backache	2 months	Pre destructive		No
26	Suresh	28	M	0-6081/BLCH		Neg	Pos	LBA	6 months	Mild kyphosis	12	Yes
27	Upendra	38	M	0-1596/BLCH		Neg	Neg	LBA	2 months	Pre destructive		No
28	thirumalesh	25	M	BLCH	Postive	Neg	Neg	Backache	4 months	Mild kyphosis	14	Yes
29	Ganganna	48	M	VH		Neg	Pos	LBA	2 months	Early destructive	4	No
30	Kumar	50	M	VH		Neg	Neg	Backache	3 months	Early destructive	6	No

					TC				ESR				CRP			
Neurological status	**Duration of neurological deficits**	**Vertebral level**	**No of VB involved**	**ATT started**	**Baseline**	**12 wks**	**6 mts**	**Final**	**Base line**	**12 wks**	**6 mts**	**Final**	**Base line**	**12 wks**	**6 mts**	**Final**
Absent		T9-10	2	5/8/13	9600	8230	6890	5300	65	33	22	14	+ve	+ve	+ve	-ve
Stage III	12 months	L2-3-4-5	4	29/10/12	11200	10230	9600	7900	72	60	42	5	+ve	+ve	+ve	-ve
Stage I	2 months	L4-5	2	21/9/12	10650	8300	6700	5800	60	42	21	15	2.52	+ve	-ve	0.2
Absent		L3-4	2	5/4/12	10800	9600	9200	7600	35	20	8	5	1.2	0.7	-ve	-ve
Absent		L1-2	2	6/12/12	8700	7400	6450		55	37	14		+ve	-ve	-ve	
Absent		L5-S1	2	7/9/12	7600	7230	7050	6500	46	30	22	9	+ve	+ve	-ve	-ve
Stage II	10 months	T9-10	2	10/11/12	9870	8400	7560	6800	68	56	45	22	2.82	2.14	-ve	0.25

Absent		L1-2	2	23/4/13	8910	7680	7320		47	32	20	11	+ve	+ve	-ve	-ve
Stage II	4 months	T9-10	2	7/10/13	7890	7570	6840	6310	63	48	25	13	+ve	+ve	-ve	-ve
Absent		L4-5	2	24/10/12	8670	8120	7840	7100	49	32	22	13	+ve	-ve	-ve	-ve
Absent		L2-3-4	3	10/7/12	12200	10500	7800	5600	50	46	20	12	+ve	+ve	-ve	-ve
Stage II	6 months	L3-4-5	3	21/9/13	7650	7230	7360	6980	53	38	26	14	+ve	+ve	-ve	-ve
Absent		T12-L1	2	28/9/12	9300	8370	7650		52	39	14		+ve	+ve	-ve	
Absent		C5	1	2/12/13	8920	7830	6560		68	52	17		+ve	+ve	-ve	
Absent		T12-L1-2	3	25/1/13	10400	9950	6580	5460	60	42	28	11	+ve	+ve	-ve	-ve
Stage II	4 months	T10-11	2	18/3/13	18700	12450	10340	9390	50	34	27	11	+ve	+ve	-ve	-ve
Absent		T12-L1	2	6/2/13	9870	8650	7860	7970	64	41	35	20	+ve	+ve	+ve	-ve
Absent		T12-L1	2	11/3/13	11320	9890	7380		58	35	13		+ve	+ve	-ve	
Absent		L4-5-S1-2	4	15/11/13	9400	8350	7900	7200	80	62	45	20	2.9	1.5	-ve	-ve
Absent		L3-4	2	5/8/13	8000	7600	6970		77	46	20		+ve	+ve	-ve	
Stage II	4 months	T10-11	2	20/1/14	11700	7800	7100	6870	55	40	20	14	+ve	+ve	-ve	-ve
Stage I	7 months	T8-9	2	26/7/12	11980	8000	7200	6850	50	46	25	16	+ve	+ve	-ve	-ve
Absent		SkipT7,L	3	3/10/13	10780	8780	7700	7540	76	62	40	22	+ve	+ve	-ve	-ve
Absent		L5-S1	2	4/8/12	11900	10230	8690		57	32	16		+ve	-ve	-ve	
Absent		L1-2	2	23/3/13	4700	4200	5160		28	14	10		+ve	-ve	-ve	
Stage I	5 months	L1-2-3	3	15/1/14	13300	8300	7600	6890	27	18	12	10	+ve	+ve	-ve	-ve
Absent		L4-5	2	21/2/14	8700	7560	7300		46	28	14		+ve	-ve	-ve	
Stage II	3 months	T9-10-11	3	15/11/13	11300	10500	9720	8400	63	51	36	20	+ve	+ve	-ve	-ve
Absent		L2-3	2	16/1/13	12500	11200	9730	8300	78	64	46	22	+ve	+ve	-ve	-ve
Absent		T11-12	2	15/4/13	8600	7450	7300	6800	58	42	35	16	+ve	+ve	-ve	-ve

General Condition	Complications	ATT Stopped	Duration (months)	Surgery	Outcome	Bonyankylosis
Hyp anemia, Old PTB	GI disturbance	29/3/14	9	No	Excellent	No
Hyp anemia, Bed Sores	Skin rashes	19/11/13	12	No	Poor	Yes
Hyp anemia		9/7/13	9	No	Good	No
Hyp anemia		12/7/13	9	No	Good	Yes
Hyp anemia		22/7/13	6	No	Excellent	No
Hyp anemia		19/7/13	9	No	Excellent	No
Hyp anemia	GI disturbance	16/11/13	12	No	Poor	Yes
Hyp anemia, old PTB		2/11/13	6	No	Excellent	No
Hyp anemia	Skin rashes	17/4/14	12	No	Fair	No
Hyp anemia		3/8/13	9	No	Good	No
Hyp anemia, TB lymphadenopathy		5/4/13	9	No	Good	No
Hyp anemia, Bed sores		27/9/14	12	Posterior stabilis	Fair	Yes
Hyp anemia		16/4/13	6	No	Excellent	No
Hyp anemia, Old PTB		13/6/14	6	No	Excellent	No
Hyp anemia		18/11/13	9	No	Good	No
Hyp anemia	GI disturbance	22/12/13	9	Drainage 1st mt	Good	Yes
Hyp anemia		23/11/13	9	No	Excellent	No
Hyp anemia		18/9/13	6	No	Excellent	No
Hyp anemia, TB lymphadenopathy	Skin rashes	27/8/14	9	No	Good	No

Hyp anemia		15/2/14	6	No	Excellent	No
Hyp anemia	GI disturbance	28/9/14	9	Posterior stabilis	Fair	Yes
Hyp anemia		2/5/13	9	No	Good	No
Hyp anemia, old PTB		9/7/14	9	No	Good	No
Hyp anemia		2/2/13	6	No	Excellent	No
Hyp anemia	GI disturbance	25/9/13	6	No	Excellent	No
Hyp anemia		28/9/14	9	Posterior stabilis	Good	Yes
Hyp anemia		2/9/14	6	No	Excellent	No
Hyp anemia, TB lymphadenopathy		24/8/13	9	Drainage	Good	No
Hyp anemia	GI disturbance	2/6/	9	No	Excellent	No

BIBLIOGRAPHY:

1. Tuli SM. Tuberculosis of skeletal system (bones, joints, spine and bursal sheaths) Third edition 2004(Jaypee Brothers medical publishers. New Delhi. India).
2. Tuli SM. Results of Treatment of Spinal Tuberculosis By "Middle-Path" Regime. JBJS Feb 1975; 57-B: 13-22.
3. Valsalan R, Purushothaman R et al. Efficacy of directly observed treatment short-course intermittent regimen in spinal tuberculosis. Indian J Orthop. 2012 Mar-Apr; 46(2): 138–144.
4. Jain AK, AmitSrivastava et al. Efficacy of extended DOTS category I chemotherapy in spinal tuberculosis based on MRI-based healed status. IndJ Orthop 2012 Nov; 46 (6): 633-36.
5. Medical Research Council. A 5 yr assessment of controlled trail of ambulatory treatment, debridement and anterior spinal fusion in the management of Tuberculosis of spine. Studies in Bulawyo and Hong Kong. VI Report. JBJS 1978; 60B: 163-77.
6. Medical Research Council. A 10 yr assessment of a controlled trail comparing debridement and anterior spinal fusion on the management of Tuberculosis spine on patients on the standard chemotherapy in Hong Kong. VIII Report. JBJS 1982; 64B: 393-98.
7. Medical Research Council. A controlled trail of Ambulant outpatient treatment and inpatient rest in bed in the management of tuberculosis of spine in Young Korean patients on standard chemotherapy. JBJS 1973; 55B: 678-97.
8. Abhay Nene, ShekharBhojraj. Results of Nonsurgical Treatment of Thoracic Spinal Tuberculosis in adults. The Spine Journal 2005; 5: 79–84.
9. Hodgson AR, Stock FE, Fang HSY. Anterior Spinal fusion. The Operative approach and pathological findings in 412 Pateroids with Pott's spine. Br J Surg 1960; 48: 172-78.
10. Wilkinson MC. Tuberculosis of the spine treated by Chemotherapy and Operative debridement. A long term Follow up study. JBJS 1969; 51A: 1331-42.
11. Bavadekar AV. Anterior spinal surgery in the management of the TB spine. Ind J Surg 1978 Mar: 131-51.

AUTHORS:

1. Manoj Kumar H. V.
2. Somashekara S. A.
3. Shivaraj N.
4. Abhijit Patil
5. Suresh M.

PARTICULARS OF CONTRIBUTORS:

1. Professor, Department of Orthopaedics, Bangalore Medical College and Research Institution.
2. Assistant Professor, Department of Orthopaedics, Bangalore Medical College and Research Institution.
3. Final Year Post Graduate, Department of Orthopaedics, Bangalore Medical College and Research Institution.
4. Senior Resident, Department of Orthopaedics, Bangalore Medical College and Research Institution.
5. Senior Resident, Department of Orthopaedics, Bangalore Medical College and Research Institution.

NAME ADDRESS EMAIL ID OF THE CORRESPONDING AUTHOR:

Dr. Manoj Kumar H. V,
Professor & Unit Chief,
Department of Orthopedics,
Bowring & Lady Curzon Hospital,
Shivaji Nagar, Bangalore-560001.
E-mail: orthomanoj@gmail.com
orthosoma@gmail.com

Date of Submission: 20/01/2015.
Date of Peer Review: 21/01/2015.
Date of Acceptance: 03/02/2015.
Date of Publishing: 13/02/2015.