

A CROSS-SECTIONAL MORPHOLOGICAL AND FUNCTIONAL EVALUATION OF FILTERING BLEBS FIVE YEARS POST TRABECULECTOMY

Jyoti Shetty¹, Michelle Clovis Da Costa², Jhanavi Jhamnan³, Fauqia⁴

¹Medical Director, Department of Ophthalmology, Bangalore West Lions Superspeciality Eye Hospital, Bangalore.

²DNB Student, Department of Ophthalmology, Bangalore West Lions Superspeciality Eye Hospital, Bangalore.

³Former Consultant, Department of Ophthalmology, Bangalore West Lions Superspeciality Eye Hospital, Bangalore.

⁴Consultant, Department of Ophthalmology, Bangalore West Lions Superspeciality Eye Hospital, Bangalore.

ABSTRACT

BACKGROUND

After trabeculectomy, wound remodelling and fibrosis continues lifelong and can affect bleb filtration. Ethnicity plays an important role in wound healing. Wound modulation with Mitomycin C affects the morphology as well as long-term functional success of the bleb.

The aim of the study is to assess the morphology of blebs 5 years post trabeculectomy using clinical methods (slit lamp biomicroscopy and Moorfields Bleb Grading System MBGS) along with Anterior Segment Optical Coherence Tomography (AS-OCT) and to correlate it with its functional outcome.

MATERIALS AND METHODS

This prospective cross-sectional study evaluated 40 eyes of 30 patients who had undergone trabeculectomy with adjuvant mitomycin C and had a postoperative duration of 5 years or more. Following a comprehensive ophthalmic examination, grading of filtering bleb was performed using MBGS. Internal bleb morphology was imaged using AS-OCT.

RESULTS

At the time of surgery, the age of the patients ranged from 33-71 years. The average postoperative duration was 8.6 ± 3.3 years. Based on slit lamp biomicroscopy, we found that 47% of the total blebs were diffuse, 30% were cystic and 23% were flat. MBGS parameters were studied in relation to bleb type on slit lamp. Bleb height ($p=0.001$) and central bleb vascularity ($p=0.010$) were found to have statistically significant association. There is a statistically significant agreement between the bleb type on slit lamp examination and morphological classification based on AS-OCT at $p<0.05$ ($p=0.000$). We observed complete success in 90% of eyes and qualified success in 100%. IOP at the time of study was found to have negative correlation with total bleb height on AS-OCT ($r: -0.3592$; $p=0.022909$).

CONCLUSION

This case series with a long-term followup period showed that trabeculectomy augmented with Mitomycin C (MMC) can achieve good long-term IOP control. The filtering bleb morphology using clinical methods (slit lamp biomicroscopy and MBGS) and AS-OCT was found to be consistent; therefore, indicating that clinical grading of bleb morphology is adequate and reliable in clinics in which imaging techniques are not available. In cases where IOP and bleb morphology do not correlate, AS-OCT is a useful tool to assess the internal bleb morphology and enhances our understanding of bleb functioning.

KEYWORDS

Moorfields Bleb Grading System, Bleb Morphology, Anterior Segment Optical Coherence Tomography, Trabeculectomy, Mitomycin C.

HOW TO CITE THIS ARTICLE: Shetty J, Da Costa MC, Jhamnani J, et al. A cross-sectional morphological and functional evaluation of filtering blebs five years post trabeculectomy. *J. Evid. Based Med. Healthc.* 2017; 4(48), 2954-2961. DOI: 10.18410/jebmh/2017/584

BACKGROUND

Glaucoma is a progressive optic neuropathy characterised by specific structural changes in the optic disc and particular

irreversible functional deficits in visual field¹ that is associated frequently, but not invariably with raised Intraocular Pressure (IOP).

In 2013, the number of people (aged 40-80 years) with glaucoma worldwide was estimated to be 64.3 million, increasing to 76.0 million in 2020 and 111.8 million in 2040.² The prevalence of glaucoma in rural south Indian population above 40 years of age was estimated to be 2.6% of which Primary Open-Angle Glaucoma (POAG) was 1.7% and Primary Angle-Closure Glaucoma (PACG) was 0.5% and secondary glaucoma excluding Pseudoexfoliation (PXF) was 0.3% according to the ACES study.³

Financial or Other, Competing Interest: None.

Submission 27-05-2017, Peer Review 02-06-2017,

Acceptance 14-06-2017, Published 15-06-2017.

Corresponding Author:

Dr. Fauqia,

Consultant, Bangalore West Lions Superspeciality Eye Hospital, Bangalore - 560002.

E-mail: fouqiah@yahoo.com

DOI: 10.18410/jebmh/2017/584



The treatment of glaucoma is targeted at lowering the IOP as it is currently the only modifiable risk factor.^{4,5} This is done either by decreasing the formation of aqueous humour or by increasing its outflow as in the case of filtration surgery.

Trabeculectomy is a filtering surgery where an ostium is created into the anterior chamber allowing aqueous to flow into the subconjunctival space leading to the formation of a filtering bleb. The aqueous humour in the subconjunctival space may then exit by multiple pathways including transconjunctival filtration and absorption through the episcleral veins.

The primary factor for the success of trabeculectomy is that the filtering bleb becomes functional and remains as such, thereby maintaining the desired intraocular pressure leading to long-term success of the surgery. Bleb function depends on the degree of fibrosis and obstruction of intrascleral aqueous humour flow, thus examining the morphology of the filtering bleb is useful in evaluating its function.

Clinically, the bleb morphology is assessed using slit lamp biomicroscopy and MBGS. However, bleb evaluation merely based on slit-lamp examination has its own limitations as it is subjective. Moreover, the internal morphology of filtering blebs, which could play an important part in determining the surgical outcome cannot be evaluated under slit lamp. Anterior Segment Optical Coherence Tomography (AS-OCT) provides internal visualisation of the blebs.^{6,7,8}

A long-term study of the bleb post trabeculectomy is important because wound remodelling and fibrosis continues lifelong and can affect bleb filtration. Our aim is to study the functionality and morphology of filtering blebs 5 years post trabeculectomy with adjuvant Mitomycin C and to determine a possible relationship between the clinical and imaging parameters of the bleb.

MATERIALS AND METHODS

We employed a prospective cross-sectional study design. The study was carried out in the Glaucoma Outpatient Department of Bangalore West Lions Superspeciality Eye Hospital between June 2014 to June 2016. Our study population consisted of glaucoma patients who had undergone trabeculectomy with adjuvant MMC in our hospital presenting to the OPD for follow up, five years or more after surgery. Our study sample included 40 eyes of 30 consecutive patients who met the inclusion criteria. All the patients were operated by the same surgeon five or more years prior to the beginning of our study using the same technique (fornix based flap, 0.4 mg/mL of MMC applied to filtration area for two minutes used as adjuvant, scleral flap sutured with both fixed and releasable sutures. When combined with cataract surgery, phacoemulsification was done at another site).

A written informed consent was obtained from all selected patients after obtaining ethical clearance. The tenets of the Declaration of Helsinki were adhered to.

A detailed history was taken to determine relevant clinical data that is, clinical diagnosis, the age of the patient,

duration post-surgery and the use of additional topical or oral antiglaucoma medication.

The patient was then subjected to a detailed clinical examination.

The best corrected distant visual acuity was noted using Snellen's charts. A meticulous slit lamp evaluation was done to rule out any other cause for decreased vision. Based on slit lamp biomicroscopy, the bleb morphology was assessed and classified as flat, diffuse or cystic. The functional outcome was defined in terms of Intraocular Pressure (IOP) and was measured using Perkin's applanation tonometer and recorded in mmHg. We classified a bleb as successful if the postoperative IOP was maintained <21 mmHg or IOP reduction more than 25% of the preoperative value without medication or additional surgery. Use of antiglaucoma medication to achieve the target IOP defines the nature of success that is whether it is a complete or qualified success.

The fundus examination was done using 90D lens with slit lamp biomicroscope to study damage to the disc and retinal nerve fibre layer. A colour monophotograph of each bleb was first obtained in a standardised fashion with the eye looking inferiorly to display the largest area available of the superior conjunctiva using the canthal margins as the horizontal limits of the photograph. The viewing system and the illumination system were kept at 60 degrees with diffuse illumination and the magnification at 10. The photo was then compared with the standard photographs given in Moorfields bleb grading system.

Six Criteria were Assessed and Graded

1. Central area (1-5).
2. Maximal area (1-5).
3. Bleb height (1-4).
4. Vascularity was graded in 3 areas including the central bleb conjunctiva, peripheral conjunctiva and non-bleb conjunctiva. Vascularity in each area was assigned a score from 1 to 5.

AS-OCT (Cirrus; Carl Zeiss Meditec, Dublin, CA) was used to take images of the bleb using anterior segment 5 line raster. All of the images and measurements were performed by the same operator. The patients were asked to look down and the upper lid was gently elevated by a finger to expose the bleb as much as possible. Care was taken to avoid exerting any pressure on the globe or bleb. Orthogonal line scans (length, 10 mm) of several serial radial sections perpendicular to the limbus and several serial sections tangential to the limbus were performed over the bleb area. A single best image was selected and one measurement was taken for each parameter in the same image by the same operator. All of the bleb images were measured using built-in software analysis. The measurements obtained were in micrometres. Bleb structures were assessed in terms of quantitative parameters like bleb wall thickness, subconjunctival fluid space, suprascleral fluid space and bleb height.

Bleb wall reflectivity along with internal bleb reflectivity were analysed and classified as mild, moderate and high.

Data Analysis Method

Descriptive and inferential statistical analysis has been carried out in the present study. Results of continuous measurements are presented in mean \pm SD (range- min-max) and results on categorical measurements are presented in number (%). Significance is assessed at 5% level of significance.

The Pearson correlation coefficient was used to evaluate any correlation between two continuous variables. The contingency coefficient of correlation between the two categorical variables.

A two-tailed test (Chi-square test) was used to find the significance of study parameters on categorical scale between two or more groups and a p value of <0.05 was considered significant for measured variables.

P value of <0.05 was considered significant and <0.01 was considered strongly significant.

R value above 0.5 indicated good positive correlational significance and a value below -0.5 indicates good negative correlation.

Statistical software- Statistical analysis was carried out using SAS 9.2, SPSS 15.0,

Stata 10.1, MedCalc 9.0.1, Systat 12.0, R environment Ver. 2.11.1. Microsoft excel and word were used to generate graphs and tables.

RESULTS

The study included 40 eyes of 30 patients with post trabeculectomy duration of 5 years or more of which 60% of eyes belonged to male patients.

Most of the patients were in the age group of 60-70 years (mean age = 63.35 ± 10).

At the time of surgery, most patients were in the age group 50-60 years with the mean age of 54.8 ± 10.4 . The mean duration between trabeculectomy and inclusion in this study ranged from 5-15 years with a mean of 8.6 ± 3.3 years.

The preoperative IOP in the study population ranged from 26-50 mmHg with a mean of 40.5 ± 6.8 . The postoperative IOP at the time of study ranged from 8-20 mmHg with a mean of 11.8 ± 3.8 . The mean reduction in IOP post trabeculectomy at the time of study is $68.8 \pm 12.7\%$ (Figure 1).

On slit lamp examination, 47% of the total blebs were diffuse, 30% were cystic and 23% were flat. 50% of eyes of each subtype had IOP in the range of 10-15 mmHg, however, no significant association was seen at $p < 0.05$.

No statistically significant relation was seen between the demographic parameters, gender, age at the time of the study, age at surgery and postoperative duration with respect to postoperative IOP at the time of study and bleb type on biomicroscopy at $p < 0.05$.

77% of the study population were diagnosed as POAG and 23% were diagnosed as PACG. A postoperative IOP within 10-15 mmHg range was achieved in 50% of POAG and 40% of PACG, but no statistical significance was seen at $p < 0.05$.

The MBGS parameters were studied in relation to postoperative IOP at the time of study (Table 1). Among the eyes which achieved an IOP of <15 mmHg post trabeculectomy- 77.5% of them had a central diffusion area of $\geq 50\%$ and 60% eyes had a maximal diffusion area of $\geq 50\%$. 75% of eyes have a height of grade 2 or 3.75% had an avascular (grade 1) to mild vascularisation of the central zone (grade 2), 80% normal (grade 2) to moderately vascularised (grade 4) peripheral bleb conjunctiva and the non-bleb conjunctiva was normal (grade 2) or had mild vascularisation (grade 3) in 70% of blebs.

But, statistically no significant association was seen between the postoperative IOP at the time of study and the MBGS parameters diffusion area of the bleb, bleb height and vascularity at $p < 0.05$.

Comparison of Bleb Morphology on Slit Lamp in relation to Bleb grading by MBGS (Table 2)

Almost, all blebs (97.5% and 100%, respectively), irrespective of the type of bleb on slit lamp showed a central and maximal diffusion area of $\geq 50\%$ (grade 2 and above).

The diffuse blebs had a height of grade 2 -3, flat blebs were mostly of grade 1 -2 and most cystic blebs were grade 3 -4 according to MBGS. This shows a strong and statistically significant relation between bleb type on slit lamp and height according to MBGS at $p < 0.05$ ($p=0.001$).

Most blebs that appeared diffuse (89.5%) and flat (89%) on slit lamp had normal to mild central bleb vascularity (grade 2 and grade 3, respectively), while 58% of cystic blebs were found to be avascular (grade 1). The vascularity of peripheral and non-bleb conjunctiva in $>90\%$ of blebs were normal (grade 2) or mild (grade3) irrespective of the bleb type. We see statistically significant relation between bleb type on slit lamp and vascularity in the central zone of the bleb according to MBGS at $p < 0.05$ ($p=0.010$). But, no statistical significance between bleb type on slit lamp and diffusion area and vascularity of peripheral and non-bleb conjunctiva at $p=0.05$.

There is a statistically significant agreement between the bleb type on slit lamp examination and morphological classification based on AS-OCT at $p < 0.05$ ($p=0.000$). However, AS-OCT revealed cystoid appearance in two blebs that were biomicroscopically graded as diffuse. Also, five blebs that appeared flat on slit lamp were found to be diffuse on AS-OCT (Table 3).

Comparison of Slit Lamp appearance with AS-OCT parameters

Cystic blebs were found to have thin walls (mean= 25.5μ) with large hyporeflexive space (mean subconjunctival space= 91.17μ and suprascleral fluid space= 404.08μ). Flat blebs were found to have thicker (mean= 90.22μ) hyperreflective walls with fluid spaces (mean subconjunctival space= 29.89μ and suprascleral fluid space= 76.22μ) of less height. However, the walls of blebs that were classified as diffuse (mean= 62.16μ) were thicker when compared with cystic blebs, but relatively thinner than flat blebs and had low-to-moderate reflectivity.

Statistically, there is a significant agreement between bleb morphology on slit lamp and bleb wall thickness, subconjunctival fluid space height and bleb wall and total bleb reflectivity on AS-OCT at $p < 0.05$ ($p = 0.004$; $p = 0.003$; $p = 0.007$; $p = 0.000$, respectively).

Comparison of Bleb Height on AS-OCT and Height According To MBGS (Figure 3)

More than 50% of the blebs graded as grade 2 and grade 3 according to MBGS were found to have total bleb height between 80-300 μ and 300-520 μ , respectively. Statistically, there is a significant association between height according to MBGS and total height of the bleb on AS-OCT at $p < 0.05$ ($p = 0.050$).

Comparison of Bleb Vascularity (MBGS) With Bleb Wall Reflectivity on AS-OCT

On comparing the vascularity of the blebs with bleb wall reflectivity, no significant association was seen at $p < 0.05$ ($p = 0.718$).

Postoperative IOP Correlated with AS-OCT parameters

Postoperative IOP at the time of study correlates negatively with total bleb height (Figure 4) and was found to be statistically significant at $p < 0.05$. ($r = -0.3592$; $p = 0.022909$).

There is no statistical significant correlation between IOP at the time of study and bleb wall thickness (figure 5) at $p < 0.05$ ($R = 0.0722$; $P = 0.65796$).

There was a negative correlation between post trabeculectomy IOP and subconjunctival fluid space height (figure 6), but was not statistically significant at $p < 0.05$ ($R = -0.2601$, $P = 0.10518$).

IOP at the time of study correlates negatively with suprascleral fluid space (figure 7), but statistically, no significance was seen at $p < 0.05$ ($R = -0.2803$, $P = 0.080133$).

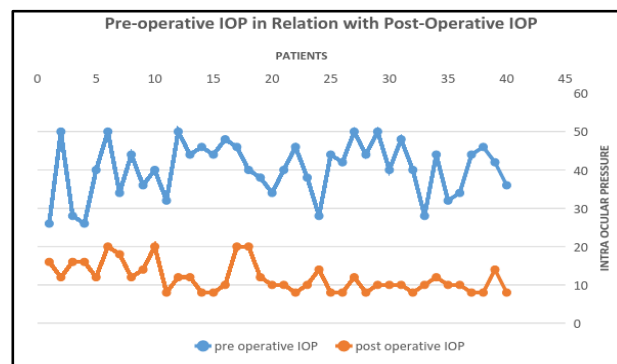


Figure 1. Scatter Plot Showing Preoperative IOP in Relation with Postoperative IOP

IOP	DIFFUSION AREA								HEIGHT				VASCULARITY											
	CENTRAL				MAXIMAL								CENTRAL				PERIPHERAL				NON BLEB CONJUNCTIVAL			
	1	2	3	4	1	2	3	4	1	2	3	4	1	2	3	4	1	2	3	4	1	2	3	4
5-10	0	3	4	4	0	1	3	4	0	5	4	2	5	3	3	0	0	5	4	4	0	8	3	0
10-15	1	10	4	6	0	6	5	5	2	11	8	0	2	11	6	2	3	7	8	3	2	15	2	2
15-20	0	1	2	1	0	1	6	9	1	3	0	0	0	1	2	1	0	1	3	0	0	1	3	0
20-25	0	1	3	0	0	1	2	1	0	1	3	0	1	1	2	0	0	2	2	0	0	3	1	0

Table 1. Moorfields Bleb Grading System in Relation to Post Trabeculectomy IOP

BLEB TYPE	DIFFUSION AREA								HEIGHT				VASCULARITY											
	CENTRAL				PERIPHERAL								CENTRAL				PERIPHERAL				NON BLEB CONJUNCTIVA			
	1	2	3	4	1	2	3	4	1	2	3	4	1	2	3	4	1	2	3	4	1	2	3	4
DIFFUSE	0	6	8	5	0	3	5	11	0	13	6	0	1	9	8	1	1	7	8	3	1	12	4	2
FLAT	1	4	3	1	0	4	3	2	3	5	1	0	0	5	3	1	0	3	5	1	0	5	4	0
CYSTIC	0	5	2	5	0	2	5	5	0	2	8	2	7	2	2	1	2	5	4	1	1	10	1	0

Table 2. Comparison of Bleb Morphology on Slit Lamp with Moorfields Bleb Grading System

	AS-OCT			Bleb Morphology
	Cystic	Flat	Diffuse	
	2 (5.0%)	1 (2.5%)	16 (40%)	diffuse
	0 (0%)	4 (10.0%)	5 (12.5%)	Flat
	11 (27.5%)	0 (0%)	1 (2.5%)	cystic

Table 3. Correlation of Types of Blebs on Slit Lamp and AS-OCT

BLEB TYPE	BLEB WALL THICKNESS		SUBCONJUNCTIVAL FLUID SPACE		SUPRASCLERAL FLUID SPACE		TOTAL BLEB HEIGHT		REFLECTIVITY
	MEAN	SD	MEAN	SD	MEAN	SD	MEAN	SD	
DIFFUSE	62.16	27.54	36.63	19.77	112.11	199.4	350.42	185.6	low -mod
FLAT	90.22	34.86	29.89	14.51	76.22	59.11	290.22	143.37	high
CYSTIC	25.5	16.41	91.17	61.87	404.08	318.48	679	306.21	low

Table 4. AS-OCT Parameters in Relation to Slit Lamp Appearance

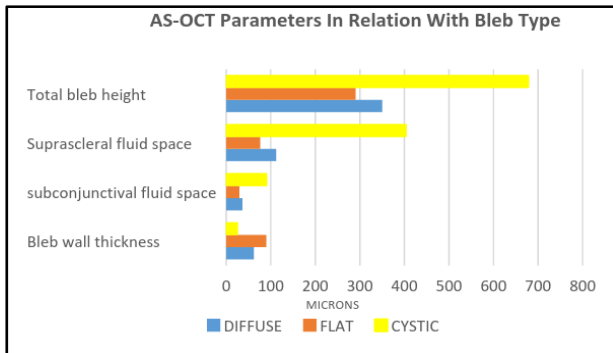


Figure 2. Bar Diagram Showing AS-OCT Parameters in Relation to Slit Lamp Appearance

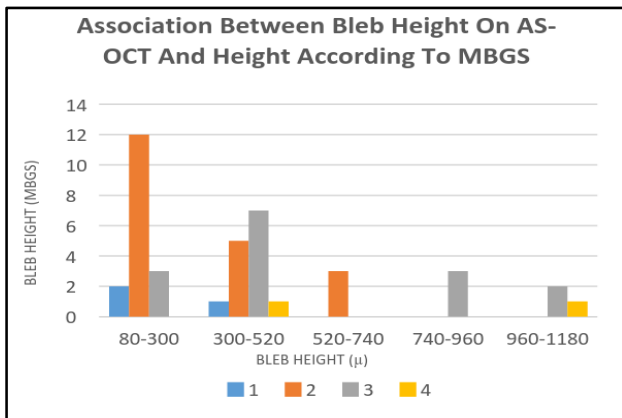


Figure 3. Clustered Column Graph Showing Association between Bleb Height on AS-OCT and Height According to MBGS

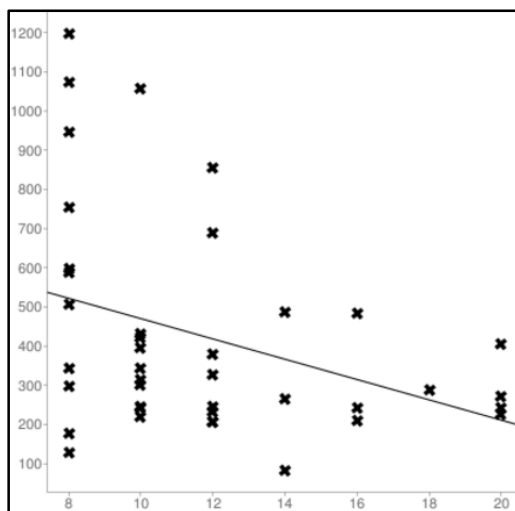


Figure 4. Linear Regression Graph Showing Correlation between Total Bleb Height and IOP at the Time of Study

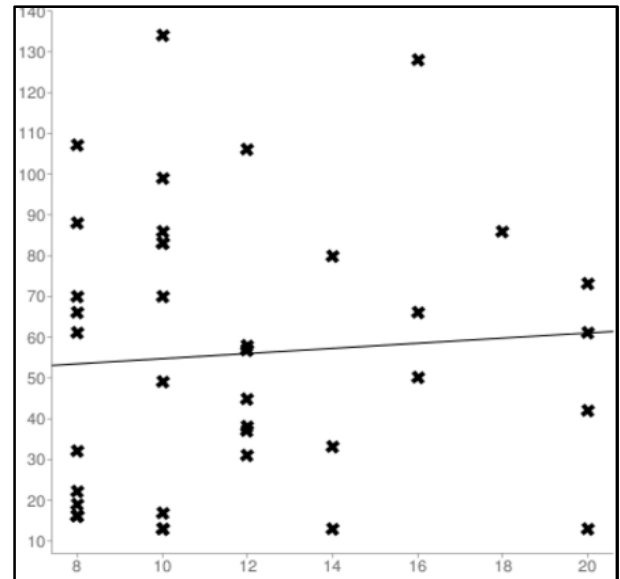


Figure 5. Linear Regression Graph Showing Correlation between Bleb Wall Thickness (AS-OCT) and IOP at the Time of Study

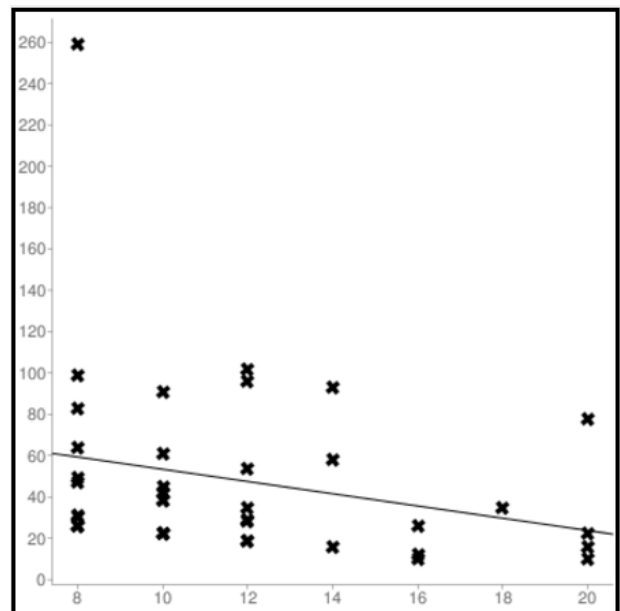


Figure 6. Linear Regression Plot Showing Correlation between Subconjunctival Fluid Space (AS-OCT) and IOP at the Time of Study

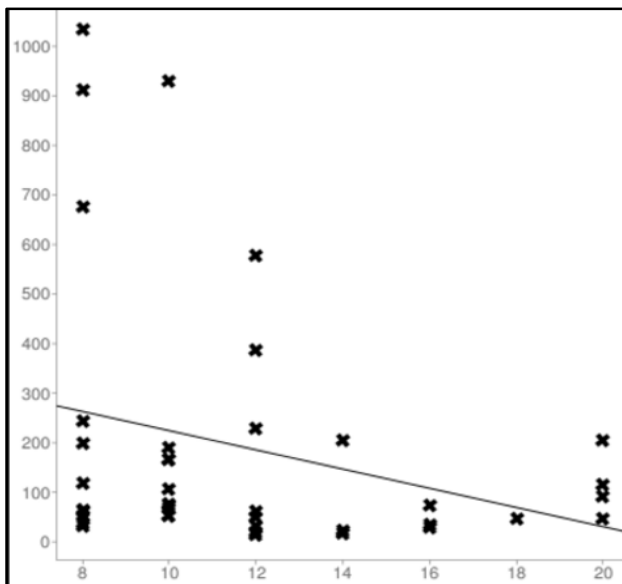


Figure 7. Linear Regression Plot Showing Correlation between Suprascleral Fluid Space and IOP at the Time of Study

Slit lamp photographs for Moorfields Bleb Grading System 1.

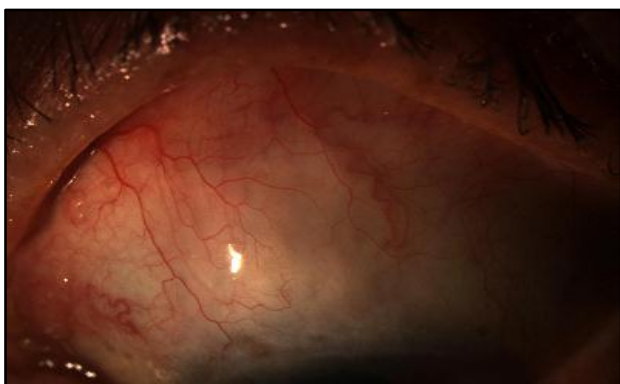

Figure 8. Classified as Flat on Slit Lamp

In comparison with the standard photographs in MBGS central diffusion area- grade 3, maximal diffusion area- grade 3, Height- grade 1, Vascularity - central grade 2, peripheral- grade 2, non-bleb conjunctiva- grade 3.

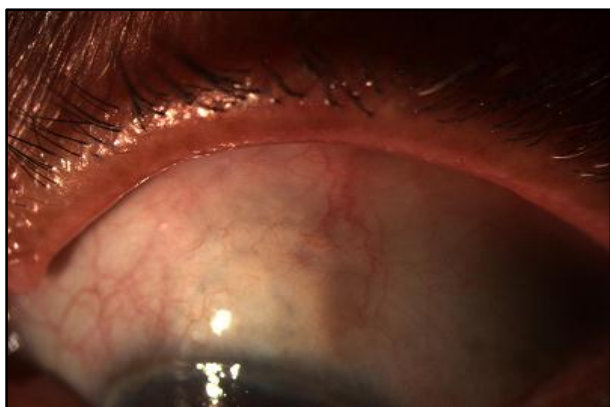

Figure 9. Classified as Cystic on Slit Lamp

In comparison with the standard photographs in MBGS, central diffusion area- grade 4, maximal diffusion area- grade 4, height- grade 2.

Vascularity: central- grade 2, peripheral- grade 2, non-bleb conjunctiva- grade 2.




Figure 10. AS-OCT Image of a Diffuse Bleb

A- Bleb wall thickness, B- Subconjunctival fluid space, C- Suprascleral fluid space, D- Total bleb height.

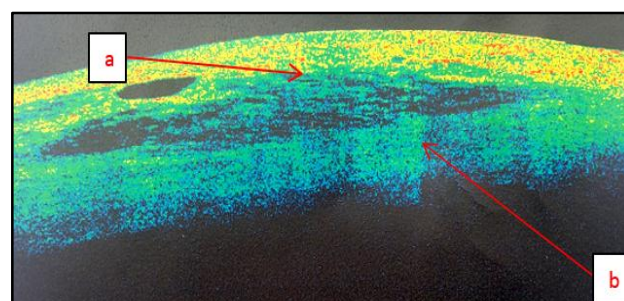


Figure 11. Coloured AS-OCT Image of Diffuse Bleb

A- Low reflectivity of bleb wall; B- Low reflectivity of bleb.

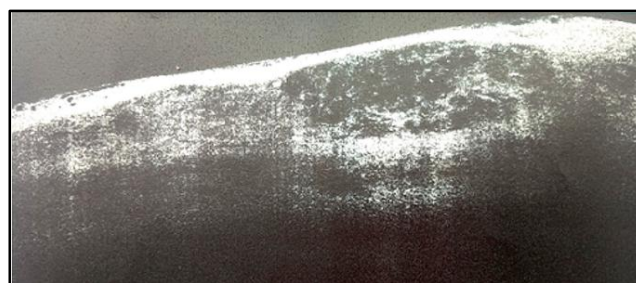


Figure 12. AS-OCT Image of a Cystic Bleb

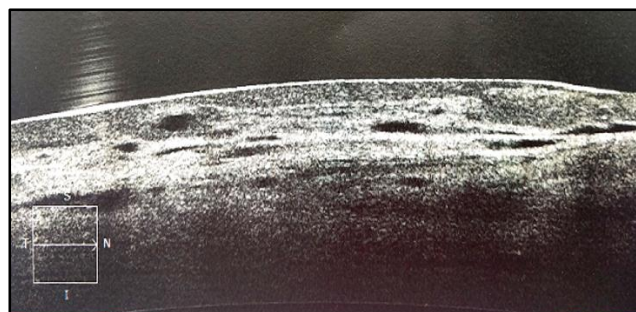


Figure 13. AS-OCT Image of a Low Lying Diffuse Bleb

DISCUSSION

This prospective cross sectional study was conducted in the glaucoma clinic of Bangalore West Lions Super Speciality Eye Hospital, a tertiary care centre from June 2014 to June 2016.

The aim was to study the functionality and morphology of filtering blebs 5 years post trabeculectomy with adjuvant MMC and to determine a possible relationship between the clinical and imaging parameters of the bleb.

Our study included 40 eyes of 30 patients. Most of the patients were in the age group of 60-70 years and 60% eyes belonged to male patients. At the time of Trabeculectomy, the age of the patients ranged from 33-71 years. The average postoperative duration was 8.6 ± 3.3 years.

Long-term follow-up of primary trabeculectomy without adjunctive MMC, has shown that despite successful control of IOP at 1 year, the probability of success decreases with time and stabilises at 67% by 10 years.⁹ Landers, et al¹⁰ reported a complete success in 60% and qualified success in 90% eyes that underwent trabeculectomy without MMC at the end of 20 years.

Chen¹¹ described the efficacy of MMC in enhancing bleb survival following trabeculectomy in eyes with a high risk of failure. Kitazawa et al¹² reported that 88% of glaucomatous eyes with poor surgical prognosis achieved an IOP of <20 mmHg without glaucoma medications with use of intraoperative MMC during trabeculectomy in a period of 7-12 months. Kitazawa Y, Suemori-Matsushita H et al¹³ in another study evaluated and found 100% success in eyes that underwent trabeculectomy with 0.2 mg/mL MMC. Similarly, we observed complete success in 90% of eyes and qualified success 100%.

Agarwal et al¹⁴ reported efficacy with MMC 0.4 mg/mL and 0.2 mg/mL applied for 4 mins in post-trabeculectomy patients. They also reported that avascular, thin, sharply demarcated blebs were noted in 33.3% and in 66.67% of eyes of patients treated with 0.02% and 0.04% MMC, respectively.

Guven Yilmaz et al¹⁵ determined that 64.7% of functional blebs were avascular and thin walled, in a study population that had undergone trabeculectomy with 0.2 mg/mL MMC applied for 4 mins.

Our study included patients who underwent trabeculectomy with 0.4 mg/mL intraoperative subconjunctival MMC for 2 mins. 30% of the blebs were found to be cystic. No bleb related complications were seen in the patients included in this study.

In our study, we defined complete success as IOP post trabeculectomy <21 mmHg without medication and qualified success as IOP post trabeculectomy <21mmHg with medication. As per this criterion, all the blebs were classified as successful, with approximately half the blebs being diffuse and the rest cystic (30%) and flat (23%). We did not find any relation between bleb type and post trabeculectomy IOP at the time of study at $p < 0.05$ ($p = 0.166$)

At the time of our cross-sectional study, we found no statistical significance between postoperative duration and postoperative IOP at the time of study or type of bleb ($p = 0.407$, $p = 0.967$, respectively). Being an observational

study we could not assess the effect of duration post-surgery on bleb macroscopic and microscopic characteristics.

We graded the filtering blebs using Moorfields Bleb Grading System, and found a very significant association between the bleb type on slit lamp and the height and central bleb vascularity according to MBGS grading ($p = 0.001$, $p = 0.010$). This was in contrast to the Crowston, et al¹⁶ study that found poor agreement between bleb height in MBGS and slit lamp morphology.

Smith et al¹⁷ reported that higher blebs in clinical evaluation of filtering blebs was significantly associated with low IOP, but there was no association between the vascularity or extension of bleb with post trabeculectomy IOP at the time of study. In our study, we compared the diffusion area, bleb height and vascularity according to MBGS with the post trabeculectomy IOP and no statistically significant association was seen.

AS-OCT is able to demonstrate features of bleb morphology that is not visible on slit lamp. Ciancaglini et al⁸ in a study that proposed a combined clinical and instrumental approach to evaluate the filtering bleb functionality found a good degree of concordance between the clinical and AS-OCT bleb classification particularly for diffuse and cystic patterns ($p < 0.001$). In our study also, we found a high degree of agreement between classification of type of bleb on slit lamp and AS-OCT ($p = 0.000$).

Cystic blebs in our study were found to have thin walls enclosing large hyporeflexive cystic spaces ranging up to 1000 μ . Flat blebs were seen to have thicker walls with high reflectivity and small fluid spaces. The walls of diffuse blebs were found to have low-to-moderate reflectivity. These findings were similar to those seen in the Leung et al¹⁸ study.

The Singh et al¹⁹ study found good agreement between bleb height on AS-OCT and MBGS. We also found a good association between bleb height on AS-OCT and MBGS. ($p = 0.050$).

We found a good association between bleb appearance on slit lamp and bleb wall reflectivity and also the internal bleb reflectivity similar to the Leung et al and the Singh et al¹⁹ study. Pfenninger et al²⁰ reported a significant direct correlation between the reflectivity of the fluid-filled cavity and IOP at the time of study. Leung et al¹⁸ found good IOP control in low reflective blebs. However, we did not find any correlation between either bleb wall or internal bleb reflectivity with post trabeculectomy IOP. This could be due to the very subjective nature of assessment of reflectivity on AS-OCT as AS-OCT does not provide signal intensity measurements.

The Leung et al¹⁸ demonstrated in their case series that the presence of suprascleral fluid space is not related to bleb function, which is similar to that seen in our study.

Fakhraie et al²¹ show a positive correlation between bleb height, bleb wall thickness and internal cavity height on AS-OCT and post trabeculectomy IOP. While Kawaji et al²² showed that bleb wall thickness, bleb height and fluid-filled cavity height on AS-OCT was negatively correlated with post trabeculectomy IOP. Tominaga et al⁷ showed that only bleb wall thickness correlates negatively with post

trabeculectomy IOP while bleb height on AS-OCT does not correlate with post trabeculectomy IOP. While Ciancaglini et al⁸ states bleb wall thickness at the thinnest point is not related to bleb functionality.

Our case series demonstrated a significant negative correlation between post trabeculectomy IOP and total bleb height on AS-OCT. No significant correlation was seen between post trabeculectomy IOP and bleb wall thickness or height of subconjunctival fluid space and suprascleral fluid space.

CONCLUSION

This case series with a long-term followup period showed that trabeculectomy augmented with MMC can achieve good long-term IOP control. The filtering bleb morphology using clinical methods (slit lamp biomicroscopy and Moorfields Bleb Grading System) and AS-OCT was found to be consistent therefore, indicating that clinical grading of bleb morphology is adequate and reliable in clinics in which imaging techniques are not available. In cases where IOP and bleb morphology do not correlate, AS-OCT is a useful tool to assess the internal bleb morphology and enhances our understanding of bleb functioning.

REFERENCES

- [1] Foster PJ, Buhrmann R, Quigley HA, et al. The definition and classification of glaucoma in prevalence surveys. *Br J Ophthalmol* 2002;86(2):238-242.
- [2] Tham YC, Li X, Wong TY, et al. Global prevalence of glaucoma and projections of glaucoma burden through 2040. A systematic review and meta-analysis. *Ophthalmology* 2014;121(11):2081-2090.
- [3] Ramakrishnan R, Nirmalan PK, Krishnadas R, et al. Glaucoma in a rural population of southern India: the Aravind comprehensive eye survey. *Ophthalmology* 2003;110(8):1484-1490.
- [4] Weinreb RN, Khaw PT. Primary open-angle glaucoma. *Lancet* 2004;363(9422):1711-1720.
- [5] Mansouri K. The road ahead to continuous 24-hour intraocular pressure monitoring in glaucoma. *J Ophthalmic Visi Res* 2014;9(2):260-268.
- [6] Singh M, Aung T, Friedman DS, et al. Anterior segment optical coherence tomography imaging of trabeculectomy blebs before and after laser suture lysis. *Am J Ophthalmol* 2007;143(5):873-875.
- [7] Tominaga A, Miki A, Yamazaki Y, et al. The assessment of the filtering bleb function with anterior segment optical coherence tomography. *J Glaucoma* 2010;19(8):551-555.
- [8] Ciancaglini M, Carpineto P, Agnifili L, et al. Filtering bleb functionality: a clinical, anterior segment optical coherence tomography and in vivo confocal microscopy study. *J Glaucoma* 2008;17(4):308-317.
- [9] Chen TC, Wilensky JT, Viana MA. Long-term follow-up of initially successful trabeculectomy. *Ophthalmology* 1997;104(7):1120-1125.
- [10] Landers J, Martin K, Sarkies N, et al. A twenty-year follow-up study of trabeculectomy: risk factors and outcomes. *Ophthalmology* 2012;119(4):694-702.
- [11] Chen CW. Enhanced intraocular pressure controlling effectiveness of trabeculectomy by local application of mitomycin-C. *Trans Asia-Pacific Acad Ophthalmol* 1983;9:172-176.
- [12] Kitazawa Y. Trabeculectomy with mitomycin. *Archives of Ophthalmology* 1991;109(12):1693.
- [13] Kitazawa Y, Suemori-Matsushita H, Yamamoto T, et al. Low-dose and high-dose mitomycin trabeculectomy as an initial surgery in primary open-angle glaucoma. *Ophthalmology* 1993;100(11):1624-1628.
- [14] Agarwal HC, Sood NN, Sihota R, et al. Mitomycin-C in congenital glaucoma. *Ophthalmic Surg Lasers* 1997;28(12):979-985.
- [15] Güven Yılmaz S, Değirmenci C, Palamar M, et al. Evaluation of filtering bleb function after trabeculectomy with mitomycin c using biomicroscopy, anterior segment optical coherence tomography and in vivo confocal microscopy. *Turk J Ophthalmol* 2015;45(4):132-137.
- [16] Crowston JG, Kirwan JF, Wells A, et al. Evaluating clinical signs in trabeculectomized eyes. *Eye (Lond)* 2004;18(3):299-303.
- [17] Smith M, Chipman ML, Trope GE, et al. Correlation between the Indiana bleb appearance grading scale and intraocular pressure after phacotrabeculectomy. *J Glaucoma* 2009;18(3):217-219.
- [18] Leung CK, Yick DW, Kwong YY, et al. Analysis of bleb morphology after trabeculectomy with Visante anterior segment optical coherence tomography. *Br J Ophthalmol* 2007;91(3):340-344.
- [19] Singh M, Chew PT, Friedman DS, et al. Imaging of trabeculectomy blebs using anterior segment optical coherence tomography. *Ophthalmol* 2007;114(1):47-53.
- [20] Pfenninger L, Schneider F, Funk J. Internal reflectivity of filtering blebs versus intraocular pressure in patients with recent trabeculectomy. *Invest Ophthalmol Visl Sci* 2011;52(5):2450-2455.
- [21] Fakhraie G, Kohansal S, Eslami Y, et al. Correlation between filtering bleb clinical morphology, anterior segment optical coherence tomography findings, and intraocular pressure. *Iranian Journal of Ophthalmology* 2011;23(4):21-28.
- [22] Kawaji T, Inoue T, Matsumuro R, et al. Trabeculectomy bleb assessment via three-dimensional anterior segment optical coherence tomography. *JSM Ophthalmol* 2014;2(2):1020.