

## A CLINICAL STUDY ON FUNCTIONAL OUTCOME AFTER COMBINED ARTHROSCOPIC AND FLUOROSCOPIC ASSISTED REDUCTION AND INTERNAL FIXATION OF CLOSED TIBIAL PLATEAU FRACTURES IN ADULTS

T. Bhavani Prasad<sup>1</sup>, B. Sasibushan Reddy<sup>2</sup>, Sandeep Saraf<sup>3</sup>, K. Harish<sup>4</sup>, T. Dinesh Kumar<sup>5</sup>

### HOW TO CITE THIS ARTICLE:

T. Bhavani Prasad, B. Sasibushan Reddy, Sandeep Saraf, K. Harish, T. Dinesh Kumar. "A Clinical Study on Functional Outcome after Combined Arthroscopic and Fluoroscopic Assisted Reduction and Internal Fixation of Closed Tibial Plateau Fractures in Adults". *Journal of Evidence based Medicine and Healthcare*; Volume 2, Issue 24, June 15, 2015; Page: 3623-3631.

**ABSTRACT: BACKGROUND AND INTRODUCTION:** Management of tibial plateau fractures had witnessed tremendous improvement in surgical techniques over the past decades. Conservative treatment of these fractures results in consistently poor results. The present literature supports that absolute anatomical reduction and stable fixation of peri articular fractures followed by early post-operative rehabilitation is crucial for good results. And if this is achieved by minimal damage to soft tissue the results are much better. In this study it is achieved by arthroscopy and fluoroscopy. **MATERIALS AND METHODS:** We have conducted a prospective study between September 2009 to August 2013 including 9 patients with tibial plateau fractures treated with combined arthroscopic and fluoroscopic reduction and internal fixation with or without bone grafting. And then the radiographic and functional evaluation done.

**RESULTS:** According to Hohl's clinical and radiographic scoring systems 4 patients were assessed excellent, 3 good, 2 fair. According to Rasmussen's clinical scoring system 4 patients excellent, 3 good and 2 fair results. **CONCLUSION:** The use of arthroscopy and fluoroscopy in the management of tibial plateau fractures results in good outcome. It also helped to simultaneously treat the meniscal injuries. But its use is mainly limited to Shatzkar type 1, 2, 3, 4.

**KEYWORDS:** Arthroscopic Guides, Fluoroscopic Guides, Tibial plateau fractures.

**INTRODUCTION:** Fractures of the tibial plateau represent 1% of all fractures and 8% of fractures in the elderly population. These fractures are a real surgical challenge to an orthopedic surgeon because of the complexity of fracture patterns and the associated soft-tissue injuries. If not adequately treated, these fractures often become complicated by arthritis, stiffness and angular deformity.<sup>(1)</sup>

In any case the goals of treatment are restoration of normal alignment, joint congruity, joint stabilization and ultimately the prevention of degenerative osteoarthritis.

The traditional problem of open reduction and internal fixation with arthrotomy to visualize the articular congruity are associated with high incidence of soft tissue problems and knee stiffness and delay in post-operative recovery.<sup>(2)</sup> So by achieving reduction through fluoroscopy and arthroscopy these problems due to open reduction can be minimized.

Additional advantages (1) include.

1. Better visualization of the articular surfaces,
2. Better reduction of the fracture,

# ORIGINAL ARTICLE

---

3. Better anatomical restoration of the joint surface.
4. The possibility to assess and treat the associated Intra-articular ligamentous and meniscal injuries,
5. The possibility through joint lavage, to remove loose Fragments,
6. The possibility to achieve stable fixation with the least amount of soft-tissues dissection,
7. Low risk of complications and low morbidity,
8. The possibility of converting to arthrotomy If necessary,
9. Shorter hospital stays with faster recovery of Joint motion.

A precise anatomical reduction and stable fixation and early immobilization are the goal. The present prospective study is mainly intended to study the results of tibial plateau fractures managed with the help of arthroscopy and fluoroscopy. In this study we mainly evaluate the radiographic and functional outcome.

**MATERIALS AND METHODS:** We have conducted a prospective study between September 2009 to august 2013 including 9 patients with tibial plateau fractures treated with combined arthroscopic and fluoroscopic reduction and internal fixation with or without bone grafting.

**Inclusion criteria:**

1. Pts between 18 to 65 yrs of age.
2. Pts. with Shatzkar type I, II, III, IV tibial Plateau fractures.
3. Pts. Presented within three weeks of injury.

**Exclusion criteria:**

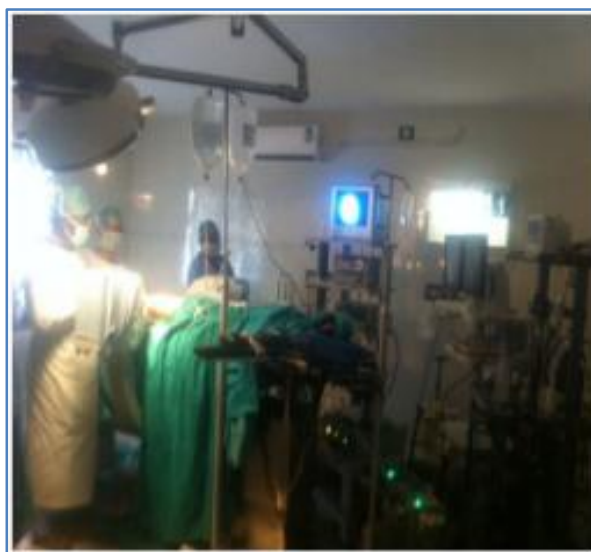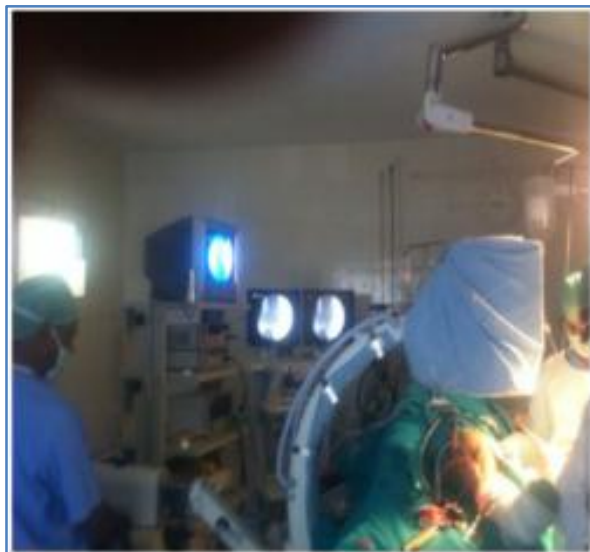1. Pt with Shatzkar type V, VI fractures.
2. Pts with complications like compartment Syndrome and neurovascular deficits.
3. Compound fractures.

**SURGICAL PROCEDURE:** During surgery diagnostic arthroscopy done initially using standard antero lateral and antero medial portals to visualize the articular surface and exact location of depression. In some case additional postero medial and postero lateral portals are needed. Blood clots are washed out but irrigation is kept as lower as possible to avoid the well-known complication of compartment syndrome associated with arthroscopy in case of intra articular fractures.

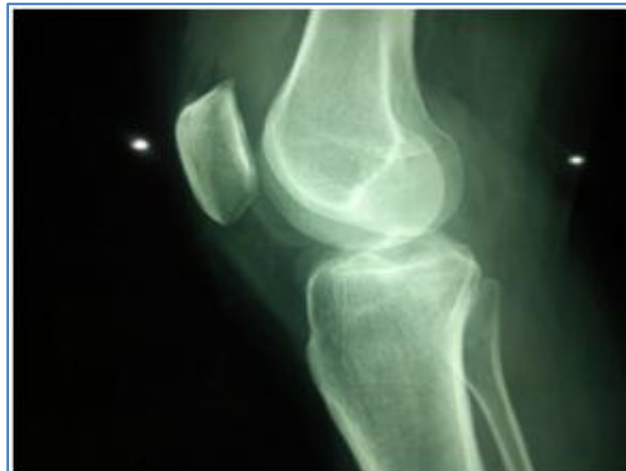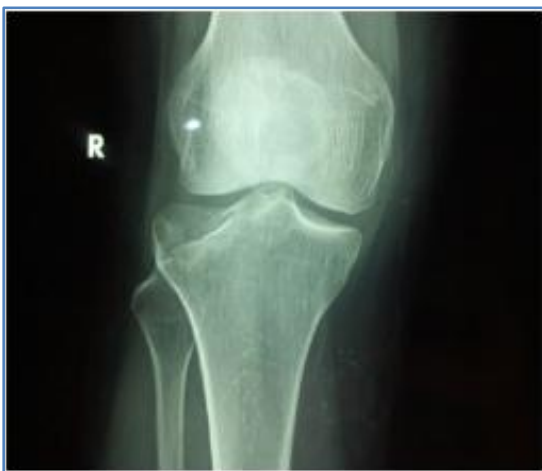# ORIGINAL ARTICLE

---

**Theatre set up showing positions of fluoroscope and arthroscope:**

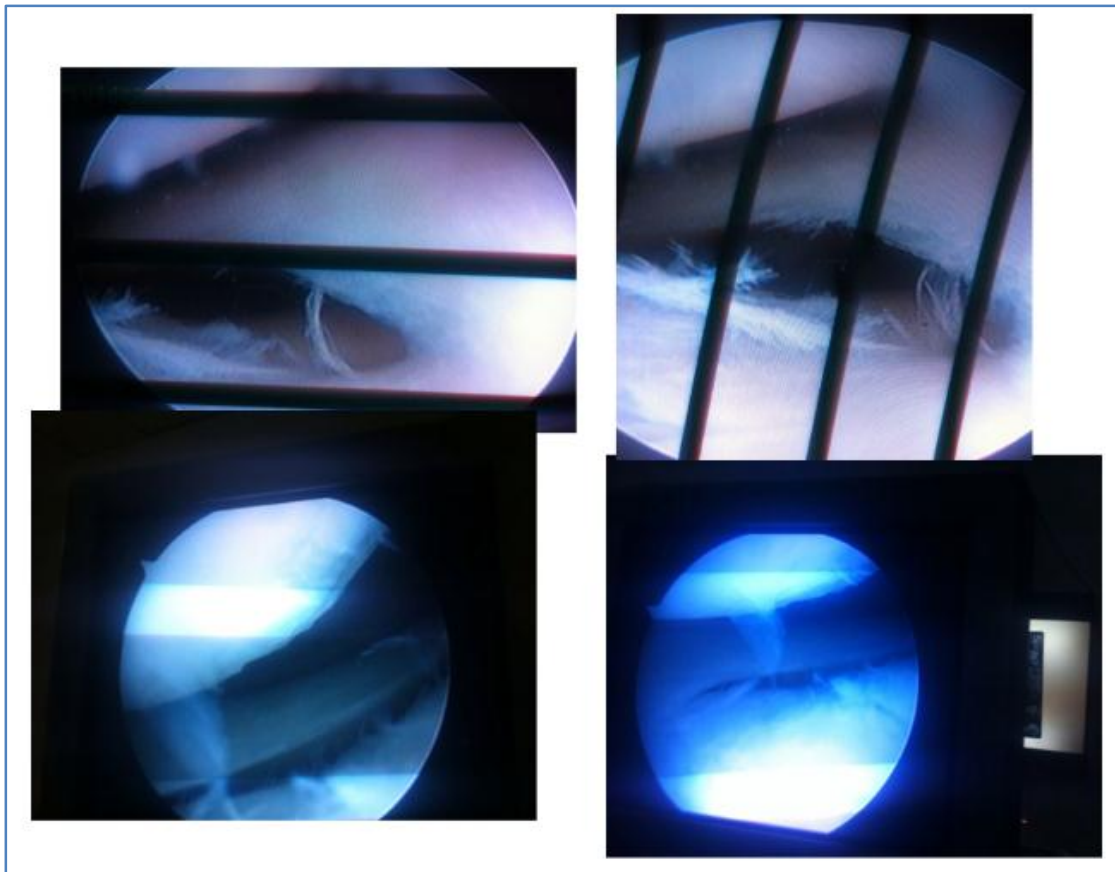


**Plain x-ray knee of a 55 yrs old female patient showing Shatzkar type 3 fracture with significant depression:**

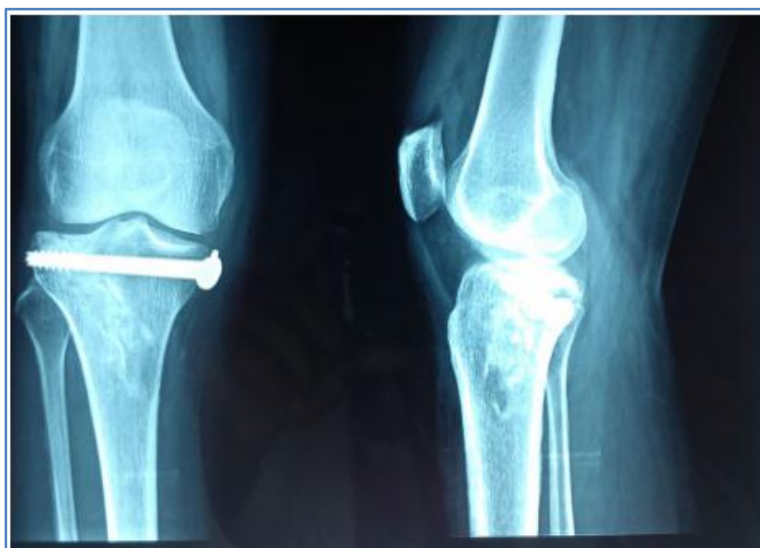

# ORIGINAL ARTICLE

**Arthroscopic pictures showing articular surface before and after reduction:**



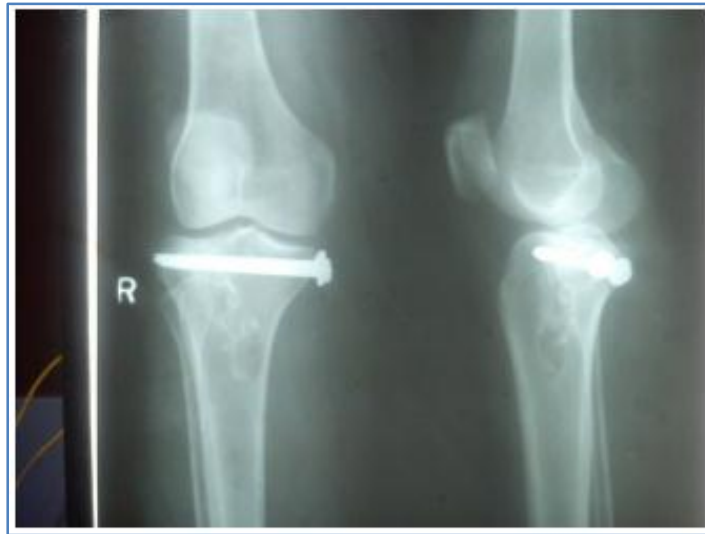**Immediate post op x-ray showing articular congruity and bone grafting:**



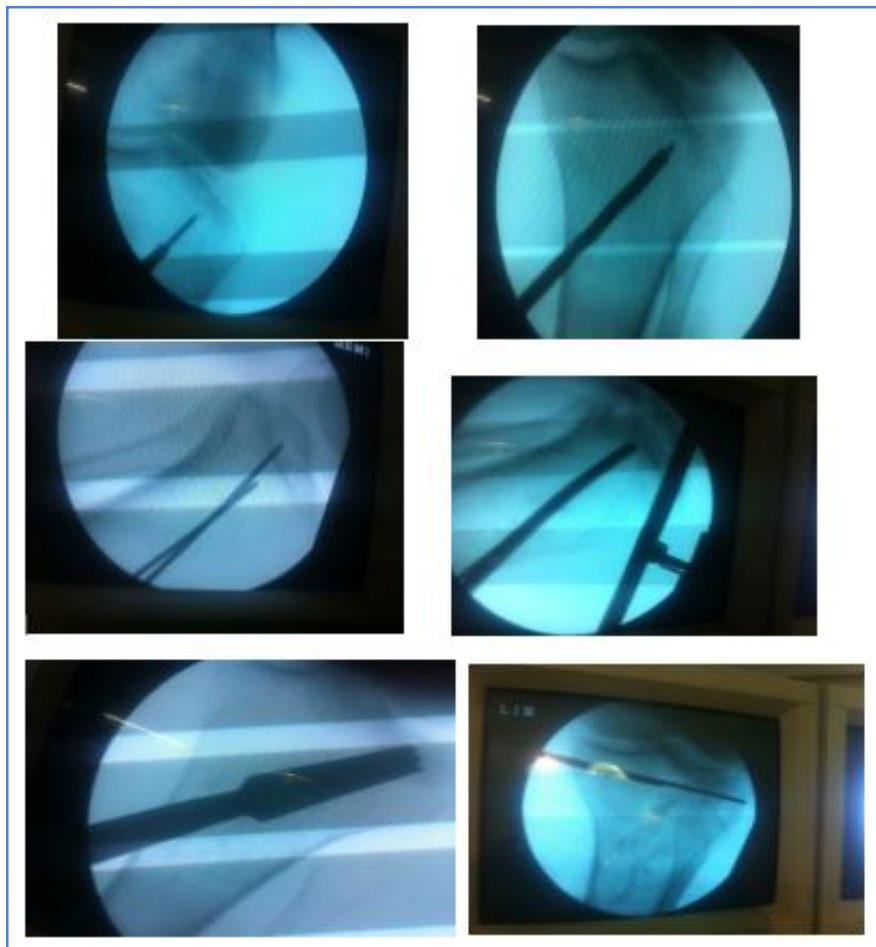
# ORIGINAL ARTICLE

---

**1 year post op X-ray of the same patient:**

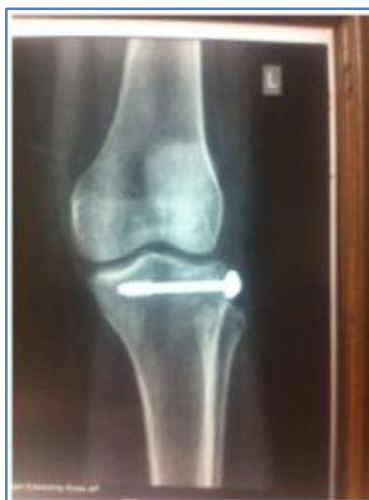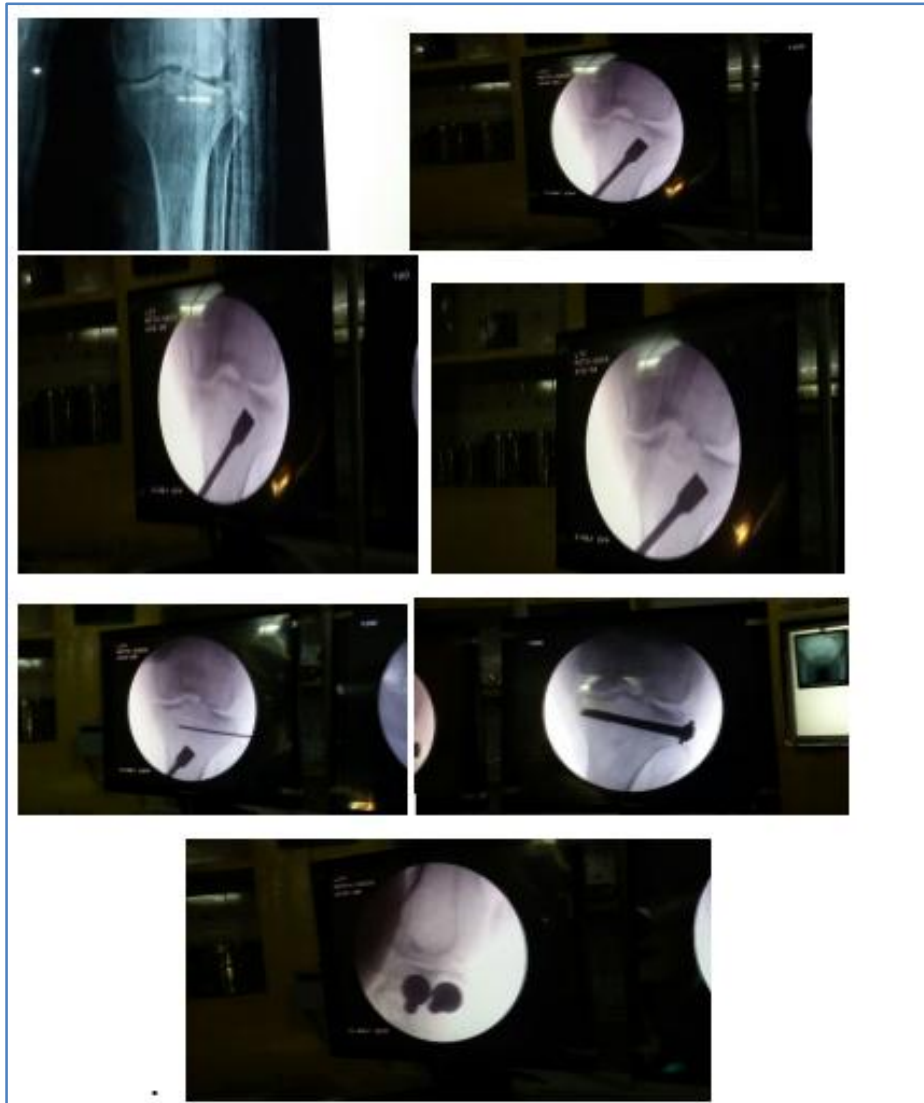


**Serial intra-operative pictures:**



# ORIGINAL ARTICLE

Another case pre-operative, intra operative and post-operative pictures:



# ORIGINAL ARTICLE

---

And associated meniscal injuries treated simultaneously.

The fracture pattern is studied quickly the exact location of articular depression localized. 1 to 2cm skin incision given on medial aspect of metaphyseal area to address lateral condyle fractures and on lateral aspect to address medial side fractures.

Cortical window is made after making pilot holes with 3.2 drill bit.

Then reduction done under fluoroscopic guidance with the help of a curved tamps to elevate the depression. Curved tamp allows to reach the wider area of sub-chondral area without widening the cortical window. Bone grafting is done as required and fixation done using 6.5 mm canulated cancellous screws over guide wires. Butress plating done in some cases through minimally invasive technique.

Standard Post-operative care is given. Radiographs are obtained immediate post op and 1<sup>st</sup>, 2<sup>nd</sup>, 3<sup>rd</sup>, 6<sup>th</sup> month and during subsequent visits.

During follow ups pts are assessed regarding knee pain, range of movements, instability. All the patients were assessed clinically and radiographically using Hohl's and Rasmussen's scoring system and osteoarthritis evaluated through scale of Ahlback.

**RESULTS:** According to Hohl's clinical and radiographic scoring systems 4 patients were assessed excellent, 3 good, 2 fair.

According to Rasmussen's clinical scoring system 4 patients excellent, 3 good and 2 fair results.

According to Ahlback scoring system one patient showed a moderate degree of OA. 2 patients mild OA.

All patients showed excellent ROM.

7 Patients were subjectively very satisfied. One patient mildly satisfied one not satisfied.

No patient had severe complications like compartment syndrome or DVT.

One patient had tourniquet palsy which recovered after 6 weeks.

**DISCUSSION:** Tibial plateau fractures have always been a challenge for orthopaedic surgeons. The goal of treatment is to restore anatomical reduction and to give a stable.<sup>(2,3)</sup> Fixation to the fracture fragments in order to begin early mobilization.

This is further facilitated if soft tissue damage can be kept to a minimal degree.<sup>(1)</sup>

Open reduction and internal fixation have a high incidence of soft tissue problems while plaster cast immobilization produces higher joint stiffness and deep venous thrombosis rate.

Fowble compared arthroscopic treatment to open reduction and internal fixation. He reported better results in terms of hospital stay, time to full weight bearing and anatomical reduction of the joint surface in patients who underwent arthroscopic treatment Fowble & Ohdera in a similar study concluded that there were no significant differences between both treatments in terms of duration of surgery, postoperative flexion and clinical results.

On the other hand, he demonstrated an easier and faster postoperative rehabilitation and the possibility to diagnose and treat any associated joint pathology With the assistance of arthroscopy the articular surface can be seen better without meniscal detachment. And intra-articular lesions can be diagnosed and eventually treated.<sup>(4)</sup>

# ORIGINAL ARTICLE

---

In our study associated intra-articular ligamentous and medical injuries were found in 3(33.33%) patients. Lateral meniscus was more susceptible to trauma.

As demonstrated by Walker and Erkman, the lateral meniscus is the most important structure in the transmission of forces across the lateral compartment, but both menisci are crucial for the maintenance of a normal joint function.

Gill et al described 29 tibial plateau fractures in skiers treated with ARIF. The mean Rasmussen score was 27.5 (range, 21 to 30). The author concluded that ARIF offers the advantage of improved visualization evaluation of hemarthrosis and chondral debris, decreased morbidity, shorter hospital stay and the ability to reliably diagnose and treat associated intra articular injuries.<sup>(1,5,6)</sup>

For this reason the treatment of associated lesions of the meniscus is important and should be repaired or partially removed if indicated

**CONCLUSION:** Combined arthroscopic and fluoroscopic assisted reduction and internal fixation of tibial plateau fractures is an effective and safe procedure for selected Shatzkar type I, II, III, IV fractures.

## REFERENCES:

1. James H. Lubowitz, M. D., Wylie S. Elson, M.D., Arthroscopic management of tibial plateau fractures.
2. Hung SS, Chao EK, Chan YS, et al. Arthroscopically assisted osteosynthesis for tibial plateau fractures. *J Trauma* 2003; 54 (2): 356-63.
3. Buchko GM, Johnson DH. Arthroscopy assisted operative management of tibial plateau fractures. *Clin Orthop* 1996; (332): 29-36. Review. 114 F. Pogliacomi, M.A. Verdano, M. Frattini, et al.
4. Blokker CP, Robrabeck CH, Bourne RP. Tibial plateau fractures and analysis of treatment in 60 patients. *Clin Orthop* 1984; 182: 193-9.
5. Mallik AR, Covall DJ, Whitelaw GP. Internal versus external fixation of bicondylar tibial plateau fractures. *Orthop Rev* 1992; 21: 1433-6.
6. Kankate RK, Singh P, Elliott DS. Percutaneous plating of low energy unstable fractures.



# ORIGINAL ARTICLE

---

**AUTHORS:**

1. T. Bhavani Prasad
2. B. Sasibushan Reddy
3. Sandeep Saraf
4. K. Harish
5. T. Dinesh Kumar

**PARTICULARS OF CONTRIBUTORS:**

1. Associate Professor, Department of Orthopaedics, Andhra Medical College, Visakhapatnam.
2. Post Graduate, Department of Orthopaedics, Andhra Medical College, Visakhapatnam.
3. Post Graduate, Department of Orthopaedics, Andhra Medical College, Visakhapatnam.

4. Post Graduate, Department of Orthopaedics, Andhra Medical College, Visakhapatnam.
5. Post Graduate, Department of Orthopaedics, Andhra Medical College, Visakhapatnam.

**NAME ADDRESS EMAIL ID OF THE CORRESPONDING AUTHOR:**

Dr. B. Sasibushan Reddy,  
Room No. 62,  
PG Men's Hostel,  
King George Hospital,  
Visakhapatnam.  
E-mail: reddy8731@gmail.com

Date of Submission: 26/05/2015.  
Date of Peer Review: 27/05/2015.  
Date of Acceptance: 01/06/2015.  
Date of Publishing: 13/06/2015.