

A CLINICAL STUDY OF VISUAL OUTCOME AND IOP CHANGES FOLLOWING YAG-CAPSULOTOMY IN POSTOPERATIVE CATARACT PATIENTS

Satyavathi Devi Pinipe¹, Shyam Savith Varanas²

¹Assistant Professor, Department of Ophthalmology, Rangaraya Medical College, Kakinada.

²Assistant Professor, Department of Ophthalmology, Rangaraya Medical College, Kakinada.

ABSTRACT

BACKGROUND

Neodymium-doped Yttrium Aluminium Garnet (Nd:YAG) laser is a solid state laser in which Nd:YAG is used as a laser medium. Nd:YAG laser posterior capsulotomy introduced a technique for closed eye, effective and relatively safe opening of the opacified posterior capsule and laser capsulotomy rapidly became the standard of care.

The aim of the study is to study the visual outcome following Nd:YAG laser capsulotomy for posterior capsular opacification.

MATERIALS AND METHODS

This is a prospective study of 100 patients conducted in the Department of Ophthalmology, Government General Hospital, Kakinada, over a period of 2 years.

RESULTS

The observations from the study were analysed and compared with the existing studies in the literature.

CONCLUSION

Nd:YAG laser capsulotomy is safest and excellent procedure for restoring vision provided the vision loss is only due to posterior capsular opacification.

KEYWORDS

Capsular Opacification, Capsulotomy, YAG Laser, Intraocular Pressure.

HOW TO CITE THIS ARTICLE: Pinipe SD, Varanasi SS. A clinical study of visual outcome and IOP changes following YAG-capsulotomy in postoperative cataract patients. *J. Evid. Based Med. Healthc.* 2017; 4(94), 5858-5861. DOI: 10.18410/jebmh/2017/1179

BACKGROUND

Nd:YAG capsulotomy is a special laser treatment used to improve the vision after cataract surgery followed by posterior capsule opacification. PCO is a common long-term complication of cataract surgery occurs about 2 years after surgery in 50% of the patients that causes decreased vision, glare and other symptoms similar to that of the original cataract. Posterior Capsular Opacification (PCO) remains one of the most common postoperative morbidities in modern day cataract surgery and Nd:YAG posterior capsulotomy is one of the most commonly performed surgical procedures.¹

Posterior capsule opacification is the most common delayed complication of cataract surgery. The incidence of PCO was reported to be 20.7% at 2 years and 28.5% at 5 years after cataract surgery.²

PCO is an extremely common development in patients after cataract extraction, and in many cases, it may not be immediately obvious, whether it is visually significant.

Financial or Other, Competing Interest: None.

Submission 06-12-2017, Peer Review 10-12-2017,

Acceptance 14-12-2017, Published 16-12-2017.

Corresponding Author:

Dr. Shyam Savith Varanasi,

Assistant Professor, Department of Ophthalmology,

Rangaraya Medical College, Kakinada-533001,

EG District, Andhra Pradesh.

E-mail: savithshyam@gmail.com

DOI: 10.18410/jebmh/2017/1179

Patients may have reduced vision from other undetermined causes or have some measures of visual function that are not reduced at all.³ YAG laser capsulotomy is the only way to treat this. Apart from affecting the vision, the thickening does not damage the eye in anyway. The patient complains of decreased visual acuity, glare and sensitivity to light. The YAG laser posterior capsulotomy has become standard treatment for this anomaly- an opening is created in the opacified posterior capsule, which immediately improves visual acuity.⁴

Since the use of Nd:YAG laser for posterior capsulotomy, the procedure has been gradually replacing the surgical capsulotomy as it is less invasive and can be performed as an outpatient procedure. Nd:YAG laser capsulotomy showed itself to be an effective alternative to surgical dissection avoiding such complications as endophthalmitis and vitreous loss.⁵

Hence, in the present study, effort is made to study the visual outcome, IOP changes and complications following Nd:YAG laser capsulotomy.

Aims and Objectives of the Study

1. The aim is to study the visual outcome and analyse the clinical results of Nd:YAG laser posterior capsulotomy in terms of efficacy, safety and complications in 100 eyes with posterior capsule opacification after small incision



cataract surgery and phacoemulsification with PCIOL (posterior chamber intraocular lens) implantation.

- To study the Intraocular Pressure (IOP) changes following Nd:YAG laser posterior capsulotomy.
- To study the intra and postoperative complications of Nd:YAG laser capsulotomy.

MATERIALS AND METHODS

This was a hospital-based prospective study in the Department of Ophthalmology, Government General Hospital, Kakinada, during the period of December 2014-August 2016.

The study included a total of 100 eyes of 100 patients who fulfilled the inclusion and exclusion criteria. Once diagnosed to have posterior capsular opacification, they were subjected to a detailed clinical examination. All patients underwent Nd:YAG laser capsulotomy. Patients were followed up at 1 hour, 4 hours, 1 day, 1 week, 1 month and 3 months.

Inclusion Criteria-

- Evidence of posterior capsular thickening/opacification on examination with slit-lamp.
- Postop cataract surgery, decrease in vision by at least 3 lines on Snellen’s chart.
- At least 3 months interval between cataract surgery and development of posterior capsular opacification.

Exclusion Criteria-

- Patients <5 years of age.
- Eyes with subluxated intraocular lens.
- Cases with postoperative complications like endophthalmitis.
- Uncooperative patients, e.g. patient with mental retardation, neurological problems.
- Posterior capsular opacification in aphakic eyes.

Post Laser Follow-Up

Intraocular pressure is recorded every 1 hour and 4 hours after capsulotomy and the patient is sent home to come for follow up after 1 week, 1 month, 3 months and 6 months. The patient is given the following treatment.

- Topical timolol maleate 0.5% b.i.d. for 1 week.
- Topical antibiotic and steroid eye drops 1 q.i.d. for 1 week.
- Oral acetazolamide tablets 250 mg q.i.d. for 5 days only when IOP is not controlled with above medication.

OBSERVATION AND RESULTS

After a short-term study of 6 months, the following observations were made. Cases were divided according to age/sex wise and also according to duration between cataract extraction and development of posterior capsular opacification.

Sex Distribution- Out of 100 patients in the study group, 52 are males and 48 are females. It was observed that the incidence of posterior capsule opacification is more in males.

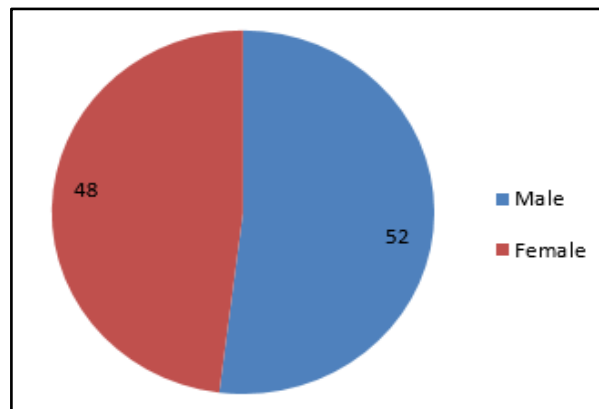


Figure 1. Showing Sex Distribution

Age Distribution

An attempt was also made to see age of the patient and duration between cataract extraction and development of posterior capsular opacification.

Sl. No.	Age in Years	Number of Cases	Average Duration between Surgery and PCO in Months
1.	1-10	0	-
2.	11-20	0	-
3.	21-40	9	12 months
4.	41-60	48	24 months
5.	>60	40	20 months

Table 1. Age Distribution

The main aim was to look for age group in which posterior capsule opacification occurs earlier. It has been shown that in patients under 40 years of age, the posterior capsule opacification was early, i.e. before 1 year. So, it can be stated that younger the age, earlier will be the posterior capsular opacification.

Duration between Cataract Extraction and Development of PCO

From this, it can be found that posterior capsule opacification occurs within 3 years in about 68% of cases within first year.

Duration in Months	Number of Eyes	Percentage
1-4 months	23	23%
5-8 months	20	20%
9-12 months	25	25%
12-36 months	22	22%
36-60 months	10	10%
Total 100 eyes		

Table 2. Showing Duration between Cataract Surgery and Development of PCO

Grading of Posterior Capsular Opacity

Posterior capsule opacification has been graded as mild, moderate and severe depending on slit-lamp examination and upon the visibility of fundus by direct and indirect ophthalmoscopy as follows.

Mild	Fundus seen with direct ophthalmoscope	24
Moderate	Fundus seen with indirect ophthalmoscope	52
Severe	No fundus view or details hazily seen	24

Table 3. Showing Grading of Posterior Capsular Opacity

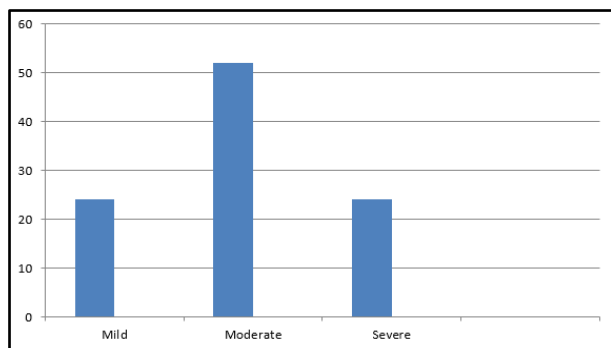


Figure 2. Showing Grading of Posterior Capsular Opacity

Complications of YAG Capsulotomy- Cases were examined within 4 hours and 24 hours for complications of Nd:YAG capsulotomy. Total number of eyes examined were 100 and results were analysed and it was observed that raised intraocular pressure is the commonest complication followed by YAG capsulotomy.

Sl. No.	Complication	Number of Eyes	Percentage
1.	Vitritis	8	8%
2.	Rise in intraocular pressure (transient)	40	40%
3.	Pitting of intraocular lens	6	6%
4.	Hyphema	4	4%
5.	Iritis	32	32%

Table 4. Showing Complications of YAG Capsulotomy

Pre-Laser VA	Post Laser Visual Acuity							Lost Follow-up
	6/6	6/9	6/12	6/18	6/24	6/36	6/60	
HM - CF5 Mts.	0	22	110	66	55	55	44	3
6/60 - 6/36	55	332	66	44	33	22	0	0
6/9 - 6/24	111	22	0	0	0	0	0	0

Table 6. Visual Improvement After Nd:YAG Laser Posterior Capsulotomy

Late Postoperative Complications- In the follow up period of 1 week, 4 weeks, 12 weeks and 24 weeks, cases were examined for complications like cystoid macular oedema, retinal detachment and chronic glaucoma.

None of the cases presented with cystoids macular oedema, retinal detachment and chronic open-angle glaucoma.

DISCUSSION

Posterior capsule opacity is a major complication of cataract surgery with or without intraocular lens implantation. The use of Nd:YAG laser has definitely simplified the treatment of posterior capsule opacification. Another great advantage is that is entirely non-invasive. The non-invasive technique of Nd:YAG laser has become popular for doing posterior capsulotomy and it has been established as a standard treatment for PCO replacing surgical capsulotomy.⁶

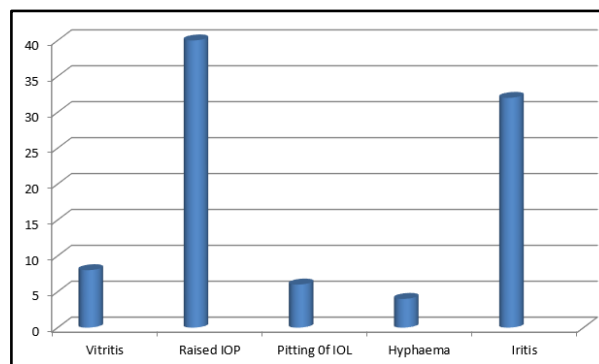


Figure 3. Showing Complications of YAG Capsulotomy

Rise in Intraocular Pressure after Nd:YAG Laser Posterior Capsulotomy- Following the Nd:YAG laser posterior capsulotomy procedure, intraocular pressure was recorded within 4 hours and 1 week and the results are tabulated as follows.

Intraocular Pressure in mm	<4 hours	1 week
No change	49	82
1-2 mmHg	40	14
3-4 mmHg	6	3
>5 mmHg	2	1

Table 5. Rise in Intraocular Pressure after Nd:YAG Laser Posterior Capsulotomy

It was observed that intraocular pressure is raised minimally immediately after YAG capsulotomy in 40 cases. No significant or delayed rise in rest of the cases.

Visual acuity was recorded after YAG capsulotomy and it was observed that 32% of the cases were improved up to 6/9 in 6/60-6/36 category (pre-laser).

In our short study of 100 cases, the main aim was to evaluate the results of Nd:YAG laser capsulotomy in 100 eyes of 100 patients.

All the 100 patients had visual acuity improvement of 1 or more lines after capsulotomy. No one had further decline in visual acuity after capsulotomy.

The average age of presentation of PCO is similar in all the studies. It has been shown that in patients under 40 years of age, the PCO was early, i.e. before 1 year and it is 2 years within the patients of age group 42-60 years.

The average time interval of cataract surgery and Nd:YAG laser capsulotomy was 23 months.

PCO occurred in young patients (under 40) twice as often as in the other groups of age. Technique of cataract extraction had an influence on the incidence of PCO as well.⁷

So, it can be stated that younger the age, earlier will be the PCO.

In the present study, though there is transient rise in IOP at the end of 4 hours, there is no much change in IOP at the end of 1 week.

In our study, we highlighted increase in the IOP was significantly related to the IOP measurement 1 hour after the capsulotomy, whereas difference between baseline and final IOP at 1 week was not significant.

Raised intraocular pressure (IOP > or = 5 mmHg from the baseline) after Nd:YAG laser posterior capsulotomy was noted in both the 'low energy' and the 'high energy' groups, but it was more common in the 'high energy' group ($p < 0.001$, $r = 0.512$).⁸

In the present study, rise in IOP is the most common complication followed by iritis, vitritis, pitting of IOL and lastly hyphema, which was also the same complication seen in other studies.

The rise in IOP is only transient. There is no permanent rise in IOP except in known glaucoma cases. This rise in IOP can be prevented by giving pre-laser antiglaucoma medication and prescribing antiglaucoma medications like 0.5% timolol eye drops and Tab. Diamox 250 mg BD after capsulotomy.

Postoperative visual improvement was 6/24 to 6/6. All patients showed post laser IOP rise that was controlled by topical beta-blockers and steroids effectively.⁹

CONCLUSION

Improvement in visual acuity with Nd:YAG laser capsulotomy is excellent. Complications with Nd:YAG laser capsulotomy are minimal and transient.

Careful follow-up with Nd:YAG laser capsulotomy is important and topical timolol maleate 0.5% drops after capsulotomy prevents spikes of IOP, which may occur in some cases. Oral acetazolamide along with topical timolol can be used in patients who show rise of IOP uncontrollable with topical timolol alone.

Proper selection of case is important. Pitting of IOL may occur in uncooperative patients. Nd:YAG laser capsulotomy should be done with caution in patients with increase in axial length, peripheral degenerations and retinal detachment in other eyes as these patients are at increased risk of retinal detachment.

Nd:YAG laser capsulotomy is a safe method of restoring vision in patients with posterior capsule opacification. The results Nd:YAG laser capsulotomy were comparable to those reported in literature.

Complications like transient rise of intraocular pressure, vitritis, bleeding from iris, pitting of intraocular lens and iritis have been reported in our study. Visual acuity improved to 6/6 in 16 cases, 6/9 in 36 cases, 6/12 in 16 cases, 6/18 in 10 cases, 6/24 in 8 cases, 6/36 in 7 cases, 6/60 in 4 cases and 3 cases were lost for follow-up.

To conclude, Nd:YAG capsulotomy is a safe procedure. Since significant pressure spikes occurs after laser procedure, it is important to put the patients on topical timolol maleate 0.5% drops. Intraocular pressure after 1 hour, 4 hours and 1 week is important. When the patient comes for follow-up after 1 week, 4 weeks and 24 weeks, it is important to look for cystoid macular oedema and retinal detachment and endophthalmitis.

REFERENCES

- [1] Aslam TM, Patton N. Methods of assessment of patients for Nd:YAG laser capsulotomy that correlate with final visual improvement. *BMC Ophthalmol* 2004;4:13.
- [2] Karahan E, Tuncer I, Zengin MO. The effect of ND:YAG laser posterior capsulotomy size on refraction, intraocular pressure, and macular thickness. *J Ophthalmol* 2014;2014:846385.
- [3] Aslam TM, Patton N. Methods of assessment of patients for Nd:YAG laser capsulotomy that correlate with final visual improvement. *BMC Ophthalmology* 2004;4:13.
- [4] Murrill CA, Stanfield DL, Van Brocklin MD. Capsulotomy. *Optom Clin* 1995;4(4):69-83.
- [5] Karahan E, Duygu Er, Kaynak S. An Overview of Nd:YAG laser capsulotomy. *Med Hypothesis Discov Innov Ophthalmol* 2014 Summer;3(2):45-50.
- [6] Bari KN. Nd:YAG laser posterior capsulotomy and visual outcome, *Delta Med Col J* 2013;1(1):16-19.
- [7] Karczewicz D, Pieńkowska-Machoy E, Modrzejewska M, et al. Posterior capsule opacification as a complication of the posterior chamber intraocular lens implantation. *Klin Oczna* 2004;106(1-2):19-22.
- [8] Waseem M, Khan HA. Association of raised intraocular pressure and its correlation to the energy used with raised versus normal intraocular pressure following Nd:YAG laser posterior capsulotomy in pseudophakes. *J Coll Physicians Surg Pak* 2010;20(8):524-527.
- [9] Awan AA, Kazmi SH, Bukhari SA. Intraocular pressure changes after Nd-YAG laser capsulotomy. *J Ayub Med Coll Abbottabad* 2001;13(2):3-4.